



U.S. National Library of Medicine
National Center for Biotechnology Information

NLM Citation: Duis J, van Bon BWM. Schinzel-Giedion Syndrome. 2024 Mar 7. In: Adam MP, Feldman J, Mirzaa GM, et al., editors. GeneReviews® [Internet]. Seattle (WA): University of Washington, Seattle; 1993-2024.
Bookshelf URL: <https://www.ncbi.nlm.nih.gov/books/>



Schinzel-Giedion Syndrome

Jessica Duis, MD, MS¹ and Bregje WM van Bon, MD, PhD²

Created: March 7, 2024.

Summary

Clinical characteristics

Classic Schinzel-Giedion syndrome (SGS), an ultra-rare multisystem disorder caused by gain-of-function pathogenic variants in a *SETBP1* mutational hot spot, is characterized by global neurodevelopmental impairment leading to moderate-to-profound intellectual disability, epilepsy (often refractory to treatment), hypotonia, spasticity, dysautonomia, hearing loss, and cerebral visual impairment. Other findings can include poor weight gain often associated with gastroesophageal reflux disease, chronic vomiting, constipation, gastroparesis, and/or feeding intolerance. Structural malformations can involve the heart, skeleton, kidney and urinary tract, genitalia, and brain. Anomalies of the liver, spleen, and/or pancreas are less common. Other features may include neuroepithelial neoplasia, severely disrupted sleep, choanal stenosis, inguinal hernia, sensitive skin, and increased risk of infection.

To date, more than 50 individuals have been reported with molecularly confirmed classic SGS.

Atypical SGS, reported in five individuals to date, is caused by pathogenic *SETBP1* variants in proximity to – but not within – the mutational hot spot. The broad spectrum of clinical features of variable severity partially overlaps with classic SGS; however, this spectrum does not include risk for neuroepithelial neoplasia to date.

Diagnosis/testing

The diagnosis of classic SGS can be established in a proband based on published clinical diagnostic criteria, or the molecular diagnosis can be established in a proband with suggestive findings and a heterozygous *SETBP1* pathogenic gain-of-function variant within the mutational hot spot (i.e., a 12-base-pair region in exon 4 encoding a canonical degron). The diagnosis of atypical SGS syndrome is established in a proband with suggestive findings and a heterozygous *SETBP1* pathogenic variant adjacent to – but not within – the mutational hot spot.

Author Affiliations: 1 Children's Hospital Colorado; University of Colorado Anschutz Medical Campus, Aurora, Colorado; Email: jduis@sequencemd.com. 2 Department of Human Genetics, Radboud University Medical Center, Nijmegen, the Netherlands; Email: bregje.vanbon@radboudumc.nl.

Copyright © 1993-2024, University of Washington, Seattle. GeneReviews is a registered trademark of the University of Washington, Seattle. All rights reserved.

Management

Treatment of manifestations: There is no cure for classic or atypical SGS. Supportive treatment to improve quality of life, maximize function, and reduce complications can include multidisciplinary care by specialists in pediatrics, neurology, physiatry, occupational and physical therapy, speech-language pathology, psychiatry, ophthalmology, ENT, surgery, pulmonology, oncology, urology, nephrology, audiology, gastroenterology, orthopedics, cardiology, and medical genetics.

Surveillance: At each visit, evaluate for feeding issues (including nutritional status and safety of oral intake), gastrointestinal issues, respiratory issues, neurologic manifestations (including seizures, changes in tone, movement disorders, mood, irritability, and alertness), kidney and urinary tract manifestations, and musculoskeletal manifestations. In individuals with classic SGS, age-related surveillance for occurrence of neoplasia includes liver ultrasound and serum alpha-fetoprotein levels, renal ultrasound examination, pelvic MRI for sacrococcygeal teratoma, and monitoring for clinical signs of leukemia.

Agents/circumstances to avoid: Nephrotoxic drugs such as nonsteroidal anti-inflammatory drugs and vancomycin should be used with caution due to high frequency of chronic renal impairment from recurrent pyelonephritis and structural renal anomalies.

Genetic counseling

Classic and atypical SGS are autosomal dominant disorders typically caused by a *de novo* *SETBP1* pathogenic variant. Rarely, individuals diagnosed with SGS have the disorder as the result of a pathogenic variant inherited from a parent. Sib recurrence of clinically defined classic SGS, presumed to be due to parental germline mosaicism, has been reported in two families. Transmission of a *SETBP1* pathogenic missense variant from an unaffected parent to a child with atypical SGS has been reported in one family (of note, the possibility of mosaicism in the unaffected parent was not excluded). Once the *SETBP1* pathogenic variant has been identified in an affected family member, prenatal and preimplantation genetic testing are possible.

GeneReview Scope

Pathogenic variants in *SETBP1* are known to be associated with a spectrum of phenotypes ranging from classic Schinzel-Giedion syndrome and atypical Schinzel-Giedion syndrome on the most severe end to *SETBP1* haploinsufficiency and other phenotypes on the milder end. This chapter specifically focuses on classic and atypical Schinzel-Giedion syndrome.

Spectrum of Phenotypes Associated with *SETBP1* Pathogenic Variants

Designation		Associated Pathogenic Variants	Comment
Schinzel-Giedion syndrome (SGS) phenotypic continuum (topic of this GeneReview)	Classic SGS	Gain-of-function pathogenic variants in mutational hot spot (i.e., a 12-base-pair region in exon 4 encoding a canonical degron)	Severe phenotype consistent w/original SGS clinical diagnostic criteria ¹
	Atypical SGS	Gain-of-function pathogenic variants adjacent to – but not within – mutational hot spot	<ul style="list-style-type: none"> Broad spectrum of clinical features of variable severity that partially overlap w/classic SGS Atypical SGS is milder than classic SGS.

Spectrum of Phenotypes continued from previous page.

Designation	Associated Pathogenic Variants	Comment
SETBP1-related disorders (not SGS or SETBP1-HD)	Missense pathogenic variants w/ unknown functional effects that are not adjacent to mutational hot spot	<ul style="list-style-type: none"> "SETBP1-related disorders" may be used to refer to phenotypes that are not consistent w/SGS or SETBP1-HD caused by SETBP1 pathogenic variants that do not result in loss of function and are not within or near the SGS mutational hot spot. Note: "SETBP1-related disorders" has also been used to refer to all phenotypes associated w/SETBP1 pathogenic variants. See Genetically Related Disorders.
SETBP1 Haploinsufficiency Disorder (SETBP1-HD)	Loss-of-function pathogenic variants (truncating variants / SETBP1-specific deletions)	See Genetically Related Disorders.

1. Lehman et al [2008]

Diagnosis

This chapter focuses on classic and atypical Schinzel-Giedion syndrome (SGS). Before pathogenic variants within *SETBP1* were identified to cause classic Schinzel-Giedion syndrome (SGS), clinical diagnostic criteria for classic SGS were proposed [Lehman et al 2008] (see Establishing the Diagnosis).

Suggestive Findings

Schinzel-Giedion syndrome (SGS) **should be considered** in a proband with the following clinical findings and family history.

Clinical findings

- Moderate-to-profound developmental delay (DD) or intellectual disability (ID)
- Facial features include a prominent forehead, midface retrusion, and bitemporal narrowing with or without other characteristic features (see Figure 2). **Although** facial features are typical in both classic and atypical SGS, the facial features in individuals with atypical SGS are not as coarse.

AND any of the following features presenting in infancy or childhood:

- Tone abnormalities (including hypotonia or spasticity)
- Feeding difficulties
- Swallowing difficulties (laryngomalacia, choanal stenosis)
- Epilepsy (multiple types of seizures)
- Microcephaly
- Cerebral vision impairment (CVI), broadly defined here as bilateral visual impairment due to non-ocular causes (i.e., based in the brain) in the presence of normal pupil reactivity
- Hearing impairment, mainly sensorineural hearing loss and less commonly conductive hearing loss
- Congenital anomalies of the kidney and urinary tract, such as hydronephrosis, ureteral anomalies, and renal cysts
- Genital anomalies (in males: hypospadias and hypoplastic scrotum; in females: hypoplastic labia)
- Cardiac anomalies, the majority of which are atrial septal defects, patent ductus arteriosus, and patent foramen ovale
- Skeletal features, including sclerotic base of the skull, wide supraoccipital-exoccipital synchondroses, broad ribs, increased cortical density or thickness, hypoplastic distal phalanges, and talipes equinovarus

- Neoplasia (reported in classic SGS only to date) that may be benign or malignant. The majority of neoplasias are of neuroepithelial origin (mainly sacrococcygeal teratomas). Depending on their location, tumors may also cause obstructive problems.

Family history. Because SGS is typically caused by a *de novo* pathogenic variant, most probands represent a simplex case (i.e., a single occurrence in a family).

Establishing the Diagnosis

Classic SGS

The **clinical diagnosis** of classic Schinzel-Giedion syndrome (SGS) can be **established** in a proband based on clinical diagnostic criteria [Lehman et al 2008] (see Table 1), or the **molecular diagnosis** can be **established** in a proband with suggestive findings and a heterozygous *SETBP1* pathogenic (or likely pathogenic) gain-of-function variant within the mutational hot spot (i.e., a 12-base-pair region in exon 4 encoding a canonical degron) (see Table 2 and Molecular Genetics).

Clinical diagnostic criteria. See Table 1.

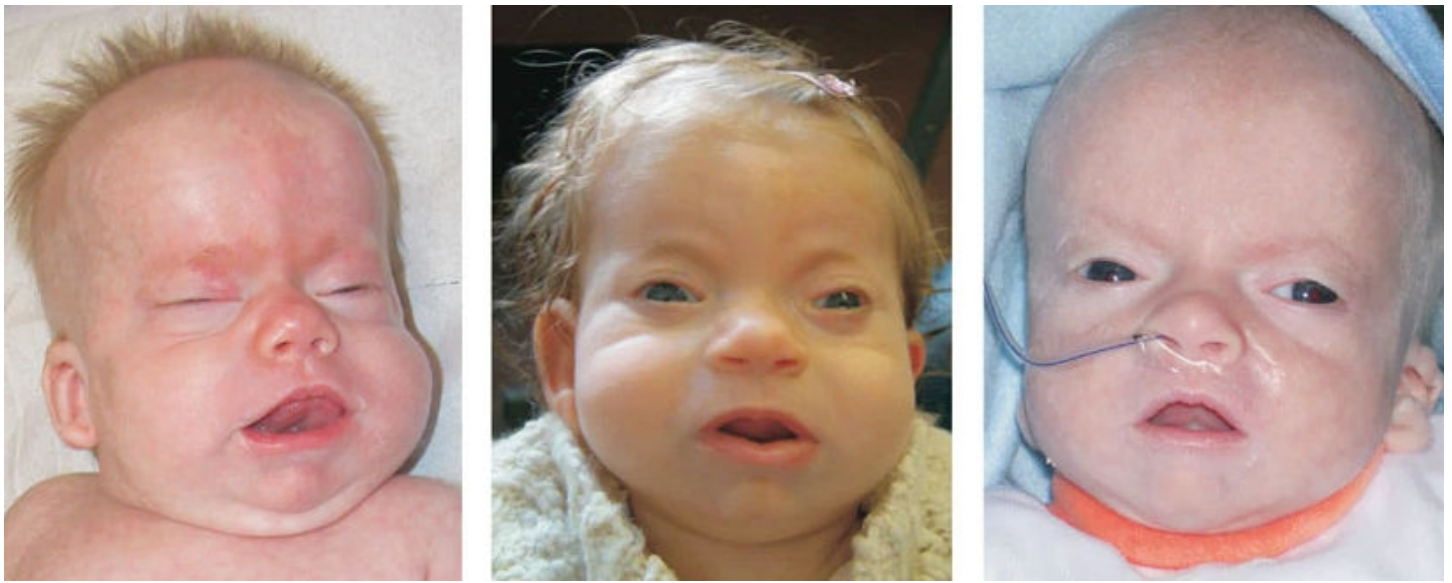

Figure 2. Characteristic facial features in individuals with Schinzel-Giedion syndrome (SGS), including prominent forehead, bitemporal narrowing, midface retrusion, hypertelorism, infraorbital crease, short nose with upturned nasal tip, and low-set, abnormally formed ears

Most individuals with SGS have a characteristic facial gestalt that is easily recognizable. There are large fontanelles, a prominent forehead, bitemporal narrowing, shallow orbits or prominent eyes, hypertelorism, midface retrusion, shortened midface, and full cheeks, leading to a facial frontal silhouette in the shape of the number eight. Additionally, most individuals have an infraorbital crease, upslanted palpebral fissures, and short nose with a bulbous nasal tip. During the first weeks of life some infants may have less recognizable facial features.

Additional diagnostic clues include abnormal ear shape, which are low-set and posteriorly rotated with anteriorly angulated lobules leading to a question mark shape. Often, individuals have a large mouth with an everted vermilion of the lower lip, protruding tongue, and macroglossia. Some may also have micrognathia, a short neck, and/or facial hemangioma.

Reprinted with permission from Hoischen et al [2010]

Table 1. Classic Schinzel-Giedion Syndrome: Clinical Diagnostic Criteria

Presence of Both Mandatory Features	AND Presence of ≥ 1 Typical Feature
Developmental delay (or hypotonia in neonates) AND Facial features (prominent forehead, midface retrusion, & short nose w/ upturned nasal tip; see Figure 2)	Hydronephrosis OR ≥ 2 of the following skeletal malformations: <ul style="list-style-type: none"> • Sclerotic skull base • Wide supraoccipital-exoccipital synchondroses • \uparrow cortical density or thickness • Broad ribs

Adapted from Lehman et al [2008]

Atypical SGS

The **diagnosis** can be established in a proband with suggestive findings and a heterozygous *SETBP1* pathogenic (or likely pathogenic) variant adjacent to – but not within – the mutational hot spot.

Molecular Genetic Testing

Molecular genetic testing approaches can include a combination of **gene-targeted testing** (single gene testing, multigene panel) and **comprehensive genomic testing** (exome sequencing, genome sequencing). Gene-targeted

testing requires that the clinician determine which gene(s) are likely involved (see Option 1), whereas comprehensive genomic testing does not (see Option 2).

Note: (1) Per ACMG/AMP variant interpretation guidelines, the terms "pathogenic variant" and "likely pathogenic variant" are synonymous in a clinical setting, meaning that both are considered diagnostic and can be used for clinical decision making [Richards et al 2015]. Reference to "pathogenic variant" in this *GeneReview* is understood to include likely pathogenic variants. (2) Identification of a heterozygous *SETBP1* variant of uncertain significance does not establish or rule out the diagnosis.

Option 1

A multigene panel that includes *SETBP1* and other genes of interest (see Differential Diagnosis) is most likely to identify the genetic cause of the condition while limiting identification of variants of uncertain significance and pathogenic variants in genes that do not explain the underlying phenotype. Note: (1) The genes included in the panel and the diagnostic sensitivity of the testing used for each gene vary by laboratory and are likely to change over time. (2) Some multigene panels may include genes not associated with the phenotypes discussed in this *GeneReview*. (3) In some laboratories, panel options may include a custom laboratory-designed panel and/or custom phenotype-focused exome analysis that includes genes specified by the clinician. (4) Methods used in a panel may include sequence analysis, deletion/duplication analysis, and/or other non-sequencing-based tests.

For an introduction to multigene panels click [here](#). More detailed information for clinicians ordering genetic tests can be found [here](#).

Note: Single-gene testing is typically NOT recommended as multi-gene panel testing offers significant advantages including more efficient (and often more affordable) testing, especially when the clinician has not suspected the diagnosis of SGS. However, when resources are limited or when a clinical diagnosis of SGS (that fulfils the original criteria proposed by Lehman et al [2008]) is highly suspected, single gene testing may be considered.

Option 2

Comprehensive genomic testing does not require the clinician to determine which gene is likely involved. **Exome sequencing** is most commonly used; **genome sequencing** is also possible. The majority of *SETBP1* pathogenic variants reported to date (e.g., missense, nonsense) are within the coding region and are likely to be identified on exome sequencing.

For an introduction to comprehensive genomic testing click [here](#). More detailed information for clinicians ordering genomic testing can be found [here](#).

Table 2. Molecular Genetic Testing Used in Schinzel-Giedion Syndrome

Gene ¹	Method	Proportion of Pathogenic Variants ² Detectable by Method
<i>SETBP1</i>	Sequence analysis ³	100% ⁴
	Gene-targeted deletion/duplication analysis ⁵	None reported to date ^{4, 6}

1. See Table A. Genes and Databases for chromosome locus and protein.

2. See Molecular Genetics for information on variants detected in this gene.

3. Sequence analysis detects variants that are benign, likely benign, of uncertain significance, likely pathogenic, or pathogenic. Variants may include missense, nonsense, and splice site variants and small intragenic deletions/insertions; typically, exon or whole-gene deletions/duplications are not detected. For issues to consider in interpretation of sequence analysis results, click [here](#).

4. Data derived from the subscription-based professional view of Human Gene Mutation Database [Stenson et al 2020]

5. Gene-targeted deletion/duplication analysis detects intragenic deletions or duplications. Methods used may include a range of techniques such as quantitative PCR, long-range PCR, multiplex ligation-dependent probe amplification (MLPA), and a gene-targeted microarray designed to detect single-exon deletions or duplications. Exome and genome sequencing may be able to detect deletions/duplications using breakpoint detection or read depth; however, sensitivity can be lower than gene-targeted deletion/duplication analysis.

6. To date, large intragenic deletions/duplications have not been reported and are not expected in individuals with classic or atypical SGS.

Clinical Characteristics

Clinical Description

Classic Schinzel-Giedion syndrome (SGS), an ultra-rare multisystem disorder, is characterized by a range of physical and developmental abnormalities. The main features include global neurodevelopmental impairment leading to moderate-to-profound intellectual disability, epilepsy (often refractory to treatment), tone abnormalities, dysautonomia, and cerebral visual and hearing impairment. Poor weight gain is common and often associated with gastroesophageal reflux disease, chronic vomiting, constipation, gastroparesis, and/or feeding intolerance. Structural malformations can involve the heart, skeleton, kidney and urinary tract, genitalia, and brain. Rarely there may be anomalies of the liver, spleen, and/or pancreas. Other features may include neuroepithelial neoplasia, severely disrupted sleep, choanal stenosis, inguinal hernia, sensitive skin, and increased risk of infection.

To date, more than 50 individuals have been reported with molecularly confirmed classic SGS [Hoischen et al 2010, Suphapeetiporn et al 2011, Lestner et al 2012, Ko et al 2013, Carvalho et al 2015, Herenger et al 2015, López-González et al 2015, Miyake et al 2015, Takeuchi et al 2015, Volk et al 2015, Hishimura et al 2016, Acuna-Hidalgo et al 2017, Bulut et al 2017, Leonardi et al 2020, Leone et al 2020, Sullivan et al 2020, Yang et al 2022].

In addition, more than 40 individuals with the clinical diagnosis of SGS were reported in the medical literature before pathogenic variants in *SETBP1* were identified to cause SGS [Lehman et al 2008].

Atypical SGS, caused by *SETBP1* pathogenic variants in proximity to – but not within – the mutational hot spot, has a broad spectrum of clinical features of variable severity that partially overlap with classic SGS, but do not include risk for neuroepithelial neoplasia to date. Five individuals with atypical SGS have been reported to date.

The following clinical description is mainly based on reports of individuals with molecularly confirmed classic SGS (see Table 3).

Table 3. Classic Schinzel-Giedion Syndrome: Frequency of Select Features

Feature	% of Persons w/Feature	
Development delay / intellectual disability	100%	
Neurologic	Epilepsy	75%-100%
	Hypotonia	75%-100%
	Cerebral visual impairment	70%-80%
	Spasticity/hypertonia	50%-75%
Feeding difficulties & poor weight gain	75%-100%	
Hearing impairment	75%-100%	
Ophthalmologic involvement	75%-100%	
Skeletal findings	75%-100%	
CAKUT	75%-100%	
Genital anomalies	75%-100%	
Hypertrichosis	50%-75%	
Cardiac defects	20%-50%	
Neoplasia	20%-50%	
Tracheo- & laryngomalacia	20%-50%	
Choanal stenosis	20%-50%	
Inguinal hernia	20%-50%	
Frequent infections	20%-50%	

Based on Hoischen et al [2010], Acuna-Hidalgo et al [2017]

CAKUT = congenital anomalies of the kidney and urinary tract

Developmental delay (DD) and intellectual disability (ID). Moderate-to-severe (in classic SGS) or mild-to-severe (in atypical SGS) developmental delay and intellectual disability are present in all individuals reported to date. The majority of individuals with classic SGS have no speech and never develop the ability to walk independently.

Epilepsy may start in the neonatal period or later. The heterogeneous seizure types include tonic, tonic-clonic, myoclonic, or partial motor seizures and infantile epileptic spasms syndrome (IESS) (seen in about 25% of individuals). EEG findings often show multifocal spikes or hypsarrhythmia. Epilepsy is reported less frequently in individuals with atypical SGS than in individuals with classic SGS.

Most seizures are refractory to treatment with anti-seizure medications (ASMs), adrenocorticotrophic hormone, steroids, and the ketogenic diet.

Hypotonia and spasticity are common and may occur at different times in the same individual. While hypotonia is common at birth, spasticity may develop at a later age and progress. Differences in muscular tone may also lead to spinal deformities such as scoliosis.

Cerebral vision impairment has been reported in 70%-80% of individuals with classic SGS and may also occur in atypical SGS.

Feeding difficulties may be due to underlying factors including hypotonia, sucking problems due to micrognathia, swallowing problems, trachea- and/or laryngomalacia, gastroesophageal reflux disease, and/or vomiting.

Hearing impairment occurs in nearly 90% of individuals with classic SGS and may also occur in atypical SGS. While the type of hearing loss can vary among affected individuals, bilateral sensorineural hearing loss is most common, ranges from mild to profound, and can differ in each ear.

Other reported types of hearing loss include mixed or conductive hearing loss. For example, mixed moderate hearing loss was reported in two individuals due to bilateral deformations of the stapes (that had a tuning fork shape) and in one individual with a flattened last cochlear spire (identified by temporal bone CT scan) [Minn et al 2002, Herenger et al 2015].

Ophthalmologic involvement. Abnormalities of the optic nerve (small optic discs, optic disc pit), strabismus, and alacrima with corneal hypoesthesia have been reported.

Skeletal findings. Anomalies identified on skeletal radiographs can include sclerotic base of the skull with a wide occipital synchondrosis, a poorly mineralized rest of the cranium, a wide anterior fontanelle, and wormian bones. Additional findings can include broad ribs, scoliosis, bowed long bones, short pubic rami, wide pubic symphysis, and hypoplastic distal phalanges in the hands and feet. Individuals often show a typical posture with clenched hand (see Figure 1). Talipes equinovarus is common.

Postaxial polydactyly (predominantly of the hands) was noted in about 5%-10% of individuals with classic SGS.

Congenital anomalies of the kidney and urinary tract. Bilateral or unilateral hydronephrosis, ranging from mild pyelectasis to severe hydronephrosis, is common in individuals with classic SGS. Hydronephrosis may be present on prenatal ultrasound examination; however, it may not be present at birth but rather develop during infancy. Two individuals with atypical SGS have had medullary cystic kidneys, mild pyelectasis, and chronic urinary infections.

Stenosis of the ureteropelvic junction or vesicoureteral reflux are common. Bladder atony may be the cause of frequent and persistent urinary tract infections.

Other anomalies can include abnormal ureters and renal cysts.

One individual had bilateral large coralliform (i.e., resembling the calyx cavities) renal stones that were predominantly calcium oxalate and calcium phosphate without pyelic dilatation [Herenger et al 2015].

Genital anomalies. The majority of individuals with classic SGS have genital anomalies. In males, these include micropenis (which may appear as ambiguous genitalia on antenatal ultrasound examination), hypospadias, hypoplastic scrotum, and cryptorchidism. In females, these include bifid uterus, hypoplastic uterus, hypoplastic labia majora or minora, and deep labial sulcus. The perineum is often short with an anteriorly displaced anus [Lehman et al 2008].

Cardiac defects. The majority of cardiac defects are atrial septal defects, persistent foramen ovale, and patent ductus arteriosus. Other cardiac findings that occur occasionally include hypoplasia of ventricles and cardiac hypertrophy.

Neoplasia. About 25% of individuals with classic SGS develop a neoplasia, often of neuroepithelial origin. To date, SGS-related neoplasia has not been reported in individuals with atypical SGS caused by *SETBP1* pathogenic variants outside of the mutational hot spot. Neoplasias may be detected at birth, during the first year of life, or later in life (e.g., malignant degeneration of a multicystic dysplastic kidney) [Matsumoto et al 2005].

Sacroccygeal teratoma is the most common tumor. Other reported tumors include hepatoblastoma, lumbosacral teratoma, lumbosacral primitive neuroectodermal tumor, Wilms tumor, and extradural ependymomas. To date, juvenile myelomonocytic leukemia has been reported in one individual [Acuna-Hidalgo et al 2017].

Although most children with SGS die from other causes, a 24-month-old child died of organ failure due to a sacroccygeal teratoma and a five-year-old child died due to relapse of an extradural ependymal tumor [Acuna-Hidalgo et al 2017].

Other findings

- **Microcephaly** has been observed in approximately 80% of individuals with classic SGS. In most reported individuals, microcephaly is postnatal – although the occipital-frontal circumference may be within normal limits at birth (almost always below the 50th and often near the 10th centile), head growth decelerates and microcephaly develops during infancy.
- **Structural brain abnormalities** vary. Most common are partial or complete agenesis of the corpus callosum. Other findings can include progressive cortical atrophy, ventricular anomalies, hydrocephalus, cortical abnormalities, delayed myelination, and choroid plexus cysts.

In one individual, an abnormal posterior fossa with stretching of the pituitary stalk resulted in central diabetes insipidus and central hypothyroidism [Santos et al 1994].

- **Respiratory abnormalities.** Structural abnormalities that may lead to breathing and swallowing difficulties include choanal stenosis, micrognathia, tracheobronchomalacia, and lung hypoplasia. Difficulty managing oral and respiratory secretions resulting from progressive gingival hypertrophy and/or excessive mucus production may be additional factors that increase the risk of aspiration and respiratory infections including pneumonia.
- **Gastrointestinal problems.** Constipation, gastroesophageal reflux disease, and aspiration are common. Chronic vomiting and gastroparesis may also occur. Anteriorly placed anus is often associated with genital anomalies in males and females.
- **Structural anomalies of internal organs**, such as hypoplasia of the pancreatic tail, annular pancreas, splenopancreatic fusion, and hepatosplenomegaly have been reported.

Postmortem microscopic evaluation of the pancreas in a four-day-old infant showed dilated interlobular ducts, filled with eosinic mucus and surrounded by abundant connective tissue. Additionally, dilated glands and mucus depositions were found in larynx and bronchial glands; although these findings were like those observed in cystic fibrosis, *CFTR* testing was normal [Acuna Hidalgo et al 2017].

- **Skin.** Generalized hypertrichosis that is common at birth may recede during infancy. Facial hemangiomas are present in 25% of individuals with classic SGS. Other features may include dry erythematous skin, redundant nuchal skin, cutis marmorata, hypoplastic nipples, hyperconvex nails, and hypoplastic dermal ridges.
- **Dental findings** include hypodontia, delayed teeth eruption, and congenital thickened gingiva (unrelated to use of ASMs).

One infant developed gingival hyperplasia at age seven months (two weeks prior to the initiation of ASMs) that became severe after age two years. His gingivae were so large that they protruded from his mouth, pressed his tongue to the pharynx, and covered his teeth. Because of difficulty with eating and breathing, he underwent full mouth gingivectomy twice, once at age four years and again at age six years. Histologic findings were gingival fibrous hyperplasia with mucoid depositions [Kondoh et al 2001].

Similar microscopic histologic findings were noted on postmortem examination in a four-day-old infant [Acuna-Hidalgo et al 2017].

- **Neurobehavioral manifestations.** To date, extensive information on behavior is not available. Although sleep disturbances and extensive periods of crying and irritability have been reported, additional evaluation is warranted for an underlying cause such as urinary tract infection and development of hydrocephalus or sacrococcygeal tumor.
- **Growth.** Birth length and weight are often within normal limits.
- **Prenatal findings.** Pregnancy may be complicated by polyhydramnios. Fetal ultrasound examination may reveal other findings such as hydronephrosis, ambiguous genitalia, cardiac defects, overlapping fingers, and/or a typical facial appearance.

Prognosis. The shortened life span of children with SGS may be correlated with the number and severity of the features present. While death mainly results from pneumonia (also after aspiration), other reported causes of death in early infancy include sepsis, lung hypoplasia, intractable epilepsy, and sudden cardiac arrest.

Genotype-Phenotype Correlations

Pathogenic variants in *SETBP1* are now known to be associated with several phenotypes depending on their location and functional effects.

- Classic SGS is associated with pathogenic gain-of-function *SETBP1* variants within the mutational hot spot (i.e., a 12-base-pair region in exon 4 encoding a canonical degron). These pathogenic variants are within amino acid residues 868-871 (p.Asp868Ala/Asn/Tyr, p.Ser869Gly/Asn/Arg, p.Gly870Cys/Asp/Ser, p.Ile871Ser/Thr). See Table 8.
- Atypical SGS is associated with pathogenic missense *SETBP1* variants near – but not within – the mutational hot spot. The specific amino acid change is also thought to influence the resulting clinical phenotype. However, clear genotype-phenotype relationships have not been established at this time, and further research is needed to understand the molecular pathogenesis and clinical consequences of these pathogenic missense variants. For a summary of case reports and pathogenic reported missense variants, click [here](#) (xls).

Prevalence

To date, more than 50 individuals have been reported in the medical literature with molecularly confirmed classic SGS; more than 40 additional individuals were reported with the clinical diagnosis of classic SGS before *SETBP1* pathogenic variants were known to be causative (see Clinical Description).

To date, five individuals with atypical SGS have been reported. For a summary of case reports and reported pathogenic missense variants in *SETBP1*, click [here](#) (xls).

Genetically Related (Allelic) Disorders

***SETBP1* haploinsufficiency disorder.** Germline pathogenic loss-of-function *SETBP1* variants and deletions (causing haploinsufficiency) are associated with *SETBP1* haploinsufficiency disorder (*SETBP1*-HD). *SETBP1*-HD is characterized by hypotonia and mild motor developmental delay; intellectual abilities ranging from normal to severe disability; speech-language disorder; behavioral problems (most commonly attention/concentration deficits and hyperactivity/impulsivity), and refractive errors and strabismus. Children with *SETBP1*-HD whose intellect is in the normal or borderline range (IQ: 80-90) were diagnosed following genetic testing for behavioral problems and/or severe speech-language disorders (the inability to produce sounds in words correctly and/or deficits in the understanding and/or expression of words and sentences).

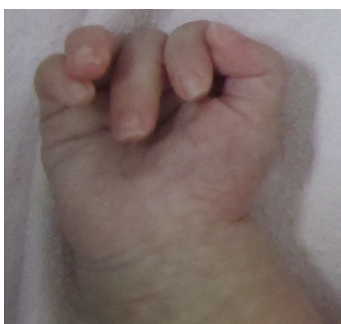


Figure 1. Characteristic hand posture with clenched hand in an individual with Schinzel-Giedion syndrome

Adapted with permission from Acuna-Hidalgo et al [2017]

SETBP1-related disorders. The term "SETBP1-related disorders" may be used to refer to variable neurodevelopmental phenotypes (i.e., phenotypes that are not consistent with classic Schinzel-Giedion syndrome [SGS], atypical SGS, or SETBP1-HD) associated with pathogenic missense SETBP1 variants of unknown functional effect that are not within or adjacent to the mutational hot spot (see [medRxiv](#)).

Sporadic cancers (including myelodysplastic/myeloproliferative neoplasms, atypical chronic myeloid leukemia, chronic myelomonocytic leukemia, juvenile myelomonocytic leukemia, and secondary acute myeloid leukemia) occurring in the absence of other findings of classic or atypical SGS frequently contain a somatic pathogenic variant in SETBP1 that is **not** present in the germline [Makishima et al 2013, Acuna-Hidalgo et al 2017]. Of note, even though recurrent somatic pathogenic gain-of-function SETBP1 variants are located at the identical positions of germline variants reported in classic and atypical SGS, predisposition to these tumors is not heritable.

Differential Diagnosis

The phenotypic features associated with classic Schinzel-Giedion syndrome (SGS) are often sufficient to diagnose this condition clinically. However, in individuals with findings in the moderate end of the spectrum of classic SGS (e.g., less apparent dysmorphisms, no hydronephrosis or other congenital anomalies and/or epilepsy) or atypical SGS, the following monogenic disorders (see Table 4), chromosomal anomalies, and teratogenic conditions may be considered in the differential diagnosis.

Table 4. Selected Monogenic Disorders in the Differential Diagnosis of Classic and Atypical Schinzel-Giedion Syndrome

Gene	Disorder	MOI	Features of Disorder	
			Overlapping w/SGS	Distinguishing from SGS
ARSB ARSK GALNS GLB1 GNS GUSB HGSNAT HYAL1 IDS IDUA NAGLU SGSH	Mucopolysaccharidosis (OMIM PS607014)	AR (XL 1)	Midface retrusion, coarse facial features, hypertrichosis, poor growth	Metabolic anomalies characteristic of MPS

Table 4. continued from previous page.

Gene	Disorder	MOI	Features of Disorder	
			Overlapping w/SGS	Distinguishing from SGS
<i>FLNA</i>	Melnick-Needles syndrome (See X-Linked Otopalatodigital Spectrum Disorders .)	XL	Skull base sclerosis, full cheeks, hydronephrosis	Luxation of digits, prominent eyes, normal intellectual development
<i>PEX1</i> <i>PEX2</i> <i>PEX3</i> <i>PEX5</i> <i>PEX6</i> <i>PEX10</i> <i>PEX11B</i> <i>PEX12</i> <i>PEX13</i> <i>PEX14</i> <i>PEX16</i> <i>PEX19</i> <i>PEX26</i>	Zellweger spectrum disorder	AR ²	Midface retrusion, hypertrichosis, large anterior fontanel, seizures	Chondrodysplasia punctata, peroxisomal abnormalities

AR = autosomal recessive; MOI = mode of inheritance; MPS = mucopolysaccharidosis; XL = X-linked

1. Mucopolysaccharidosis is inherited in an autosomal recessive manner except for MPS II; MPS II is caused by pathogenic variants in *IDS* and inherited in an X-linked manner.

2. Zellweger spectrum disorder (ZSD) is typically inherited in an autosomal recessive manner. One *PEX6* pathogenic variant has been associated with ZSD in the heterozygous state due to allelic expression imbalance dependent on allelic background.

Chromosomal abnormalities. Similar to SGS, 20p deletion, tetrasomy 12p mosaicism, 9p deletion, and trisomy 9 mosaicism can be associated with multiple congenital anomalies and coarse facial features. These chromosomal disorders can be distinguished from SGS by various characteristic features (e.g., microphthalmia in trisomy 9 mosaicism and normal head circumference in tetrasomy 12p).

Antenatal phenytoin or warfarin exposure. Prenatal exposure to phenytoin/warfarin can result in midface retrusion and hypertrichosis.

Management

No clinical practice guidelines for classic or atypical Schinzel-Giedion syndrome (SGS) have been published. The recommendations in this section reflect the authors' experience in the management of individuals with SGS.

Evaluations Following Initial Diagnosis

To establish the extent of disease and needs in an individual diagnosed with classic or atypical SGS, the evaluations summarized in Table 5 (if not performed as part of the evaluation that led to diagnosis) are recommended.

Table 5. Schinzel-Giedion Syndrome: Recommended Evaluations Following Initial Diagnosis

System/Concern	Evaluation	Comment
Constitutional	Physical exam	Measure head circumference, weight, & length.
Neurologic	Neurologic eval	<ul style="list-style-type: none"> To incl brain MRI Consider EEG if seizures are a concern.
Development	Developmental assessment	<ul style="list-style-type: none"> To incl motor, adaptive, cognitive, & speech-language eval Evaluate for early intervention / special education

Table 5. continued from previous page.

System/Concern	Evaluation	Comment
Neurobehavioral	Eval by developmental pediatrician	For persons age >12 mos: screening for behavior concerns
		In case of severe sleep disturbances, consider polysomnography/ EEG.
Musculoskeletal	Orthopedics / physical medicine & rehab / PT & OT eval	To incl assessment of: <ul style="list-style-type: none"> Gross motor & fine motor skills Contractures, clubfoot, & (kypho)scoliosis Mobility, ADL, & need for adaptive devices Need for PT (to improve gross motor skills) &/or OT (to improve fine motor skills)
Gastrointestinal/ Feeding	Gastroenterology / nutrition / feeding team eval	<ul style="list-style-type: none"> To incl eval of swallowing, aspiration risk, & nutritional status Consider eval for gastrostomy tube or gastrostomy-jejunosomy tube placement in persons w/dysphagia &/or aspiration risk.
	Assess for constipation.	
Eyes/vision	Ophthalmologic eval	To assess for reduced vision, abnormal ocular movement, strabismus, & more complex findings (e.g., cataract, retinal dystrophy) that may require referral for subspecialty care &/or low vision services
	Specialist assessment for cerebral visual impairment	Educational assessment for visual services
Hearing	Audiologic eval	Assess for sensorineural &/or conductive hearing loss.
Associated cancer ¹	Sacroccocygeal teratoma	<ul style="list-style-type: none"> Perform pelvic ultrasound in children age ≤6 mos Perform pelvic MRI in children age >6 mos
	Hepatoblastoma	Liver ultrasound & serum AFP
	Wilms tumor	Renal ultrasound
	Ependymoma	MRI of brain & spinal cord
ENT	ENT eval	<ul style="list-style-type: none"> Attempt to insert flexible nasal endoscope to detect choanal stenosis/atresia. Assess for tracheo- & laryngomalacia; additional imaging may be needed. Mgmt of drooling due to risk of aspiration
Cardiovascular	Cardiology eval	<ul style="list-style-type: none"> Assess for congenital cardiac defects (mainly atrial septal defects). Other defects incl patent foramen ovale, patent ductus arteriosus, & cardiac hypertrophy.
Respiratory	Pulmonary eval	<ul style="list-style-type: none"> Note that excessive mucus production may lead to breathing problems. Assess for tracheo- & laryngomalacia; additional imaging may be needed. Lung ultrasound or MRI¹ to exclude lung hypoplasia
CAKUT	Urologic eval	<ul style="list-style-type: none"> Assess for UPJ obstruction or VUR & hydronephrosis. Exclude other renal/bladder anomalies such as abnormal ureters, cysts & stones, & bladder atony.

Table 5. continued from previous page.

System/Concern	Evaluation	Comment
Genital anomalies	Eval for genital anomalies	<ul style="list-style-type: none"> • Males: assess for hypospadias, cryptorchidism, micropenis, hypoplastic scrotum. • Females: assess for abnormal labia, hypoplastic uterus. • Assess for an anteriorly displaced anus.
Genetic counseling	By genetics professionals ²	To inform affected persons & their families re nature, MOI, & implications of SGS to facilitate medical & personal decision making
Family support & resources	<ul style="list-style-type: none"> • Ensure appropriate social work involvement to connect families w/local resources, respite, & support. • Coordinate care to manage multiple subspecialty appointments, equipment, medications, & supplies. 	<p>Assess need for:</p> <ul style="list-style-type: none"> • Community or online resources such as Parent to Parent; • Social work involvement for parental support; • Palliative care involvement &/or home nursing referral.

ADL = activities of daily living; AFP = alpha-fetoprotein; CAKUT = congenital anomalies of the kidney and urinary tract; MOI = mode of inheritance; OT = occupational therapy; PT = physical therapy; UPJ = ureteropelvic junction; VUR = vesicoureteral reflux

1. For children with atypical SGS, the treating physician may weigh the disadvantages of anesthesia to perform an MRI against the possible advantages of a low-risk screen; however, more data are needed to inform these recommendations.

2. An option is to consider a full-body MRI at the time of diagnosis to evaluate for anomalies of the brain, lung, spinal cord, pancreas (e.g., splenopancreatic fusion / pancreatic hypoplasia), liver and spleen (hepatosplenomegaly), kidney, and urinary tract. Abnormal findings can then be evaluated in more detail.

3. Medical geneticist, certified genetic counselor, certified advanced genetic nurse

Treatment of Manifestations

There is no cure for classic or atypical Schinzel-Giedion syndrome. Supportive treatment to improve quality of life, maximize function, and reduce complications is recommended. This can include multidisciplinary care by specialists in pediatrics, neurology, psychiatry, occupational and physical therapy, speech-language pathology, gastroenterology, orthopedics, cardiology, and medical genetics (see Table 6).

Table 6. Schinzel-Giedion Syndrome: Treatment of Manifestations

Manifestation/Concern	Treatment	Considerations/Other
Developmental delay / Intellectual disability	See Developmental Delay / Intellectual Disability Management Issues.	
Epilepsy	Standardized treatment w/ASMs, ACTH, &/or steroids by experienced neurologist	<ul style="list-style-type: none"> • Seizures may be extremely refractory to ASMs, ACTH, steroids, & ketogenic diet. • Different (combined) ASMs may be effective but none has been demonstrated effective specifically for this disorder. • Education of parents/caregivers ¹
Poor weight gain / Failure to thrive	<ul style="list-style-type: none"> • Gastrostomy tube placement may be required for persistent feeding issues. • Standard mgmt for gastroparesis 	Low threshold for clinical feeding eval &/or radiographic swallowing study when showing clinical signs or symptoms of dysphagia
Spasticity	Orthopedics / physical medicine & rehab / PT & OT incl stretching to help avoid contractures & falls	Consider need for positioning & mobility devices, disability parking placard.

Table 6. continued from previous page.

Manifestation/Concern	Treatment	Considerations/Other
Eyes	Per ophthalmologist	Refractive errors, strabismus, eye lubrication for alacrima
	Per ophthalmic subspecialist	More complex findings (e.g., cataract, retinal dystrophy)
	Low vision services	<ul style="list-style-type: none"> • Children: through early intervention programs &/or school district • Adults: low vision clinic &/or community vision service / OT / mobility services
Cerebral visual impairment	No specific treatment	Early intervention program to stimulate visual development
Hearing	Hearing aids may be helpful per otolaryngologist.	Community hearing services through early intervention or school district
Bowel dysfunction	Stool softeners, prokinetics, osmotic agents, laxatives, or bowel washout w/flatulence tube & warm water	Daily for maintenance &/or as needed
Genitourinary	Per urologist	<ul style="list-style-type: none"> • Straight catheterization on daily schedule • Surgical interventions, such as vesicostomy, as needed
	Per nephrologist	Standard mgmt for hydronephrosis & renal anomalies
Respiratory	Per pulmonologist	Consider oscillating vests to loosen & thin mucus, supplemental oxygen, CPAP, mucus suctioning, & chest physiotherapy
Cancer (classic SGS only)	<ul style="list-style-type: none"> • Therapy depending on type of cancer • Standard guidelines for respective cancer may be followed 	Chemotherapy dose intensification does not seem to be feasible due to ↑ likelihood of infections
Infections	Treatment depending on type of infection	Consider prophylactic antibiotics for recurrent infections.
Cardiac anomalies	Per cardiologist	
Sleep	Monitor for sleep disturbances.	Consider polysomnography/EEG when indicated.
Dental	Per dentist	Dental care w/attention to gingival hypertrophy, crowding, hypodontia, & delayed tooth eruption
Family/Community	<ul style="list-style-type: none"> • Ensure appropriate social work involvement to connect families w/ local resources, palliative care, respite, & support. • Coordinate care to manage multiple subspecialty appointments, equipment, medications, & supplies. 	Ongoing assessment of need for palliative care involvement &/or home nursing
Palliative care	Per palliative team	<ul style="list-style-type: none"> • Based on needs of affected person • Hospice services if applicable

ACTH = adrenocorticotropic hormone; ASM = anti-seizure medication; CPAP = continuous positive airway pressure; OT = occupational therapy; PT = physical therapy

1. Education of parents/caregivers regarding common seizure presentations is appropriate. For information on non-medical interventions and coping strategies for children diagnosed with epilepsy, see [Epilepsy Foundation Toolbox](#).

Developmental Delay / Intellectual Disability Management Issues

The following information represents typical management recommendations for individuals with developmental delay / intellectual disability in the United States; standard recommendations may vary from country to country.

Ages 0-3 years. Referral to an early intervention program is recommended for access to occupational, physical, speech, and feeding therapy as well as infant mental health services, special educators, and sensory impairment specialists. In the US, early intervention is a federally funded program available in all states that provides in-home services to target individual therapy needs.

Ages 3-5 years. In the US, developmental preschool through the local public school district is recommended. Before placement, an evaluation is made to determine needed services and therapies and an individualized education plan (IEP) is developed for those who qualify based on established motor, language, social, or cognitive delay. The early intervention program typically assists with this transition. Developmental preschool is center based; for children too medically unstable to attend, home-based services are provided.

All ages. Consultation with a developmental pediatrician is recommended to ensure the involvement of appropriate community, state, and educational agencies (US) and to support parents in maximizing quality of life. Some issues to consider:

- IEP services:
 - An IEP provides specially designed instruction and related services to children who qualify.
 - IEP services will be reviewed annually to determine whether any changes are needed.
 - Special education law requires that children participating in an IEP be in the least restrictive environment feasible at school and included in general education as much as possible, when and where appropriate.
 - Vision and hearing consultants should be a part of the child's IEP team to support access to academic material.
 - PT, OT, and speech services will be provided in the IEP to the extent that the need affects the child's access to academic material. Beyond that, private supportive therapies based on the affected individual's needs may be considered. Specific recommendations regarding type of therapy can be made by a developmental pediatrician.
 - As a child enters the teen years, a transition plan should be discussed and incorporated in the IEP. For those receiving IEP services, the public school district is required to provide services until age 21.
- A 504 plan (Section 504: a US federal statute that prohibits discrimination based on disability) can be considered for those who require accommodations or modifications such as front-of-class seating, assistive technology devices, classroom scribes, extra time between classes, modified assignments, and enlarged text.
- Developmental Disabilities Administration (DDA) enrollment is recommended. DDA is a US public agency that provides services and support to qualified individuals. Eligibility differs by state but is typically determined by diagnosis and/or associated cognitive/adaptive disabilities.
- Families with limited income and resources may also qualify for supplemental security income (SSI) for their child with a disability.

Motor Dysfunction

Gross motor dysfunction

- Physical therapy is recommended to maximize mobility and to reduce the risk for later-onset orthopedic complications (e.g., contractures, scoliosis, hip dislocation).

- Consider use of durable medical equipment and positioning devices as needed (e.g., wheelchairs, standers, walkers, bath chairs, orthotics, adaptive strollers).
- For muscle tone abnormalities refer to rehabilitation and physical medicine to consider management of muscle tone that may be an unrecognized source of pain and irritability.

Oral motor dysfunction should be assessed at each visit and clinical feeding evaluations and/or radiographic swallowing studies should be obtained for choking/gagging during feeds, poor weight gain, frequent respiratory illnesses, or feeding refusal that is not otherwise explained. Assuming that the child is safe to eat by mouth, feeding therapy (typically from an occupational or speech therapist) is recommended to help improve coordination or sensory-related feeding issues. Feeds can be thickened or chilled for safety. In the majority of children feeding dysfunction is severe and an NG-tube, GJ-tube, or G-tube will be necessary.

Communication issues. Consider evaluation for alternative means of communication (e.g., [augmentative and alternative communication](#) [AAC]) for individuals who have expressive language difficulties. An AAC evaluation can be completed by a speech-language pathologist who has expertise in the area. The evaluation will consider cognitive abilities and sensory impairments to determine the most appropriate form of communication. AAC devices can range from low-tech, such as picture exchange communication, to high-tech, such as voice-generating devices. AAC devices do not hinder verbal development of speech, but rather support optimal speech and language development.

Neurobehavioral Concerns

Consultation with a developmental pediatrician may be helpful in guiding parents in appropriate behavior management strategies and therapies that may benefit the child and/or prescribing medications as needed. Severe irritability requires evaluation to determine an underlying medical cause such as urinary tract infection, hydrocephalus, or – in children with classic SGS – sacroccygeal teratoma.

Surveillance

To monitor existing manifestations, the individual's response to supportive care, and the emergence of new manifestations, the evaluations summarized in Table 7 are recommended.

Table 7. Schinzel-Giedion syndrome: Recommended Surveillance

System/Concern	Evaluation	Frequency
Feeding	<ul style="list-style-type: none"> • Measurement of growth parameters (weight, height, & head circumference) • Eval of nutritional status & safety of oral intake incl swallowing problems / dysphagia 	At each visit
Gastrointestinal	<ul style="list-style-type: none"> • Monitor for constipation. • Monitor gastroesophageal reflux disease & perform additional GI assessments if needed. • In case of chronic vomiting, consider gastroparesis. 	
Respiratory	Monitor for evidence of aspiration, breathing problems due to excess mucus production, respiratory insufficiency.	
Neurologic	<ul style="list-style-type: none"> • Monitor those w/seizures as clinically indicated. • Assess for new manifestations such as seizures, changes in tone, & movement disorders. • Consider brain &/or spine MRI depending on clinical changes (incl changes in mood, irritability, alertness). 	

Table 7. continued from previous page.

System/Concern	Evaluation	Frequency
CAKUT	Per treating urologist	<ul style="list-style-type: none"> • Frequency based on clinical findings • Consider bladder atony when urinary tract infections are frequent & persistent.
	Per treating nephrologist	<ul style="list-style-type: none"> • Standard follow up of hydronephrosis & renal function ¹ • Frequency based on type of features
Development	Monitor developmental progress & educational needs.	At each visit
Neurobehavioral	Behavioral assessment incl ↑ irritability or sleep disturbances	
Musculoskeletal	Physical medicine, OT/PT assessment of mobility, self-help skills	
Ophthalmologic involvement	Per treating ophthalmologist(s)	Per treating ophthalmologist(s)
	Low vision services	Per treating clinicians
Neoplasia surveillance ^{2, 3}	Liver ultrasound & serum AFP levels	Every 3 mos until age 4 yrs
	Renal ultrasound exam	Every 3 mos until age 10 yrs
	Pelvic MRI for sacrococcygeal teratoma	Annually or when clinically indicated
	Monitor for signs of leukemia (e.g., ↑ bleeding/bruising).	<ul style="list-style-type: none"> • At each visit • Perform complete blood count when clinically indicated.
Infection surveillance	Assess for respiratory & urinary infections.	At each visit
Dental	Dental eval	Twice a year
Family/Community	Assess family need for social work support (e.g., palliative/respite care, home nursing, other local resources), care coordination, or follow-up genetic counseling if new questions arise (e.g., family planning).	At each visit

AFP = alpha-fetoprotein; CAKUT = congenital anomalies of the kidney and urinary tract; OT = occupational therapy; PT = physical therapy

1. Monitor renal function closely due to high frequency of renal scarring from recurrent pyelonephritis and structural urinary tract anomalies.

2. Based on screening guidelines for other disorders associated with increased risk of childhood cancers in the absence of established guidelines for SGS.

3. For children with atypical SGS, the treating physician may weigh the disadvantages of anesthesia needed to perform an MRI against the possible advantages of a low-risk screen; however, more data are needed to inform these recommendations.

Agents/Circumstances to Avoid

Nephrotoxic drugs such as nonsteroidal anti-inflammatory drugs and vancomycin should be used with caution due to high frequency of chronic renal scarring from recurrent pyelonephritis and structural renal anomalies.

Evaluation of Relatives at Risk

See Genetic Counseling for issues related to testing of at-risk relatives for genetic counseling purposes.

Therapies Under Investigation

Search [ClinicalTrials.gov](https://clinicaltrials.gov) in the US and [EU Clinical Trials Register](https://clinicaltrialsregister.eu) in Europe for access to information on clinical studies for a wide range of diseases and conditions. Note: There may not be clinical trials for this disorder.

Genetic Counseling

Genetic counseling is the process of providing individuals and families with information on the nature, mode(s) of inheritance, and implications of genetic disorders to help them make informed medical and personal decisions. The following section deals with genetic risk assessment and the use of family history and genetic testing to clarify genetic status for family members; it is not meant to address all personal, cultural, or ethical issues that may arise or to substitute for consultation with a genetics professional. —ED.

Mode of Inheritance

Classic and atypical Schinzel-Giedion syndrome (SGS) are autosomal dominant disorders typically caused by a *de novo* *SETBP1* pathogenic variant.

Risk to Family Members

Parents of a proband

- Most probands reported to date with classic or atypical SGS have the disorder as the result of a *de novo* *SETBP1* pathogenic variant.
- Rarely, individuals diagnosed with SGS have the disorder as the result of a pathogenic variant inherited from a parent. Sib recurrence of clinically defined classic SGS, presumed to be due to parental germline mosaicism, has been reported in two families [Schinzel & Giedion 1978, Antich et al 1995]. Transmission of a *SETBP1* pathogenic missense variant from an unaffected parent to a child with atypical SGS has been reported in one family (of note, the possibility of mosaicism in the unaffected parent was not excluded) [Leonardi et al 2020].
- If a molecular diagnosis has been established in the proband, molecular genetic testing is recommended for the parents of the proband to evaluate their genetic status and inform recurrence risk assessment.
- If the pathogenic variant identified in the proband is not identified in either parent and parental identity testing has confirmed biological maternity and paternity, the following possibilities should be considered:
 - The proband has a *de novo* pathogenic variant.
 - The proband inherited a pathogenic variant from a parent with germline (or somatic and germline) mosaicism. Note: Testing of parental leukocyte DNA may not detect all instances of somatic mosaicism and will not detect a pathogenic variant that is present in the germ (gonadal) cells only.

Sibs of a proband. The risk to the sibs of the proband depends on the clinical/genetic status of the proband's parents.

- If a molecular diagnosis has been established in proband and the *SETBP1* pathogenic variant found in the proband cannot be detected in the leukocyte DNA of either parent, the recurrence risk to sibs is slightly greater than that of the general population because of the possibility of parental germline mosaicism [Schinzel & Giedion 1978, Antich et al 1995].
- If the parents have not been tested for the *SETBP1* pathogenic variant but are clinically unaffected, the risk to the sibs of a proband appears to be low. However, sibs of a proband with clinically unaffected parents are still presumed to be at increased risk for SGS because of the possibility of parental germline mosaicism and, in atypical SGS, the possibility of incomplete penetrance or variable expressivity. (Transmission of an

SETBP1 pathogenic variant from an unaffected parent to a child with atypical SGS has been reported in one family [Leonardi et al 2020].)

Offspring of a proband. Individuals with classic SGS are not known to reproduce.

Other family members. Given that most probands with a known heterozygous SGS-related *SETBP1* pathogenic variant reported to date have the disorder as the result of a *de novo* pathogenic variant, the risk to other family members is presumed to be low.

Related Genetic Counseling Issues

Family planning

- The optimal time for determination of genetic risk and discussion of the availability of prenatal/preimplantation genetic testing is before pregnancy.
- It is appropriate to offer genetic counseling (including discussion of potential risks to offspring and reproductive options) to parents of affected individuals.

Prenatal Testing and Preimplantation Genetic Testing

Once the *SETBP1* pathogenic variant has been identified in an affected family member, prenatal and preimplantation genetic testing are possible. Although risk to future pregnancies is presumed to be low as the proband most likely has a *de novo* *SETBP1* pathogenic variant, there is a slightly increased recurrence risk to sibs based on the possibility of parental germline mosaicism and, in atypical SGS, the possibility of incomplete penetrance or variable expressivity [Schinzel & Giedion 1978, Antich et al 1995, Leonardi et al 2020]. Given this risk, prenatal and preimplantation genetic testing may be considered.

Differences in perspective may exist among medical professionals and within families regarding the use of prenatal testing. While most centers would consider use of prenatal testing to be a personal decision, discussion of these issues may be helpful.

Resources

GeneReviews staff has selected the following disease-specific and/or umbrella support organizations and/or registries for the benefit of individuals with this disorder and their families. GeneReviews is not responsible for the information provided by other organizations. For information on selection criteria, click [here](#).

- **Schinzel-Giedion Syndrome Foundation**
Email: contact@sgsfoundation.org
www.sgsfoundation.org
- **American Association on Intellectual and Developmental Disabilities (AAIDD)**
Phone: 202-387-1968
Fax: 202-387-2193
www.aaid.org
- **MedlinePlus**
[Schinzel-Giedion syndrome](#)
- **VOR: Speaking out for people with intellectual and developmental disabilities**
Phone: 877-399-4867
Email: info@vor.net
www.vor.net

- **Human Disease Gene Website Series - Registry**
SETBP1
- **Schinzel-Giedion Syndrome Registry**
www.sgsfoundation.org/sgs-registry

Molecular Genetics

Information in the Molecular Genetics and OMIM tables may differ from that elsewhere in the GeneReview: tables may contain more recent information. —ED.

Table A. Schinzel-Giedion Syndrome: Genes and Databases

Gene	Chromosome Locus	Protein	Locus-Specific Databases	HGMD	ClinVar
<i>SETBP1</i>	18q12.3	SET-binding protein	SETBP1 database	SETBP1	SETBP1

Data are compiled from the following standard references: gene from [HGNC](#); chromosome locus from [OMIM](#); protein from [UniProt](#). For a description of databases (Locus Specific, HGMD, ClinVar) to which links are provided, click [here](#).

Table B. OMIM Entries for Schinzel-Giedion Syndrome ([View All in OMIM](#))

269150	SCHINZEL-GIEDION MIDFACE RETRACTION SYNDROME
611060	SET-BINDING PROTEIN 1; SETBP1

Molecular Pathogenesis

SETBP1 encodes SET-binding protein (SEB), which binds the SET nuclear oncogene that is involved in DNA replication. Although the function of SEB is not yet fully understood, the protein is known to be involved in cell proliferation, neuronal migration, and neurogenesis [Acuna-Hidalgo et al 2017].

Classic Schinzel-Giedion syndrome (SGS) is caused by pathogenic heterozygous gain-of-function variants within a **mutational hot spot** of *SETBP1*. This mutational hot spot is comprised of a 12-base-pair region within exon 4 encoding for amino acid residues 868 to 871 within the SKI domain. These four residues are part of a canonical degron sequence recognized by ubiquitin E3 ligases and are important for regulating protein degradation. In the presence of these pathogenic variants, the degradation "machinery" of the cell cannot bind to the protein efficiently. Therefore, less protein is degraded, which essentially results in overproduction of SEB.

Atypical SGS is caused by other pathogenic *SETBP1* missense variants located near – but not within – the mutational hot spot and are associated with phenotypes with considerable clinical overlap with classic SGS.

Notably, other *SETBP1* pathogenic missense variants either close to or further away from the mutational hot spot may be associated with a broad spectrum of phenotypes with insufficient clinical overlap with either SGS or *SETBP1* haploinsufficiency disorder and are therefore considered to be associated with "*SETBP1*-related disorders" (see Genetically Related Disorders). These variants are expected to have heterogeneous functional effects (independent of SEB overabundance), including impaired ubiquitination, DNA binding, and transcription. Knowledge regarding associated phenotypes, as well as the spectrum of severity (including for classic and atypical SGS syndrome-associated pathogenic variants) is expected to continue to evolve as more variants are identified.

Mechanism of disease causation. Gain of function

Table 8. *SETBP1* Pathogenic Variants Referenced in This *GeneReview*

Reference Sequences	DNA Nucleotide Change	Predicted Protein Change	Comment
NM_015559.3 NP_056374.2	c.2602G>A	p.Asp868Asn	Pathogenic gain-of-function variants clustering w/in a 12-bp hot spot in exon 4 (a degron region) assoc w/classic SGS syndrome ¹
	c.2602G>T	p.Asp868Tyr	
	c.2603A>C	p.Asp868Ala	
	c.2605A>G	p.Ser869Gly	
	c.2606G>A	p.Ser869Asn	
	c.2607C>G	p.Ser869Arg	
	c.2608G>T	p.Gly870Cys	
	c.2608G>A	p.Gly870Ser	
	c.2609G>A	p.Gly870Asp	
	c.2612T>G	p.Ile871Ser	
	c.2612T>C	p.Ile871Thr	

Variants listed in the table have been provided by the authors. *GeneReviews* staff have not independently verified the classification of variants.

GeneReviews follows the standard naming conventions of the Human Genome Variation Society (varnomen.hgvs.org). See [Quick Reference](#) for an explanation of nomenclature.

1. It is expected that there will be a spectrum of severity even within classic SGS syndrome-associated pathogenic variants as knowledge regarding the clinical and molecular spectrum continues to evolve. Further, pathogenic *SETBP1* missense variants close to this mutational hot spot may lead to features that partially overlap with either SGS or *SETBP1* haploinsufficiency disorder (see Genetically Related Disorders).

Chapter Notes

Author Notes

Dr Bregje van Bon is involved in clinical follow up of individuals with *SETBP1*-related disorders. She would be happy to communicate with persons who have any questions regarding diagnosis of *SETBP1* related disorders or other considerations.

Acknowledgments

The authors would like to thank all individuals with SGS, their families, and the Schinzel-Giedion Syndrome Foundation for sharing their medical and personal stories at the clinic and during live and online international meetings. They are the true experts, and we have been able write this *GeneReview* chapter based on their knowledge.

Revision History

- 7 March 2024 (bp) Review posted live
- 9 August 2023 (bvb) Original submission

References

Literature Cited

- Acuna-Hidalgo R, Deriziotis P, Steehouwer M, Gilissen C, Graham SA, van Dam S, Hoover-Fong J, Telegrafi AB, Destree A, Smigiel R, Lambie LA, Kayserili H, Altunoglu U, Lapi E, Uzielli ML, Aracena M, Nur BG, Mihci E, Moreira LM, Borges Ferreira V, Horovitz DD, da Rocha KM, Jezela-Stanek A, Brooks AS, Reutter H, Cohen JS, Fatemi A, Smitka M, Grebe TA, Di Donato N, Deshpande C, Vandersteen A, Marques Lourenco C, Dufke A, Rossier E, Andre G, Baumer A, Spencer C, McGaughran J, Franke L, Veltman JA, De Vries BB, Schinzel A, Fisher SE, Hoischen A, van Bon BW. Overlapping SETBP1 gain-of-function mutations in Schinzel-Giedion syndrome and hematologic malignancies. *PLoS Genet.* 2017;13:e1006683. PubMed PMID: 28346496.
- Antich J, Manzanares R, Camarasa F, Krauel X, Vila J, Cusi V. Schinzel-Giedion syndrome: report of two sibs. *Am J Med Genet.* 1995;59:96-9. PubMed PMID: 8849020.
- Bulut O, Ince Z, Altunoglu U, Yildirim S, Coban A. Schinzel-Giedion syndrome with congenital megacalycosis in a Turkish patient: report of SETBP1 mutation and literature review of the clinical features. *Case Rep Genet.* 2017;2017:3740524. PubMed PMID: 29333303.
- Carvalho E, Honjo R, Magalhaes M, Yamamoto G, Rocha K, Naslavsky M, Zatz M, Passos-Bueno MR, Kim C, Bertola D. Schinzel-Giedion syndrome in two Brazilian patients: Report of a novel mutation in SETBP1 and literature review of the clinical features. *Am J Med Genet A.* 2015;167A:1039-46. PubMed PMID: 25663181.
- Herenger Y, Stoetzel C, Schaefer E, Scheidecker S, Maniere MC, Pelletier V, Alembik Y, Christmann D, Clavert JM, Terzic J, Fischbach M, De Saint Martin A, Dollfus H. Long term follow up of two independent patients with Schinzel-Giedion carrying SETBP1 mutations. *Eur J Med Genet.* 2015;58:479-87. PubMed PMID: 26188272.
- Hishimura N, Watari M, Ohata H, Fuseya N, Wakiguchi S, Tokutomi T, Okuhara K, Takahashi N, Iizuka S, Yamamoto H, Mishima T, Fujieda S, Kobayashi R, Cho K, Kuroda Y, Kurosawa K, Tonoki H. Genetic and prenatal findings in two Japanese patients with Schinzel-Giedion syndrome. *Clin Case Rep.* 2016;5:5-8. PubMed PMID: 28096980.
- Hoischen A, van Bon BW, Gilissen C, Arts P, van Lier B, Steehouwer M, de Vries P, de Reuver R, Wieskamp N, Mortier G. De novo mutations of SETBP1 cause Schinzel-Giedion syndrome. *Nature Genet.* 2010;42:483-5. PubMed PMID: 20436468.
- Ko JM, Lim BC, Kim KJ, Hwang YS, Ryu HW, Lee JH, Kim JS, Chae JH. Distinct neurological features in a patient with Schinzel-Giedion syndrome caused by a recurrent SETBP1 mutation. *Childs Nerv Syst.* 2013;29:525-9. PubMed PMID: 23400866.
- Kondoh T, Kamimura N, Tsuru A, Matsumoto T, Matsuzaka T, Moriuchi H. A case of Schinzel-Giedion syndrome complicated with progressive severe gingival hyperplasia and progressive brain atrophy. *Pediatr Int.* 2001;43:181-4. PubMed PMID: 11285076.
- Lehman AM, McFadden D, Pugash D, Sangha K, Gibson WT, Patel MS. Schinzel-Giedion syndrome: report of splenopancreatic fusion and proposed diagnostic criteria. *Am J Med Genet A.* 2008;146A:1299-306. PubMed PMID: 18398855.
- Leonardi E, Bettella E, Pelizza MF, Aspromonte MC, Polli R, Boniver C, Sartori S, Milani D, Murgia A. Identification of SETBP1 mutations by gene panel sequencing in individuals with intellectual disability or with "developmental and epileptic encephalopathy". *Front Neurol.* 2020;11:593446. PubMed PMID: 33391157.
- Leone MP, Palumbo P, Palumbo O, Di Muro E, Chetta M, Laforgia N, Resta N, Stella A, Castellana S, Mazza T, Castori M, Carella M, Bukvic N. The recurrent SETBP1 c.2608G > A, p.(Gly870Ser) variant in a patient with

- Schinzel-Giedion syndrome: an illustrative case of the utility of whole exome sequencing in a critically ill neonate. *Ital J Pediatr.* 2020;46:74. PubMed PMID: 32460883.
- Lestner JM, Chong WK, Offiah A, Kefas J, Vandersteen AM. Unusual neuroradiological features in Schinzel-Giedion syndrome: a novel case. *Clin Dysmorphol.* 2012;21:152-4. PubMed PMID: 22473152.
- López-González V, Domingo-Jiménez MR, Burglen L, Ballesta-Martínez MJ, Whalen S, Piñero-Fernández JA, Guillén-Navarro E. [Schinzel-Giedion syndrome: a new mutation in SETBP1]. *An Pediatr (Barc).* 2015;82:e12-6. PubMed PMID: 25082129.
- Makishima H, Yoshida K, Nguyen N, Przychodzen B, Sanada M, Okuno Y, Ng KP, Gudmundsson KO, Vishwakarma BA, Jerez A, Gomez-Segui I, Takahashi M, Shiraishi Y, Nagata Y, Guinta K, Mori H, Sekeres MA, Chiba K, Tanaka H, Muramatsu H, Sakaguchi H, Paquette RL, McDevitt MA, Kojima S, Saunthararajah Y, Miyano S, Shih LY, Du Y, Ogawa S, Maciejewski JP. Somatic SETBP1 mutations in myeloid malignancies. *Nat Genet.* 2013;45:942-6. PubMed PMID: 23832012.
- Matsumoto F, Tohda A, Shimada K, Okamoto N. Malignant retroperitoneal tumor arising in a multicystic dysplastic kidney of a girl with Schinzel-Giedion syndrome. *Int J Urol.* 2005;12:1061-2. PubMed PMID: 16409612.
- Minn D, Christmann D, De Saint-Martin A, Alembik Y, Eliot M, Mack G, Fischbach M, Flament J, Veillon F, Dollfus H. Further clinical and sensorial delineation of Schinzel-Giedion syndrome: report of two cases. *Am J Med Genet.* 2002;109:211-7. PubMed PMID: 11977181.
- Miyake F, Kuroda Y, Naruto T, Ohashi I, Takano K, Kurosawa K. West syndrome in a patient with Schinzel-Giedion syndrome. *J Child Neurol.* 2015;30:932-6. PubMed PMID: 25028416.
- Richards S, Aziz N, Bale S, Bick D, Das S, Gastier-Foster J, Grody WW, Hegde M, Lyon E, Spector E, Voelkerding K, Rehml HL, et al. Standards and guidelines for the interpretation of sequence variants: a joint consensus recommendation of the American College of Medical Genetics and Genomics and the Association for Molecular Pathology. *Genet Med.* 2015;17:405-24. PubMed PMID: 25741868.
- Santos H, Cordeiro I, Medeira A, Mendonça E, Antunes NL, Rosa FC. Schinzel-Giedion syndrome. A patient with hypothyroidism and diabetes insipidus. *Genet Couns.* 1994;5:187-9. PubMed PMID: 7917131.
- Schinzel A, Giedion A. A syndrome of severe midface retraction, multiple skull anomalies, clubfeet, and cardiac and renal malformations in sibs. *Am J Med Genet.* 1978;1:361-75. PubMed PMID: 665725.
- Stenson PD, Mort M, Ball EV, Chapman M, Evans K, Azevedo L, Hayden M, Heywood S, Millar DS, Phillips AD, Cooper DN. The Human Gene Mutation Database (HGMD®): optimizing its use in a clinical diagnostic or research setting. *Hum Genet.* 2020;139:1197-207. PubMed PMID: 32596782.
- Sullivan JA, Stong N, Baugh EH, McDonald MT, Takeuchi A, Shashi V. A pathogenic variant in the SETBP1 hotspot results in a forme-fruste Schinzel-Giedion syndrome. *Am J Med Genet A.* 2020;182:1947-51. PubMed PMID: 32445275.
- Suphapeetiporn K, Srichomthong C, Shotelersuk V. SETBP1 mutations in two Thai patients with Schinzel-Giedion syndrome. *Clin Genet.* 2011;79:391-3. PubMed PMID: 21371013.
- Takeuchi A, Okamoto N, Fujinaga S, Morita H, Shimizu J, Akiyama T, Ninomiya S, Takanashi J, Kubo T. Progressive brain atrophy in Schinzel-Giedion syndrome with a SETBP1 mutation. *Eur J Med Genet.* 2015;58:369-71. PubMed PMID: 26096993.
- Volk A, Conboy E, Wical B, Patterson M, Kirmani S. Whole-exome sequencing in the clinic: lessons from six consecutive cases from the clinician's perspective. *Mol Syndromol.* 2015;6:23-31. PubMed PMID: 25852444.
- Yang H, Liu Z, Chen D, Lin W, Wang L, Chen T, Wang R, Yan X. Detection of a novel SETBP1 variant in a Chinese neonate with Schinzel-Giedion syndrome. *Front Pediatr.* 2022;10:920741. PubMed PMID: 36147799.

License

GeneReviews® chapters are owned by the University of Washington. Permission is hereby granted to reproduce, distribute, and translate copies of content materials for noncommercial research purposes only, provided that (i) credit for source (<http://www.genereviews.org/>) and copyright (© 1993-2024 University of Washington) are included with each copy; (ii) a link to the original material is provided whenever the material is published elsewhere on the Web; and (iii) reproducers, distributors, and/or translators comply with the [GeneReviews® Copyright Notice and Usage Disclaimer](#). No further modifications are allowed. For clarity, excerpts of GeneReviews chapters for use in lab reports and clinic notes are a permitted use.

For more information, see the [GeneReviews® Copyright Notice and Usage Disclaimer](#).

For questions regarding permissions or whether a specified use is allowed, contact: admasst@uw.edu.