



Gefitinib

Updated: March 6, 2018.

OVERVIEW

Introduction

Gefitinib is a selective tyrosine kinase receptor inhibitor used in the therapy of non-small cell lung cancer. Gefitinib therapy is associated with transient elevations in serum aminotransferase levels and rare instances of clinically apparent acute liver injury.

Background

Gefitinib (ge fi' ti nib) is a selective inhibitor of the tyrosine kinase receptor of epidermal growth factor (EGFR), which is often mutated and over expressed in cancer cells, particularly non-small cell lung cancer and some forms of breast cancer. The mutated EGF tyrosine kinase receptor is constitutively expressed which causes unregulated cell growth and proliferation. By inhibition of this growth factor receptor, gefitinib blocks the intracellular Ras signaling transduction cascade, which results in inhibition of the malignant cell growth. Highest rates of response to gefitinib are seen in patients with activating mutations of EGFR in the tumor tissue. Gefitinib received approval for use in the United States in 2009 for the treatment of advanced non-small cell lung cancer after failure of other therapies, but has been available in Japan since 2002. Gefitinib is available in tablets of 250 mg under the brand name Iressa. The recommended dose is 250 mg by mouth once daily, with dose modification based upon tolerance. Side effects are common and include diarrhea, nausea, vomiting, anorexia, mouth ulcers, conjunctivitis, rash, pruritus and fatigue. Uncommon serious side effects include interstitial lung disease and corneal erosions.

Hepatotoxicity

In large early clinical trials, elevations in serum aminotransferase levels occurred in 9% to 13% of patients treated with standard doses of gefitinib, and 2% to 4% of patients had to stop therapy because of elevations above 5 times the upper limit of normal. Serum enzyme elevations typically arise after 4 to 12 weeks of treatment with a hepatocellular pattern. Immunoallergic and autoimmune features have not been described, but rash is common in patients receiving gefitinib. Most cases of liver injury due to gefitinib in the literature have been minimally or not symptomatic, and the injury resolved within 1 to 2 months of stopping the drug. Restarting therapy was usually but not always followed by rapid recurrence of serum enzyme elevations, and corticosteroid therapy did not appear to prevent this recurrence. In some instances, lower doses were tolerated with minimal or no ALT elevations. Periodic monitoring of liver tests during therapy is recommended. Despite the frequency of serum aminotransferase elevations during gefitinib therapy, cases of clinically apparent liver injury with jaundice are rare. Cases of severe and fatal hepatotoxicity have been reported to the sponsor and monitoring of liver tests during therapy is recommended.

Likelihood score: B (likely cause of clinically apparent liver injury).

Mechanism of Injury

The cause of the liver injury due to gefitinib is unknown. Gefitinib is metabolized in the liver largely via CYP 3A4, and liver injury may be due to accumulation of a toxic or immunogenic intermediate.

Outcome and Management

Serum aminotransferase elevations above 5 times the upper limit of normal (if confirmed) should lead to dose interruption. If changes persist, are severe, or reoccur on restarting, gefitinib should be discontinued. There have been no published reports of acute liver failure, chronic hepatitis or vanishing bile duct syndrome due to gefitinib but the product label mentions severe hepatotoxicity with fatalities occurring in 0.04% of patients. Patients with liver abnormalities during gefitinib therapy generally tolerate other tyrosine kinase receptor inhibitors without recurrence of severe injury.

Drug Class: Antineoplastic Agents, Protein Kinase Inhibitors

CASE REPORT

Case 1. Serum aminotransferase elevations during gefitinib therapy.

[Modified from: Takeda M, Okamoto I, Fukuoka M, Nakagawa K. Successful treatment with erlotinib after gefitinib-related severe hepatotoxicity. *J Clin Oncol* 2010; 28: e273-4. [PubMed Citation](#)]

A 66 year old woman with metastatic non-small cell adenocarcinoma of the lung developed serum aminotransferase elevations during therapy with gefitinib (250 mg daily). She was a nonsmoker and the lung cancer was shown to harbor a deletion in exon 19 of the epidermal growth factor receptor gene, which has been shown to confer sensitivity to inhibition by gefitinib. Serum aminotransferase levels were normal before and during the first 8 weeks of treatment, but became moderately elevated at week 13 (Table). Nevertheless, gefitinib was continued and ursodiol and glycyrrhizate [an herbal medication used in Japan as therapy of liver disease] were started. Serum enzymes gradually improved. However, 36 weeks after starting gefitinib, ALT levels rose markedly [ALT 1011 and AST 599 U/L] and gefitinib was stopped. She was taking no other medications. Abdominal ultrasound was unremarkable. Serum enzymes decreased with stopping gefitinib and 7 weeks later they were normal. Erlotinib (150 mg daily) was started and serum aminotransferase levels remained normal during long term therapy (15 weeks at the time of the report).

Key Points

Medication:	Gefitinib (250 mg daily)
Pattern:	Hepatocellular (R=unable to calculate)
Severity:	1+ (serum enzyme elevations only)
Latency:	12 weeks to initial elevations, 36 weeks to marked elevations
Recovery:	7 weeks
Other medications:	Initially none; later ursodiol and glycyrrhizate

Laboratory Values

Time After Starting	Time After Stopping	ALT (U/L)	AST (U/L)	Other
0	Pre	20	20	Gefitinib started

Table continued from previous page.

Time After Starting	Time After Stopping	ALT (U/L)	AST (U/L)	Other
8 weeks		30	30	
13 weeks		181	84	
14 weeks		200	86	
16 weeks		120	80	
22 weeks		80	60	
26 weeks		40	40	
29 weeks		35	40	
33 weeks		100	70	
36 weeks	0	750	410	Gefitinib stopped
38 weeks	2 weeks	1011	599	
40 weeks	4 weeks	410	100	
42 weeks	6 weeks	70	70	
44 weeks	2 months	40	40	Erlotinib started
12 months	3 months	35	30	
14 months	5 months	20	20	
Normal Values		<35	<40	

* Selected values estimated from Figure 1.

Comment

Elevations in serum aminotransferase levels occur in at least 10% of patients treated with gefitinib, but they are usually mild and self-limited and rise to above 5 times the upper limit (approximately 200 U/L) in only 2% to 4% of patients, and even then may not require drug discontinuation. In this patient, the serum aminotransferase levels rose to more than 20 times the upper limit of normal which led to immediate discontinuation of therapy. Glycyrrhizate is an extract of licorice which is used in Japan as a hepatoprotective agent and usually given intravenously one to three times weekly, but its dose and regimen were not provided in this report. The authors also do not mention whether the patient was symptomatic or jaundiced and results of serum alkaline phosphatase, bilirubin and prothrombin time were not given, nor was information provided about previous liver disease, alcohol use, or results of virologic and immunologic tests to rule out other causes of liver injury. Nevertheless, the timing of presentation and prompt improvement on stopping gefitinib are convincing as was the lack of recurrence with erlotinib treatment. Monitoring of serum enzymes during gefitinib and erlotinib therapy is warranted and the agents should be discontinued if symptoms or jaundice arise or aminotransferase levels remain above 5 times the upper limit of normal in the absence of other possible etiologies.

PRODUCT INFORMATION

REPRESENTATIVE TRADE NAMES

Gefitinib – Iressa®

DRUG CLASS

Box continues on next page...

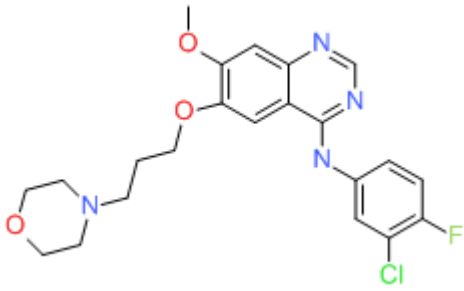
Box continued from previous page.

Antineoplastic Agents

COMPLETE LABELING

Product labeling at DailyMed, National Library of Medicine, NIH

CHEMICAL FORMULA AND STRUCTURE

DRUG	CAS REGISTRY NUMBER	MOLECULAR FORMULA	STRUCTURE
Gefitinib	184475-35-2	C ₂₂ -H ₂₄ -Cl-F-N ₄ -O ₃	 The chemical structure of Gefitinib is shown. It features a central benzimidazole ring system. One nitrogen atom of the benzimidazole is substituted with a 4-chloro-3-fluorophenyl group. The other nitrogen atom is substituted with a propyl chain that is further substituted with a piperidine ring. The benzimidazole ring also has a methoxy group and a propyl chain attached to the benzene ring.

ANNOTATED BIBLIOGRAPHY

References updated: 06 March 2018

Abbreviations: EGFR, epidermal growth factor receptor; NSCLC, non-small cell lung cancer.

Zimmerman HJ. Hepatotoxicity: the adverse effects of drugs and other chemicals on the liver. 2nd ed. Philadelphia: Lippincott, 1999.

(Review of hepatotoxicity published in 1999 before the availability of tyrosine kinase receptor inhibitors).

DeLeve LD. Kinase inhibitors. Gefitinib. Cancer chemotherapy. In, Kaplowitz N, DeLeve LD, eds. Drug-induced liver disease. 3rd ed. Amsterdam: Elsevier, 2013, p. 556.

(Review of hepatotoxicity of cancer chemotherapeutic agents; gefitinib has been linked to reversible serum aminotransferase elevations, but not clearly to symptomatic, clinically apparent liver injury).

Chabner BA, Barnes J, Neal J, Olson E, Mujagic H, Sequist L, Wilson W, et al. Targeted therapies: tyrosine kinase inhibitors, monoclonal antibodies, and cytokines. In, Brunton LL, Chabner BA, Knollman BC, eds. Goodman & Gilman's the pharmacological basis of therapeutics. 12th ed. New York: McGraw-Hill, 2011, pp. 1731-54.

(Textbook of pharmacology and therapeutics).

Fukuoka M, Yano S, Giaccone G, Tamura T, Nakagawa K, Douillard JY, Nishiwaki Y, et al. Multi-institutional randomized phase II trial of gefitinib for previously treated patients with advanced non-small-cell lung cancer. J Clin Oncol 2003; 21: 2237-46. PubMed PMID: 12748244.

(Among 210 patients with advanced lung cancer treated with two doses of gefitinib, serum ALT elevations occurred in 14%, were above 5 times ULN in 4.7%, and 4 patients [2%] withdrew from therapy for serum enzyme elevations).

Kris M, Natale RB, Herbst R, Lynch TJ Jr, Prager D, Belani CP, Schiller JH, et al. Efficacy of gefitinib, an inhibitor of the epidermal growth factor receptor tyrosine kinase, in symptomatic patients with non-small cell lung cancer. *JAMA* 2003; 290: 2149-58. PubMed PMID: 14570950.

(Among 216 patients with advanced lung cancer treated with two doses of gefitinib for an average of 2 months, elevations in ALT >5 times ULN occurred in 3 [1.5%], but none developed symptomatic hepatitis with jaundice).

Lynch TJ, Bell DW, Sordella R, Gurubhagavatula S, Okimoto RA, Brannigan BW, Harris PL, et al. Activating mutations in the epidermal growth factor receptor underlying responsiveness of non-small-cell lung cancer to gefitinib. *N Engl J Med*. 2004; 350: 2129-39. PubMed PMID: 15118073.

(A mutation in EGF tyrosine kinase receptor was identified in 8 of 9 tumors from patients with a clinical response to gefitinib, but in 0 of 7 nonresponders; in vitro, the mutated receptor was more sensitive than the wild type to inhibition by gefitinib).

Birnbaum A, Ready N. Gefitinib therapy for non-small cell lung cancer. *Curr Treat Options Oncol* 2005; 6: 75-81. PubMed PMID: 15610717.

(Review of efficacy and safety of gefitinib therapy for non-small cell lung cancer; hepatotoxicity is not discussed).

Kindler HL, Friberg G, Skoog L, Wade-Oliver K, Vokes EE. Phase I/II trial of gefitinib and oxaliplatin in patients with advanced colorectal cancer. *Am J Clin Oncol* 2005; 28: 340-4. PubMed PMID: 16062074.

(14 patients with advanced lung cancer were treated with gefitinib and oxaliplatin; mild serum ALT elevations occurred in 9 patients [64%]).

Ho C, Davis J, Anderson F, Bebb G, Murray N. Side effects related to cancer treatment: CASE 1. Hepatitis following treatment with gefitinib. *J Clin Oncol* 2005; 23: 8531-3. PubMed PMID: 16293881.

(57 year old woman with advanced lung cancer developed abnormal liver tests 8 weeks after starting gefitinib [AST ~800 U/L], which resolved in 2 months but recurred within a week of restarting [AST~520 U/L], resolving again and recurring even with concurrent prednisone).

Seki N, Uematsu K, Shibakuki R, Eguchi K. Promising new treatment schedule for gefitinib responders after severe hepatotoxicity with daily administration. *J Clin Oncol* 2006; 24: 3213-4; author reply 3214-5. PubMed PMID: 16809744.

(Letter in response to Ho [2005] describing 61 year old Japanese woman who had a clinical response to gefitinib therapy, but developed serum ALT elevations after 8 weeks of therapy, recurring on rechallenge, but later tolerated gefitinib with minimal ALT elevations when given every 5 days instead of daily).

Fujiwara Y, Kiura K, Toyooka S, Takigawa N, Tokumo M, Hotta K, Aoe M, et al. Relationship between epidermal growth factor receptor gene mutations and the severity of adverse events by gefitinib in patients with advanced non-small cell lung cancer. *Lung Cancer* 2006; 52: 99-103. PubMed PMID: 16503086.

(Among 26 patients with non-small cell lung cancer [NSCLC] treated with gefitinib, 11 had EGFR mutations in tumor tissue which correlated with tumor response [78% vs 21% in those without], but not with side effects [any ALT elevation in 36% vs 7%, ALT >5 times ULN in 0% vs 7%]).

Reck M, Buchholz E, Romer KS, Krutzfeldt K, Gatzemeier U, Manegold C. Gefitinib monotherapy in chemotherapy-naïve patients with inoperable stage III/IV non-small-cell lung cancer. *Clin Lung Cancer* 2006; 7: 406-11. PubMed PMID: 16800967.

(Among 58 patients with advanced NSCLC treated with gefitinib, common toxicities were rash, diarrhea, nausea and fatigue; ALT changes not mentioned).

Carlini P, Papaldo P, Fabi A, Felici A, Ruggeri EM, Milella M, Ciccarese M, et al. Liver toxicity after treatment with gefitinib and anastrozole: drug-drug interactions through cytochrome p450? *J Clin Oncol* 2006; 24: e60-1. PubMed PMID: 17158530.

(Letter in response to Ho [2005] describing a 63 year old woman with lung cancer who developed rising ALT elevations after 16 weeks of gefitinib therapy [ALT 77 to 213 U/L], which decreased on stopping and rapidly recurred on restarting).

Jiang H. Overview of gefitinib in non-small cell lung cancer: an Asian perspective. *Jpn J Clin Oncol* 2009; 39: 137-50. PubMed PMID: 19088154.

(Systematic review of the literature on gefitinib therapy of NSCLC, focusing upon differences in response rates between Asian and Western patients that is probably due to different rates of activating mutations; rates of adverse events are similar in Asian and non-Asian patients).

Sanford M, Scott LJ. Gefitinib: a review of its use in the treatment of locally advanced/metastatic non-small cell lung cancer. *Drugs* 2009; 69: 2303-28. PubMed PMID: 19852530.

(Review of the pharmacology, efficacy and safety of gefitinib; overall rate of serum enzyme elevations of >5 times ULN was 9% with gefitinib vs 1% in comparative regimens; severe side effects are more common in elderly).

Ohashi Y, Suzuki K, Sakurai M, Ishikawa H, Onishi T, Nakagaki S, Kato T, et al. [Safety analysis of eight patients treated with erlotinib after severe gefitinib-induced liver injury]. *Gan To Kagaku Ryoho* 2010; 37: 1307-11. Japanese. PubMed PMID: 20647715.

(Abstract only: among 8 patients who developed marked serum ALT elevations on gefitinib therapy, only one had recurrence [with skin rash] when switched to erlotinib).

Kim ST, Lee J, Kim JH, Won YW, Sun JM, Yun J, Park YH, et al. Comparison of gefitinib versus erlotinib in patients with non-small cell lung cancer who failed previous chemotherapy. *Cancer* 2010; 116: 3025-33. PubMed PMID: 20564408.

(Retrospective analysis of 467 patients with NSCLC treated with either gefitinib or erlotinib found similar rates of clinical response; no discussion of adverse events).

Campbell L, Blackhall F, Thatcher N. Gefitinib for the treatment of non-small-cell lung cancer. *Expert Opin Pharmacother* 2010; 11: 1343-57. PubMed PMID: 20426712.

(Review of structure, mechanism of action, pharmacology, efficacy and safety of gefitinib; "Asymptomatic elevations in liver transaminases and bilirubin also occurred commonly but usually recovered upon discontinuation of therapy. Rarely did hepatitis occur").

Takeda M, Okamoto I, Fukuoka M, Nakagawa K. Successful treatment with erlotinib after gefitinib-related severe hepatotoxicity. *J Clin Oncol* 2010; 28: e273-4. PubMed PMID: 20385983.

(66 year old woman with lung cancer developed ALT elevations after 36 weeks of treatment with gefitinib [ALT peak ~1011 U/L], resolving within 8 weeks of stopping and not recurring on starting erlotinib: Case 1).

Ku GY, Chopra A, de Lima Lopes G Jr. Successful treatment of two lung cancer patients with erlotinib following gefitinib-induced hepatotoxicity. *Lung Cancer* 2010; 70: 223-5. PubMed PMID: 20817304.

(Two men, ages 52 and 88 years, with NSCLC developed serum ALT elevations 4 and 6 weeks after starting gefitinib [bilirubin normal, peak ALT 354 and 297 U/L], resolving rapidly on stopping and not recurring when switched to erlotinib).

Yin YM, Geng YT, Shao YF, Hu XL, Li W, Shu YQ, Wang ZX. First-line single agent treatment with gefitinib in patients with advanced non-small-cell lung cancer. *J Exp Clin Cancer Res* 2010; 29: 126. PubMed PMID: 20843324.

(Among 45 Chinese patients with NSCLC treated with gefitinib, liver test abnormalities occurred in 3 [7%], but were mild and self-limited).

Nakatomi K, Nakamura Y, Tetsuya I, Kohno S. Treatment with gefitinib after erlotinib-induced liver injury: a case report. *J Med Case Reports* 2011; 5: 593. PubMed PMID: 22188652.

(31 year old woman with metastatic lung cancer developed enzyme elevations 4 weeks after starting erlotinib [peak ALT 3130 U/L] that fell to normal within 3 weeks of stopping and did not rise again when she was started on gefitinib).

Kijima T, Shimizu T, Nonen S, Furukawa M, Otani Y, Minami T, Takahashi R, et al. Safe and successful treatment with erlotinib after gefitinib-induced hepatotoxicity: difference in metabolism as a possible mechanism. *J Clin Oncol* 2011; 29: e588-90. PubMed PMID: 21502555.

(Two women, ages 67 and 83 years, with lung cancer developed elevated aminotransferase levels 4 and 8 weeks after starting gefitinib [peak ALT 731 and ~450 U/L, bilirubin and Alk P not given], which resolved upon stopping, recurred on restarting, but did not recur when erlotinib was used).

Lai YC, Lin PC, Lai JI, Hsu SY, Kuo LC, Chang SC, Wang WS. Successful treatment of erlotinib-induced acute hepatitis and acute interstitial pneumonitis with high-dose corticosteroid: a case report and literature review. *Int J Clin Pharmacol Ther* 2011 Jul; 49: 461-6. PubMed PMID: 21726497.

(74 year old man developed interstitial pneumonitis and mild serum enzyme elevations 1 month after starting erlotinib [ALT 116 U/L], both of which improved within days on high dose corticosteroids).

Chen J, Gu R, Wang Q, Dassarath M, Yin Z, Yang K, Wu G. Gefitinib-induced hepatotoxicity in patients treated for non-small cell lung cancer. *Onkologie* 2012; 35: 509-13. PubMed PMID: 23007149.

(Among 92 patients with NSCLC treated with gefitinib, 6 [7%] had ALT elevations [range 47-91 U/L] arising 1 week to 6 months after starting, but only one required dose adjustment and all resolved).

Maemondo M, Minegishi Y, Inoue A, Kobayashi K, Harada M, Okinaga S, Morikawa N, et al. First-line gefitinib in patients aged 75 or older with advanced non-small cell lung cancer harboring epidermal growth factor receptor mutations: NEJ 003 study. *J Thorac Oncol* 2012; 7: 1417-22. PubMed PMID: 22895139.

(Among 31 elderly patients with NSCLC, 6 [19%] developed ALT or AST levels above 5 times ULN).

Kunimasa K, Yoshioka H, Iwasaku M, Nishiyama A, Korogi Y, Masuda G, Takaiwa T, et al. Successful treatment of non-small cell lung cancer with gefitinib after severe erlotinib-related hepatotoxicity. *Intern Med* 2012; 51: 431-4. PubMed PMID: 22333382.

(64 year old woman developed liver test elevations 5 weeks after starting erlotinib for NSCLC [bilirubin normal, ALT 129 rising to 617 U/L], recurring when erlotinib was restarted [ALT 1008 U/L by day 3], but not when switched to gefitinib).

Takimoto T, Kijima T, Otani Y, Nonen S, Namba Y, Mori M, Yokota S, et al. Polymorphisms of CYP2D6 gene and gefitinib-induced hepatotoxicity. *Clin Lung Cancer* 2013; 14 (5): 502-7. PubMed PMID: 23664723.

(Distribution of polymorphisms of CYP2D6 gene were similar in 55 patients who developed ALT elevations during gefitinib therapy as found in the general Japanese population; 17 patients were switched to erlotinib and did not have recurrence).

Kitade H, Yamada T, Igarashi S, Hokkoku K, Mori M, Shintaku K, Sagawa M, et al. [Efficacy of low-dose erlotinib against gefitinib-induced hepatotoxicity in a patient with lung adenocarcinoma harboring EGFR mutations]. *Gan To Kagaku Ryoho* 2013; 40: 79-81. Japanese. PubMed PMID: 23306923.

(Abstract only: 80 year old woman developed ALT elevations [3-5 times ULN] during gefitinib therapy, which resolved on stopping and did not recur with erlotinib therapy given for 3 years).

Yoshida T, Yamada K, Azuma K, Kawahara A, Abe H, Hattori S, Yamashita F, et al. Comparison of adverse events and efficacy between gefitinib and erlotinib in patients with non-small-cell lung cancer: a retrospective analysis. *Med Oncol* 2013; 30: 349. PubMed PMID: 23263831.

(Comparison of side effects in 107 patients with NSCLC treated with gefitinib and 35 treated with erlotinib found "liver dysfunction" more frequent with gefitinib than erlotinib [13% vs 6%], whereas overall adverse events leading to drug discontinuation were less common [13% vs 26%]).

Chen X, Pan Y, Zhang S, Chen D, Yang S, Li X, Ma S. Rechallenge with gefitinib following severe drug-induced hepatotoxicity in a patient with advanced non-small cell lung cancer: A case report and literature review. *Oncol Lett* 2014; 7: 878-80. PubMed PMID: 24527096.

(61 year old woman with NSCLC developed marked ALT elevations 14 months after starting gefitinib [ALT 1,130 U/L], which fell to near normal 10 weeks later and did not increase when gefitinib was restarted one year later).

Yonesaka K, Suzumura T, Tsukuda H, Hasegawa Y, Ozaki T, Sugiura T, Fukuoka M. Erlotinib is a well-tolerated alternate treatment for non-small cell lung cancer in cases of gefitinib-induced hepatotoxicity. *Anticancer Res* 2014; 34: 5211-5. PubMed PMID: 25202117.

(Among 25 patients with advanced NSCLC treated with gefitinib, 7 developed ALT elevations above 5 times ULN [specific values not given], all of whom then tolerated erlotinib with no or only minor enzyme elevations).

Durand M, Logerot S, Fonrose X, Schir E. [Treatment with erlotinib after gefitinib induced hepatotoxicity: literature review and case report]. *Therapie* 2014; 69: 163-8. French. PubMed PMID: 24926635.

(Patient with NSCLC developed marked ALT elevations on gefitinib therapy with positive rechallenge, who nevertheless subsequently tolerated erlotinib without recurrence: Abstract only).

Chalasanani N, Bonkovsky HL, Fontana R, Lee W, Stolz A, Talwalkar J, Reddy KR, et al.; United States Drug Induced Liver Injury Network. Features and outcomes of 899 patients with drug-induced liver injury: The DILIN Prospective Study. *Gastroenterology* 2015; 148: 1340-52.e7. PubMed PMID: 25754159.

(Among 899 cases of drug induced liver injury enrolled in a US prospective study between 2004 and 2013, 49 were attributed to antineoplastic agents [5.5%], 3 of which were attributed to kinase inhibitors [imatinib, lapatinib], but none to erlotinib or gefitinib).

Zenke Y, Umemura S, Sugiyama E, Kirita K, Matsumoto S, Yoh K, Niho S, et al. Successful treatment with afatinib after grade 3 hepatotoxicity induced by both gefitinib and erlotinib in EGFR mutation-positive non-small cell lung cancer. *Lung Cancer* 2016; 99: 1-3. PubMed PMID: 27565905.

(57 year old man with NSCLC developed ALT elevations 7 weeks after starting gefitinib [bilirubin 2.0 mg/dL, ALT peak 594 U/L], which resolved upon stopping but he then developed worsening jaundice within a week of starting erlotinib [bilirubin 5.4 mg/dL, ALT normal], and later tolerated afatinib; genetic testing revealed Gilbert syndrome and "poor metabolizer" phenotype of CYP 3A5).

Ueda H, Hayashi H, Kudo K, Takeda M, Nakagawa K. Successful treatment with afatinib after gefitinib- and erlotinib-induced hepatotoxicity. *Invest New Drugs* 2016; 34: 797-9. PubMed PMID: 27550238.

(67 year old woman with metastatic NSCLC developed ALT elevations 16 weeks after starting gefitinib [ALT 223 U/L] which improved upon stopping, recurred with restarting gefitinib and later recurred 10 weeks after starting erlotinib [ALT 262 U/L], which improved on stopping but recurred even with lower doses, but subsequent ALT levels remained normal on switching to afatinib).

Toba H, Sakiyama S, Takizawa H, Tangoku A. Safe and successful treatment with afatinib in three postoperative non-small cell lung cancer patients with recurrences following gefitinib/erlotinib-induced hepatotoxicity. *J Med Invest* 2016; 63 (1-2): 149-51. PubMed PMID: 27040072.

(Two women and one man, ages 63 to 73 years with NSCLC developed ALT elevations 4-8 weeks after starting gefitinib [which recurred in one 6 weeks after switching to erlotinib], but all three tolerated long term afatinib [7 months] without recurrence of enzyme elevations).

Bunchorntavakul C, Reddy KR. Drug hepatotoxicity: newer agents. Clin Liver Dis 2017; 21: 115-34. PubMed PMID: 27842767.

(Review of the hepatotoxicity of recently approved medications including the tyrosine kinase inhibitors erlotinib and gefitinib which has been linked to serum enzyme elevations in 10-24% of patients and above 5 times ULN in 2-4% as well as individual cases of severe injury, some of which have been fatal).

Sugiyama E, Umemura S, Nomura S, Kirita K, Matsumoto S, Yoh K, Niho S, et al. Impact of single nucleotide polymorphisms on severe hepatotoxicity induced by EGFR tyrosine kinase inhibitors in patients with non-small cell lung cancer harboring EGFR mutations. Lung Cancer 2015; 90: 307-13. PubMed PMID: 26323212.

(Among 60 patients with NSCLC treated with gefitinib, 19 [32%] developed "severe" liver test abnormalities which was more frequent in those with poor metabolized phenotype [48% vs 14%]; 9 patients were switched to erlotinib and did not develop recurrence of severe injury).

Takeda M, Okamoto I, Nakagawa K. Pooled safety analysis of EGFR-TKI treatment for EGFR mutation-positive non-small cell lung cancer. Lung Cancer 2015; 88: 74-9. PubMed PMID: 25704957.

(A pooled analysis of 21 trials of tyrosine kinase inhibitors of EGFR found higher reported rates of "grade 3" hepatotoxicity with gefitinib [18%] than with erlotinib [5.4%] and afatinib [1.7%], and hepatotoxicity was listed as the cause of drug discontinuation in 25% of cases).

Park K, Tan EH, O'Byrne K, Zhang L, Boyer M, Mok T, Hirsh V, et al. Afatinib versus gefitinib as first-line treatment of patients with EGFR mutation-positive non-small-cell lung cancer (LUX-Lung 7): a phase 2B, open-label, randomised controlled trial. Lancet Oncol 2016; 17: 577-89. PubMed PMID: 27083334.

(Among 319 patients with EGFR mutant positive NSCLC treated with afatinib [40 mg] or gefitinib [250 mg] daily, progression-free survival was similar in both groups [11.0 vs 10.9 months] as were overall rates of adverse events, although ALT or AST elevations were less frequent with afatinib [all elevations 10% vs 24%, elevations above 5 times ULN 0% vs 1%] and one patient on gefitinib developed fatal acute liver failure).

Imai A, Hachiya T, Ikuyama Y, Sonehara K, Fujimori A, Shiba H, Atobe O. [Successful treatment of non-small cell lung cancer with afatinib after gefitinib-induced hepatotoxicity]. Gan To Kagaku Ryoho 2016; 43: 91-4. Japanese. PubMed PMID: 26809532.

(Have).

Wang J, Wu Y, Dong M, He X, Wang Z, Li J, Wang Y. Observation of hepatotoxicity during long-term gefitinib administration in patients with non-small-cell lung cancer. Anticancer Drugs 2016; 27: 245-50. PubMed PMID: 26633888.

(Among 101 patients with advanced NSCLC treated with gefitinib for 3-60 months, 40 [40%] developed abnormal liver tests which were above 5 times ULN in 4, but levels often resolved with continued therapy or remained in the mild range during long term use).

Liu Y, Zhang Y, Feng G, Niu Q, Xu S, Yan Y, Li S, Jing M. Comparison of effectiveness and adverse effects of gefitinib, erlotinib and icotinib among patients with non-small cell lung cancer: A network meta-analysis. Exp Ther Med 2017; 14: 4017-32. PubMed PMID: 29104622.

(In a network analysis of 7168 patients who received gefitinib, erlotinib or icotinib in 43 studies, clinical outcomes and rates of liver test abnormalities were similar among the three tyrosine kinase inhibitors).

Cho S, Yee J, Kim JY, Jeong Rhie S, Gwak HS. Effects of concomitant medication use on gefitinib-induced hepatotoxicity. J Clin Pharmacol 2018; 58: 263-8. PubMed PMID: 28981161.

(Among 497 Korean patients with lung cancer treated with gefitinib, 197 [40%] developed liver test abnormalities which occurred more frequently among those below the age of 65 [45%], and those receiving an H2 blocker or proton pump inhibitor [47%]).

Wu YL, Cheng Y, Zhou X, Lee KH, Nakagawa K, Niho S, Tsuji F, et al. Dacomitinib versus gefitinib as first-line treatment for patients with EGFR-mutation-positive non-small-cell lung cancer (ARCHER 1050): a randomised, open-label, phase 3 trial. *Lancet Oncol* 2017; 18: 1454-66. PubMed PMID: 28958502.

(Among 452 patients with advanced NSCLC treated with dacomitinib or gefitinib for a median duration of 22 months, progression free survival was slightly better with dacomitinib [14.7 vs 9.2 months] but severe adverse events were more frequent, although ALT elevations above 5 times ULN arose in less [1% vs 8%]).