



Rofecoxib

Updated: March 20, 2020.

OVERVIEW

Introduction

Rofecoxib is a nonsteroidal antiinflammatory drug (NSAID) that selectively inhibits cyclooxygenase-2 (Cox-2), which was used in the therapy of chronic arthritis and mild-to-moderate musculoskeletal pain. Rofecoxib was withdrawn in 2004 because of an association with an increase in cardiovascular events with its long term use. Rofecoxib had also been linked transient serum aminotransferase elevations during therapy and to rare instances of idiosyncratic drug induced liver disease.

Background

Rofecoxib (roe" fe kox' ib) is a nonsteroidal antiinflammatory drug that acts through selective inhibition of cyclooxygenase-2 resulting in decreased prostaglandin synthesis and thereby decreasing inflammation, fever and pain. The specificity for Cox-2 is believed to make rofecoxib less likely to cause gastrointestinal mucosal injury compared to standard NSAIDs that inhibit both Cox-1 and Cox-2 enzymes. Rofecoxib was approved for use as therapy of chronic arthritis due to osteoarthritis, rheumatoid arthritis and ankylosing spondylitis, as well as for acute pain from musculoskeletal conditions and trauma and for primary dysmenorrhea in 1998. Subsequently, large scale prospective studies suggested that use of rofecoxib was associated with an increased rate of cardiovascular and cerebrovascular events, and the drug was withdrawn in September 2004. Rofecoxib was previously available by prescription as capsules of 12.5 and 25 mg under the commercial name Vioxx and was given in several week courses for acute pain or trauma and long term for chronic arthritis. The typically recommended dose was 12.5 to 25 mg once daily. As with other NSAIDs, rofecoxib is generally well tolerated, but side effects can include headache, dizziness, somnolence, dyspepsia, abdominal discomfort, diarrhea, peripheral edema and hypersensitivity reactions. Rare but serious adverse events from NSAIDs include gastrointestinal ulceration and bleeding, increased risk for cardiovascular disease, renal dysfunction and hypersensitivity reactions including anaphylaxis, exfoliative dermatitis and Stevens Johnson syndrome.

Hepatotoxicity

In clinical studies involving several thousand patients treated for at least 3 months, the rate of serum aminotransferase enzyme elevations above three times the upper limit of the normal range was 1.8% in rofecoxib treated compared to 0.3% in placebo treated patients and 0.1-0.4% in patients receiving other common NSAIDs. Thus, ALT elevations due to rofecoxib were uncommon and usually of minimal clinical significance, resolving even with drug continuation.

In rare instances, rofecoxib can cause clinically apparent, symptomatic drug induced liver injury with jaundice. The pattern of liver enzyme elevations has usually been cholestatic or mixed (Case 1), although hepatocellular

patterns of injury have also been described. The latency to onset of liver injury was extremely variable, ranging from a few weeks to several years, but was typically within 1 to 12 weeks of starting. Autoimmune and immunoallergic features were uncommon.

Likelihood score: C (probable rare cause of clinically apparent liver injury).

Mechanism of Injury

The cause of acute hepatic injury from rofecoxib is unknown. The clinical pattern of injury resembles that of other NSAID induced liver injury.

Outcome and Management

The idiosyncratic liver injury due to rofecoxib can lead to prolonged jaundice, but has not been associated with acute liver failure or vanishing bile duct syndrome. In the few cases that have been described, the time to recovery has varied greatly, but is usually 1 to 3 months. Rechallenge should be avoided, but there is little information to suggest that there is cross reactivity with other NSAIDs.

Drug Class: [Nonsteroidal Antiinflammatory Drugs](#)

CASE REPORT

Case 1. Acute hepatocellular injury with jaundice due to rofecoxib.(1).

A 76 year old woman developed jaundice and pruritus 22 months after starting rofecoxib (25 mg daily) for osteoarthritis. She had no history of liver disease, alcohol abuse, drug allergies or risk factors for viral hepatitis. Her other medical condition included polymyalgia rheumatica for which she took prednisone (3 mg daily) and hypothyroidism for which she took levothyroxine (72 mcg daily). She took multivitamins, but no other over-the-counter or herbal medications. On examination, she was jaundiced and had mild hepatic tenderness, but no fever, rash, lymphadenopathy or signs of chronic liver disease. She was admitted for evaluation and rofecoxib was discontinued. Laboratory tests showed a total bilirubin of 5.6 mg/dL with a direct fraction of 5.2 mg/dL and modest elevations in aminotransferase and alkaline phosphatase levels (Table). Tests for viral hepatitis and autoimmune liver disease were negative. Imaging of the abdomen and liver were normal without evidence of biliary obstruction. Her jaundice and pruritus worsened. Magnetic resonance and endoscopic retrograde cholangiopancreatography (ERCP) were done and were normal. A liver biopsy showed intrahepatic cholestasis and mild bile duct damage with mild portal inflammation compatible with a drug induced cholestatic hepatitis. Subsequently, she improved and she was asymptomatic and liver tests were near normal when she was seen approximately 3 months after presentation.

Key Points

Medication:	Rofecoxib (25 mg daily)
Pattern:	Mixed-cholestatic (R=2.4)
Severity:	3+ (jaundice and hospitalization)
Latency:	22 months
Recovery:	Nearly complete within 3 months
Other medications:	Levothyroxine, prednisone, multivitamins

Laboratory Values

Weeks After Stopping	ALT (U/L)	Alk P (U/L)	Bilirubin (mg/dL)	Other
0	239	314	5.6	Rofecoxib stopped
2	89	217	12.2	ERCP normal
4	Liver biopsy showing intrahepatic cholestasis			
~12	62	187	0.8	
Normal	<40	<125	<1.2	

Comment

The history and presentation of this case were very typical of a drug induced cholestatic hepatitis and the only medication that could be implicated was rofecoxib which had been taken for 22 months. The latency to onset is atypical, however, but careful evaluation for other causes of obstructive jaundice was unrevealing, and she recovered with stopping the medication. Information of cross sensitivity to other NSAIDs would have been helpful.

PRODUCT INFORMATION

REPRESENTATIVE TRADE NAMES

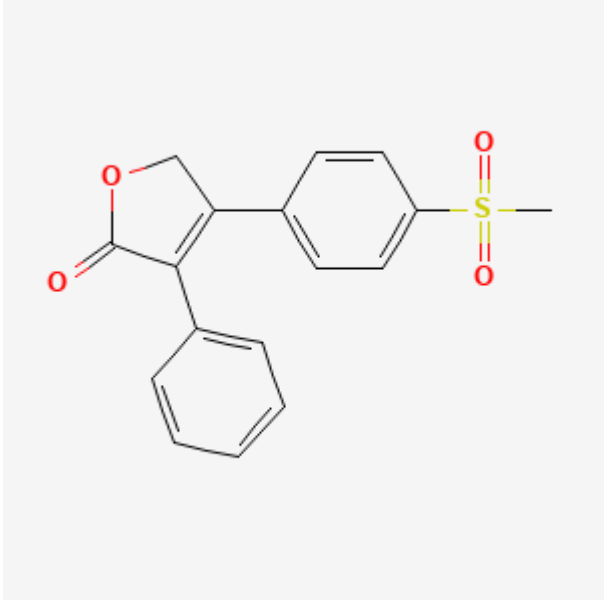
Rofecoxib – Vioxx®

(Removed from Market Worldwide, 2004)

DRUG CLASS

Nonsteroidal Antiinflammatory Drugs

CHEMICAL FORMULA AND STRUCTURE

DRUG	CAS REGISTRY NUMBER	MOLECULAR FORMULA	STRUCTURE
Rofecoxib	162011-90-7	C ₁₇ H ₁₄ O ₄ S	 <p>The chemical structure of Rofecoxib is shown. It consists of a central benzene ring substituted with a methylsulfonyl group (-SO₂CH₃) at the para position and a 2-phenyl-2-oxo-1,3-dioxolane-5-yl group at the other para position. The dioxolane ring is a five-membered ring containing one oxygen atom and a carbonyl group (=O) at the 2-position, with a phenyl ring attached at the 5-position.</p>

CITED REFERENCE

1. Papachristou GI, Demetris AJ, Rabinovitz M. Acute cholestatic hepatitis associated with long-term use of rofecoxib. *Dig Dis Sci.* 2004;49:459–61. PubMed PMID: 15139498.

ANNOTATED BIBLIOGRAPHY

References updated: 20 March 2020

Abbreviations: NSAID, nonsteroidal antiinflammatory drugs.

Zimmerman HJ. Nonsteroidal anti-inflammatory drugs. In, Zimmerman HJ. *Hepatotoxicity: the adverse effects of drugs and other chemicals on the liver.* 2nd ed. Philadelphia: Lippincott, 1999, pp. 517-41.

(Expert review of NSAID induced liver injury from 1999; rofecoxib was not discussed).

Lewis JH, Stine JG. Nonsteroidal anti-inflammatory drugs and leukotriene receptor antagonists: pathology and clinical presentation of hepatotoxicity. In, Kaplowitz N, DeLeve LD, eds. *Drug-induced liver disease.* 3rd Edition. Amsterdam: Elsevier, 2013. pp. 370-402.

(Expert review of liver injury caused by NSAIDs mentions that rofecoxib can cause serum enzyme elevations and has been linked to rare instances of clinically apparent liver injury).

Grossner T, Smyth EM, Fitzgerald GA. Pharmacotherapy of inflammation, fever, pain, and gout. In, Brunton LL, Hilal-Dandan R, Knollman BC. *Goodman & Gilman's The pharmacological basis of therapeutics,* 13th ed. New York: McGraw-Hill, 2018. pp. 685-709.

(Textbook of pharmacology and therapeutics).

McCormick PA, Kennedy F, Curry M, Traynor O. COX 2 inhibitor and fulminant hepatic failure. *Lancet.* 1999;353:40–1. PubMed PMID: 10023957.

(Case of ALF due to nimesulide, a Cox-2 inhibitor that was licensed in Europe, but not the US. Symptoms arose at 2 and jaundice at 7 weeks with ALT rising from 187 to 2857 U/L, Alk P from 50 to 114 U/L; patient had liver transplantation, but died of primary graft non-function).

Huster D, Schubert C, Berr F, Mössner J, Caca K. Rofecoxib-induced cholestatic hepatitis: treatment with molecular adsorbent recycling system (MARS). *J Hepatol.* 2002;37:413–4. PubMed PMID: 12175641.

(52 year old woman developed jaundice and itching 3 months after starting rofecoxib [bilirubin 24.6 mg/dL, ALT 228 U/L, Alk P 1314 U/L], with prolonged jaundice treated with an extracorporeal liver assist device and ultimately resolving 6 months later).

Harsch IA, Michaeli P, Hahn EG, Konturek PC, Klein R. A rare case of rofecoxib-induced cholestatic hepatitis. *Dig Liver Dis.* 2003;35:911–2. PubMed PMID: 14703890.

(73 year old woman developed jaundice and itching 10 days after starting rofecoxib [bilirubin 19.9 mg/dL, ALT 440 U/L, Alk P 435 U/L], positive lymphocyte stimulation test, no information on recovery).

Linares P, Vivas S, Jorquera F, Olcoz JL, de Leon B, Oritz de Urbina J. Severe cholestasis and acute renal failure related to rofecoxib. *Am J Gastroenterol.* 2004;99:1622–3. PubMed PMID: 15307886.

(74 year old woman developed jaundice 2 months after starting rofecoxib [bilirubin 12.0 rising to 29 mg/dL, ALT 31 U/L, Alk P 2968 U/L], with bloody diarrhea and acute renal failure, ultimately resolving on prednisone, but Alk P elevations were still present 2 years later).

- Papachristou GI, Demetris AJ, Rabinovitz M. Acute cholestatic hepatitis associated with long-term use of rofecoxib. *Dig Dis Sci*. 2004;49:459–61. PubMed PMID: 15139498.
- (76 year old woman developed jaundice and pruritus 22 months after starting rofecoxib [bilirubin 5.6 rising to 12.2 mg/dL, ALT 239 U/L, Alk P 314 U/L], with resolution over next 2-3 months: Case 1).*
- Rostom A, Goldkind L, Laine L. Nonsteroidal anti-inflammatory drugs and hepatic toxicity: a systematic review of randomized controlled trials in arthritis patients. *Clin Gastroenterol Hepatol*. 2005;3:489–98. PubMed PMID: 15880319.
- (Systematic review of trials reporting side effects from different NSAIDs: found rate of ALT elevations >3 fold elevated to be 1.8% among 7349 rofecoxib treated persons, higher than placebo recipients [0.29%] and all other NSAIDs [0.04-0.43%] except diclofenac [3.6%]; liver related serious adverse events occurred in 0.05%).*
- Ouar S, Bellaïche G, Belloc J, Tordjman G, Ley G, Slama JL. *Gastroenterol Clin Biol*. 2005;29:471–2. [Severe acute cholestatic and cytolytic hepatitis induced by rofecoxib]. French. PubMed PMID: 15918218.
- (69 year old woman developed fatigue 3 days after starting rofecoxib and stopped it promptly, but developed jaundice 1 month later [bilirubin 18.1 mg/dL, ALT 42 times ULN, Alk P 4 times ULN], with severe course and slow recovery over 6 months).*
- Haider M, Gain E, Khadem G, Pilmore H, Yun K, Jayasinghe N, Walker R. Simultaneous presentation of rofecoxib-induced acute hepatitis and acute interstitial nephritis. *Intern Med J*. 2005;35:370–2. PubMed PMID: 15892770.
- (62 year old man developed jaundice and itching 5 months after starting rofecoxib [bilirubin 14.0 rising to 29.8 mg/dL, AST 21 U/L, Alk P 218 U/L], with acute interstitial nephritis, ultimately resolving over next 3 months).*
- Yan B, Leung Y, Urbanski SJ, Myers RP. Rofecoxib-induced hepatotoxicity: a forgotten complication of the coxibs. *Can J Gastroenterol*. 2006;20:351–5. PubMed PMID: 16691302.
- (Two cases: 44 year old man developed jaundice 2 weeks after restarting rofecoxib [bilirubin 14.1 mg/dL, ALT 1826 U/L, Alk P 741 U/L], resolving in 2 months; 44 year old woman developed jaundice and itching 6 weeks after starting rofecoxib [bilirubin 12.1 mg/dL, ALT 995 U/L, Alk P 243 U/L], resolving in 1-2 months).*
- Sanchez-Matienzo D, Arana A, Castellsague J, Perez-Gutthann S. Hepatic disorders in patients treated with COX-2 selective inhibitors or nonselective NSAIDs: a case/noncase analysis of spontaneous reports. *Clin Ther*. 2006;28:1123–32. PubMed PMID: 16982289.
- (Industry review of FDA AERS reports of adverse events attributed to NSAIDs: 158,539 reports received, 3% were liver related; highest proportion liver adverse events were reported for sulindac, diclofenac and nimesulide; not for other Cox-2 inhibitors including rofecoxib).*
- Lapeyre-Mestre M, de Castro AM, Bareille MP, Del Pozo JG, Requejo AA, Arias LM, Montastruc JL, et al. Non-steroidal anti-inflammatory drug-related hepatic damage in France and Spain: analysis from national spontaneous reporting systems. *Fundam Clin Pharmacol*. 2006;20:391–5. PubMed PMID: 16867024.
- (Compared rates of spontaneous reporting of adverse effects of NSAIDs in Spain and France, found high rate of liver reports [compared to all types] for sulindac [14%] and nimesulide [17%], low for celecoxib [2% of 275 reports] and rofecoxib [0.6% of 499 reports]: 3 cases of liver injury attributed to rofecoxib from Spain and 6 from France 1982-2001).*
- Chalasanani N, Fontana RJ, Bonkovsky HL, Watkins PB, Davern T, Serrano J, Yang H, Rochon J; Drug Induced Liver Injury Network (DILIN). Causes, clinical features, and outcomes from a prospective study of drug-induced liver injury in the United States. *Gastroenterology*. 2008;135:1924–34. PubMed PMID: 18955056.
- (Among 300 cases of drug induced liver disease in the US collected from 2004 to 2008, NSAIDs were implicated as a sole agent in 8 cases and as one of several agents in 3 cases, but none were attributed to rofecoxib).*

Reuben A, Koch DG, Lee WM; Acute Liver Failure Study Group. Drug-induced acute liver failure: results of a U.S. multicenter, prospective study. *Hepatology*. 2010;52:2065–76. PubMed PMID: 20949552.

(Among 1198 patients with acute liver failure enrolled in a US prospective study between 1998 and 2007, 133 were attributed to drug induced liver injury, but none were attributed to rofecoxib).

Hernández N, Bessone F, Sánchez A, di Pace M, Brahm J, Zapata R, A, Chirino R, et al. Profile of idiosyncratic drug induced liver injury in Latin America. An analysis of published reports. *Ann Hepatol*. 2014;13:231–9. PubMed PMID: 24552865.

(Systematic review of literature of drug induced liver injury in Latin American countries published from 1996 to 2012 identified 176 cases, 62 of which were attributed to NSAIDs but mostly to nimesulide and a few to piroxicam, diclofenac and naproxen, but none to rofecoxib).

Chalasanani N, Bonkovsky HL, Fontana R, Lee W, Stolz A, Talwalkar J, Reddy KR, et al; United States Drug Induced Liver Injury Network. Features and outcomes of 899 patients with drug-induced liver injury: The DILIN Prospective Study. *Gastroenterology*. 2015;148:1340–52.e7. PubMed PMID: 25754159.

(Among 899 cases of drug induced liver injury enrolled in a US prospective study between 2004 and 2013, NSAIDs accounted for 28 cases (3%), none of which were attributed to rofecoxib).

Schmeltzer PA, Kosinski AS, Kleiner DE, Hoofnagle JH, Stolz A, Fontana RJ, Russo MW; Drug-Induced Liver Injury Network (DILIN). Liver injury from nonsteroidal anti-inflammatory drugs in the United States. *Liver Int*. 2016;36:603–9. PubMed PMID: 26601797.

(Among 1221 cases of drug induced liver injury enrolled in a prospective US registry, 30 were attributed to NSAIDs, 30 [2.5%] of which were due to NSAIDs but none were due to rofecoxib).

Bessone F, Hernandez N, Roma MG, Ridruejo E, Mendizabal M, Medina-Cáliz I, Robles-Díaz M, et al. Hepatotoxicity induced by coxibs: how concerned should we be? *Expert Opin Drug Saf*. 2016;15:1463–75. PubMed PMID: 27537326.

(Review of the literature and description of clinical features of Cox-2 specific NSAIDs and liver injury mentions 8 cases of rofecoxib related injury, generally presenting as cholestatic hepatitis and resolving within 6 months of onset).

Meunier L, Larrey D. Recent advances in hepatotoxicity of non-steroidal anti-inflammatory drugs. *Ann Hepatol*. 2018;17:187–91. PubMed PMID: 29469052.

(Review of the hepatotoxicity of NSAIDs mentions the most commonly implicated are diclofenac, nimesulide, sulindac, ibuprofen, piroxicam, naproxen and aspirin).