



Trazodone

Updated: February 26, 2020.

OVERVIEW

Introduction

Trazodone is a serotonergic modulating antidepressant that is used in therapy of depression, aggressive behavior and panic disorder. Trazodone therapy can be associated with transient, usually asymptomatic elevations in serum aminotransferase levels and has been linked to rare instances of clinically apparent acute liver injury.

Background

Trazodone (traz' oh done) is a triazolopyridine derivative whose mechanism of action is believed to be inhibition of serotonin reuptake and modulation of serotonin receptor activity, which results in increased levels and activity of serotonin. Trazodone was approved for use in major depressive disorder in the United States in 1981 and remains in wide use, with more than 22 million prescriptions being filled yearly. Trazodone is also used off-label for control of aggressive behavior, panic disorder, anxiety, insomnia, substance abuse, bulimia, schizophrenia and dementia. Trazodone has anxiolytic activity and normalizes sleep patterns, effects that have made trazodone one of the most frequently prescribed drugs for insomnia. Trazodone is available in tablets of 50, 75, 100, 150 and 300 mg in several generic forms and formerly under the brand name Desyrel. The recommended dosage for depression in adults is 150 mg in divided doses that can be increased in 50 mg amounts to a maximum of 600 mg daily. An extended release formulation is also available in 150 mg tablets (Olepto) which is given once daily. It is typically given in single, bedtime lower doses for insomnia. Common side effects of trazodone are drowsiness, fatigue, dizziness, headache, dry mouth, blurred vision, nausea, decreased libido, increased appetite and weight gain. Uncommon but potentially severe adverse events include suicidal thoughts and behaviors, activation of mania, serotonin syndrome, cardiac arrhythmias, orthostatic hypotension, priapism and angle-closure glaucoma.

Hepatotoxicity

Liver test abnormalities occur in a proportion of patients on trazodone, but elevations are usually modest and usually do not require dose modification or discontinuation. At least a dozen instances of acute, clinically apparent episodes of liver injury with marked liver enzyme elevations with or without jaundice have been reported in patients on trazodone. The onset of injury varies from a few days to 6 months and the pattern of serum enzyme elevations is usually hepatocellular, but mixed and cholestatic forms have also been described. Several cases have had immunoallergic features (rash, fever, eosinophilia), but these were not prominent. Autoimmune (autoantibodies) features are uncommon. Rare instances of acute liver failure and death from trazodone have been reported. Nefazodone, an antidepressant similar in structure and mechanism of action to

trazodone, was approved for use in 1998, but is currently not commonly used because of multiple reports of acute hepatocellular injury, with a high mortality rate arising 2 weeks to 6 months after starting therapy.

Likelihood score: B (likely but rare cause of clinically apparent liver injury).

Mechanism of Injury

The mechanism by which trazodone causes liver injury is not known. Trazodone is extensively metabolized by the liver, mainly via the cytochrome P450 system (CYP3A4), and hepatotoxicity may be mediated by toxic intermediates of its metabolism. Trazodone is susceptible to multiple drug-drug interactions.

Outcome and Management

The serum aminotransferase elevations that occur on trazodone therapy are usually self-limited and do not require dose modification or discontinuation of therapy. Rare instances of acute liver failure and chronic hepatitis have been attributed to trazodone therapy. Persons with intolerance to trazodone may have similar reactions to other antidepressants, and careful monitoring is warranted if other such agents are used.

Drug Class: [Antidepressant Agents](#)

Other Drugs in the Subclass: [Nefazodone](#)

CASE REPORT

Case 1. Acute hepatitis due to trazodone.(1)

A 38 year old woman with rheumatoid arthritis developed itching followed by jaundice approximately 18 months after starting trazodone. She was also receiving prednisone (10 mg daily), methotrexate, hydroxychloroquine, nabumetone, propoxyphene, folate, birth control pills and alendronate, but had been on this regimen for many years. She had no history of liver disease or known risk behaviors for acquiring hepatitis and did not drink alcohol. On examination, she was jaundiced but had no rash, fever or signs of chronic liver disease. Laboratory results showed a bilirubin of 11.0 mg/dL with marked elevations in serum aminotransferase levels (Table). Her liver tests had been normal on routine testing several months previously. Tests for hepatitis A, B and C were negative as were autoantibodies. An abdominal ultrasound showed no evidence of biliary obstruction. A liver biopsy showed intrahepatic cholestasis, modest inflammation, and ballooning degeneration but no fat or fibrosis. Trazodone was stopped, and she began to improve rapidly. She was discharged from the hospital, but one week later restarted trazodone. After two days she had a return of her symptoms and jaundice. Within two weeks of stopping trazodone for the second time, she had no symptoms of liver disease and her liver tests were near-normal.

Key Points

Medication:	Trazodone
Pattern:	Hepatocellular (R=5.8)
Severity:	3+ (jaundice, hospitalization)
Latency:	Initially 18 months, with rechallenge 3 days
Recovery:	Within 1 month
Other medications:	Prednisone, methotrexate, hydroxychloroquine, nabumetone, propoxyphene, folate, birth control pills, alendrolate.

Laboratory Values

Time After Starting	Time After Stopping	ALT (U/L)	Alk P (U/L)	Bilirubin (mg/dL)	Other
12 months		13	64	0.8	Routine testing
Onset of pruritus and jaundice 18 months after starting trazodone					
18 months	0	1092	206	11.0	
	3 days	786	191	8.7	
Discharged from hospital and restarted trazodone shortly thereafter					
	10 (0) days	1476	259	10.3	
	15 (5) days	466	202	3.3	
	19 (9) days	146	154	2.4	
	23 (13) days	55	108	1.6	
	30 (20) days	43	93	1.4	
	51 (41) days	17	71	0.9	
Normal Values		<48	<125	<1.2	

* Numbers in parentheses indicate the days after stopping the second time.

Comment

Trazodone has been linked to rare cases of hepatic injury. The onset of injury is generally after several months and is typically hepatocellular, although cases with a shorter latency and with a cholestatic pattern of serum enzyme elevations have been described. In this case, the long latency period was atypical of trazodone and not characteristic of drug induced liver disease in general. Furthermore, the patient was taking other potentially hepatotoxic drugs (methotrexate, nabumetone). What makes the likelihood of trazodone being the cause of the injury was the inadvertent rechallenge that led to a rapid worsening of the injury. Furthermore, the liver biopsy showed no evidence of methotrexate injury and had changes that were considered typical of drug induced liver injury. The hepatic injury rapidly resolved with stopping therapy.

PRODUCT INFORMATION

REPRESENTATIVE TRADE NAMES

Trazodone – Generic, Desyrel®

DRUG CLASS

Antidepressant Agents

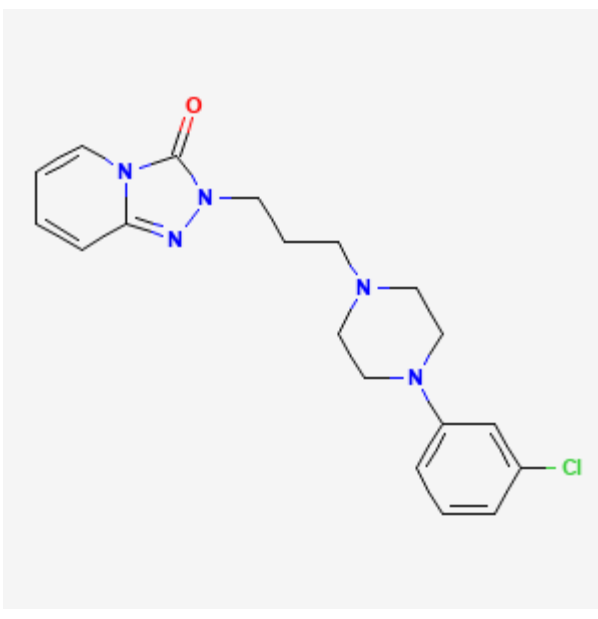
COMPLETE LABELING

Product labeling at DailyMed, National Library of Medicine, NIH

CHEMICAL FORMULA AND STRUCTURE

DRUG	CAS REGISTRY NUMBER	MOLECULAR FORMULA	STRUCTURE
------	---------------------	-------------------	-----------

Table continued from previous page.

Trazodone	19794-93-5	C19-H22-Cl-N5-O	
-----------	------------	-----------------	--

CITED REFERENCES

1. Fernandes NF, Martin RR, Schenker S. Trazodone-induced hepatotoxicity: a case report with comments on drug-induced hepatotoxicity. *Am J Gastroenterol.* 2000;95:532–5. PubMed PMID: 10685763.

ANNOTATED BIBLIOGRAPHY

References updated: 26 February 2020

Zimmerman HJ. Antidepressants. In, Zimmerman HJ. *Hepatotoxicity: the adverse effects of drugs and other chemicals on the liver.* 2nd ed. Philadelphia: Lippincott, 1999, pp. 493-8.

(Expert review of hepatotoxicity published in 1999; trazodone is listed as potentially causing either cholestatic or hepatocellular injury having been implicated in at least 6 cases, including instances of chronic hepatitis).

Larrey D, Ripault MP. Hepatotoxicity of psychotropic drugs and drugs of abuse. In, Kaplowitz N, DeLeve LD, eds. *Drug-induced liver disease.* 3rd ed. Amsterdam: Elsevier, 2013, pp. 443-62.

(Review of hepatotoxicity of antidepressants mentions that trazodone can cause immunoallergic liver injury with a latency of a few days to 1.5 year and with variable patterns of enzyme elevations).

O'Donnell JM, Bies RR, Shelton RC. Drug therapy of depression and anxiety disorders. In, Brunton LL, Hilal-Dandan R, Knollman BC, eds. *Goodman & Gilman's the pharmacological basis of therapeutics.* 13th ed. New York: McGraw-Hill, 2018, pp. 267-78.

(Textbook of pharmacology and therapeutics).

Chu AG, Gunsolly BL, Summers RW, Alexander B, McChesney C, Tanna VL. Trazodone and liver toxicity. *Ann Intern Med.* 1983;99:128–9.

(63 year old man developed rash and asymptomatic liver test abnormalities 4 weeks after starting trazodone [bilirubin normal, ALT 55 rising to 211 U/L, Alk P 139 to 535 U/L], serum enzymes worsening for a week after stopping therapy before rapidly falling to normal).

Sheikh KH, Nies AS. Trazodone and intrahepatic cholestasis. *Ann Intern Med.* 1983;99:274–5.

- (71 year old woman developed jaundice 2 weeks after starting trazodone [bilirubin 12 mg/dL, AST 780 U/L, Alk P 1310 U/L], bilirubin peaking 2 weeks later [29 mg/dL], but injury ultimately resolved within 8 weeks of stopping).
- Longstreth GF, Hershman J. Trazodone-induced hepatotoxicity and leukonychia. *J Am Acad Dermatol.* 1985;13:149–50. PubMed PMID: 4031146.
- (57 year old woman developed jaundice 6 months after starting trazodone [bilirubin 14.8 mg/dL, AST 277 U/L, Alk P 161 U/L, protime 29 sec], resolving within 5 weeks of stopping, but minor AST and Alk P elevations persisted for 6 months).
- Rongioletti F, Rebora A. Drug eruption from trazodone. *J Am Acad Dermatol.* 1986;14:274–5.
- (71 year old woman developed fever and rash several months after starting trazodone [bilirubin normal, ALT 81 U/L, Alk P 177 U/L, eosinophils 7%, ANA negative], resolving within 2 weeks of stopping).
- Beck PL, Bridges RJ, Demetrick DJ, Kelly JK, Lee SS. Chronic active hepatitis associated with trazodone therapy. *Ann Intern Med.* 1993;118:791–2. PubMed PMID: 8470853.
- (75 year old woman developed jaundice 7 months after starting trazodone [bilirubin 17.9 mg/dL, ALT 933 U/L, Alk P 144 U/L], biopsy showing chronic hepatitis, rapid clinical improvement, but bilirubin was raised for 6 months after stopping).
- Hull M, Jones R, Bendall M. Fatal hepatic necrosis associated with trazodone and neuroleptic drugs. *BMJ.* 1994;309:378.
- (72 year old woman developed ALT elevations [107 U/L] 10 weeks after starting trazodone, trifluoperazine and lithium, developing jaundice at 18 weeks and dying 2 months later).
- Robinson DS, Roberts DL, Smith JM, Stringfellow JC, Kaplita SB, Seminara JA, Marcus RN. The safety profile of nefazodone. *J Clin Psychiatry.* 1996;97 Suppl 2:31–8.
- (Pooled analysis of 3500 patients on nefazodone in clinical trials; most common side effects were nausea, somnolence, dry mouth, dizziness, constipation and asthenia; 12% stopped drug for side effects vs 7.5% on placebo, 10.5% fluoxetine and 22% imipramine; no excess weight gain or abnormal laboratory tests vs placebo; no deaths or severe side effects due to liver injury and no mention of ALT elevations).
- Lucena MI, Andrade RJ, Gomez-Outes A, Rubio M, Cabello MR. Acute liver failure after treatment with nefazodone. *Dig Dis Sci.* 1999;44:2577–9. PubMed PMID: 10630516.
- (73 year old woman developed abdominal pain 7 weeks after starting nefazodone [bilirubin 17.1 mg/dL, ALT 834 U/L, Alk P 115 U/L, protime 15 sec], with progressive liver failure and death 4 weeks after presentation).
- Aranda-Michel J, Koehler A, Bejarano PA, Poulos JE, Luxon BA, Khan CM, Ee LC, et al. Nefazodone-induced liver failure: report of three cases. *Ann Intern Med.* 1999;130:285–8. PubMed PMID: 10068386.
- (Three women, ages 54, 16 and 57 years, developed jaundice 8, 3 and 6 months after starting nefazodone [bilirubin 34.0, 22.5 and 11.8 mg/dL, ALT 2040, 1345 and 1625 U/L, Alk P 97, 206 and 273 U/L], biopsies showing massive and centrilobular necrosis; 1 died, 1 recovered and 1 was transplanted).
- van Battum PL, van de Vrie W, Metselaar HJ, Verstappen VM, Zondervan PE, de Man RA. *Ned Tijdschr Geneesk.* 2000;144:1964–7. [Acute liver failure ascribed to nefazodone: importance of 'postmarketing surveillance' for recently introduced drugs]. PubMed PMID: 11048561.
- Schirren CA, Baretton G. Nefazodone-induced acute liver failure. *Am J Gastroenterol.* 2000;95:1596–7.
- (52 year old man developed jaundice 5-6 weeks after starting nefazodone with ascites and liver failure requiring liver transplantation 6 weeks after presentation; explant showed massive hepatic necrosis).

- Eloubeidi MA, Gaede JT, Swaim MW. Reversible nefazodone-induced liver failure. *Dig Dis Sci.* 2000;45:1036–8. PubMed PMID: 10795773.
- (46 year old woman developed fatigue followed by jaundice ~4 months after starting nefazodone [bilirubin 14.5 mg/dL, ALT 456 U/L, Alk P 158 U/L], resolving within 4 months of stopping).*
- Fernandes NF, Martin RR, Schenker S. Trazodone-induced hepatotoxicity: a case report with comments on drug-induced hepatotoxicity. *Am J Gastroenterol.* 2000;95:532–5. PubMed PMID: 10685763.
- (39 year old woman developed jaundice 18 months after starting trazodone [bilirubin 11.0 mg/dL, ALT 1092 U/L and Alk P 206 U/L], improving rapidly upon stopping, but recurring with inadvertent rechallenge: Case 1).*
- Rettman KS, McClintock C. Hepatotoxicity after short-term trazodone therapy. *Ann Pharmacother.* 2001;35:1559–61. PubMed PMID: 11793619.
- (46 year old man with HIV-HCV co-infection had onset of symptoms of hepatitis within 5 days of entering cocaine detoxification program and starting trazodone [bilirubin 2.1 mg/dL, ALT 2581 U/L, Alk P 342 U/L], resolving rapidly upon stopping).*
- Ehrentraut S, Rothenhäusler HB, Gerbes AL, Rau HG, Thiel M, Schirren CA, Kapfhammer HP. *Nervenarzt.* 2002;73:686–9. [Acute liver failure in nefazodone therapy? A case report]. PubMed PMID: 12212533.
- (52 year old man developed acute liver failure 6 weeks after starting nefazodone [bilirubin 13.9 mg/dL, ALT 1947 U/L, GGT 88 U/L], progressing to hepatic failure requiring liver transplantation, dying of subsequent complications).*
- Stewart DE. Hepatic adverse reactions associated with nefazodone. *Can J Psychiatry.* 2002;47:375–7. PubMed PMID: 12025437.
- (Analysis of Canadian Adverse Drug Reaction database found 32 cases of liver injury associated with nefazodone with onset after 1 week to 2 year, mostly within 6 months, 3 with hepatic failure).*
- Carvajal García-Pando A, García del Pozo J, Sánchez AS, Velasco MA, Rueda de Castro AM, Lucena MI. Hepatotoxicity associated with the new antidepressants. *J Clin Psychiatry.* 2002;63:135–7. PubMed PMID: 11874214.
- (Analysis of cases of hepatotoxicity from antidepressants in Spanish Pharmacovigilance System from 1989-1999, identified 99 cases; among SSRIs, 26 due to fluoxetine, 14 paroxetine, 6 fluvoxamine, 5 sertraline, 3 venlafaxine and 2 citalopram; among tricyclics, 16 clomipramine 7 amitriptyline, 6 imipramine; among miscellaneous, 3 nefazodone and 1 trazodone; but all similar in rate ~1-3 per 100,000 patient-years of exposure, except for nefazodone=29/100,000).*
- Lucena M, Carvajal A, Andrade R, Velasco A. Antidepressant-induced hepatotoxicity. *Expert Opin Drug Saf.* 2003;2:249–62. PubMed PMID: 12904104.
- (Review of hepatotoxicity of antidepressants; antidepressant use has increased markedly between 1992 and 2002, accounting for 5% of cases of hepatotoxicity; SSRIs are less likely to cause injury than tricyclics and MAO inhibitors; range of presentations, typically self-limited and rapid recovery; no hallmarks of hypersensitivity).*
- Choi S. Nefazodone (Serzone) withdrawn because of hepatotoxicity. *CMAJ.* 2003;169:1187. PubMed PMID: 14638657.
- (Editorial announcing withdrawal of nefazodone in Canada; 51 Canadian reports of adverse hepatic events, 2 requiring transplant).*
- Tzimas GN, Dion B, Deschênes M. Early onset, nefazodone-induced fulminant hepatic failure. *Am J Gastroenterol.* 2003;98:1663–4. PubMed PMID: 12873607.

(Two cases of acute liver failure in 61 and 46 year olds, with onset of jaundice 3 and 4 weeks after starting nefazodone with liver failure and encephalopathy, one requiring liver transplant and one with spontaneous survival).

Spigset O, Hägg S, Bate A. Hepatic injury and pancreatitis during treatment with serotonin reuptake inhibitors: data from the World Health Organization (WHO) database of adverse drug reactions. *Int Clin Psychopharmacol.* 2003;18:157–61. PubMed PMID: 12702895.

(Among 27,542 reports of hepatic injury in WHO database, 786 were related to SSRIs [3%], including citalopram 42, fluoxetine 222, fluvoxamine 54, paroxetine 191, sertraline 112, nefazodone 91 and venlafaxine 74, only nefazodone has an excess of hepatic reports in relationship to total reports).

Sánchez Ruiz JC, González López E, Aparicio Tijeras C, Ezquerro Gadea J. *Aten Primaria.* 2004;34:104. [Hepatotoxicity due to trazodone].

(60 year old was found to have abnormal liver tests without symptoms 6 months after starting trazodone [bilirubin 1.3 mg/dL, ALT 218 U/L, GGT 96 U/L], abnormalities resolving rapidly upon stopping).

Conway CR, McGuire JM, Baram VY. Nefazodone-induced liver failure. *J Clin Psychopharmacol.* 2004;24:353–4. PubMed PMID: 15118496.

(51 year old man developed jaundice and confusion 7 months after starting nefazodone and 1 week after a dose increase [bilirubin 1.7 mg/dL, ALT 1964 U/L, Alk P 96 U/L], resolving rapidly upon stopping).

Degner D, Grohmann R, Kropp S, Rütger E, Bender S, Engel RR, Schmidt LG. Severe adverse drug reactions of antidepressants: results of the German multicenter drug surveillance program AMSP. *Pharmacopsychiatry.* 2004;37 Suppl 1:S39–45. PubMed PMID: 15052513.

(Analysis of adverse drug reactions reported from 1993–2000 in 35 psychiatric hospitals; 0.7% of SSRI recipients had a severe adverse event; hepatic in 0.05%).

Andrade RJ, Lucena MI, Fernández MC, Pelaez G, Pachkoria K, García-Ruiz E, García-Muñoz B, et al; Spanish Group for the Study of Drug-Induced Liver Disease. Drug-induced liver injury: an analysis of 461 incidences submitted to the Spanish registry over a 10-year period. *Gastroenterology.* 2005;129:512–21. PubMed PMID: 16083708.

(Reports to a Spanish network found 461 cases of drug induced liver disease, antidepressants accounting for 23 cases [5%]).

Björnsson E, Olsson R. Suspected drug-induced liver fatalities reported to the WHO database. *Dig Liver Dis.* 2006;38:33–8. PubMed PMID: 16054882.

(Survey of drug induced liver fatalities reported to WHO database between 1968–2003 revealed 4690 reports; no antidepressant ranked among the top 21 agents that were linked to at least 50 cases each).

Kostrubsky SE, Strom SC, Kalgutkar AS, Kulkarni S, Atherton J, Mireles R, Feng B, et al. Inhibition of hepatobiliary transport as a predictive method for clinical hepatotoxicity of nefazodone. *Toxicol Sci.* 2006;90:451–9. PubMed PMID: 16410371.

(Nefazodone, unlike trazodone, is a potent inhibitor of the bile salt export protein [BSEP] in cell culture).

Sabaté M, Ibáñez L, Pérez E, Vidal X, Buti M, Xiol X, Mas A, et al. Risk of acute liver injury associated with the use of drugs: a multicentre population survey. *Aliment Pharmacol Ther.* 2007;25:1401–9. PubMed PMID: 17539979.

(Among 126 cases of drug induced liver injury seen in Spain between 1993–2000, 3 were attributed to paroxetine and 3 to fluoxetine, with a relative risk of injury to rate of use in the population of 3.0 and 1.8, respectively).

DeSanty KP, Amabile CM. Antidepressant-induced liver injury. *Ann Pharmacother.* 2007;41:1201–11. PubMed PMID: 17609231.

(Review of drug induced liver injury and reports of injury from MAO inhibitors, SSRIs, tricyclics and atypical agents).

Chalasan N, Fontana RJ, Bonkovsky HL, Watkins PB, Davern T, Serrano J, Yang H, Rochon J; Drug Induced Liver Injury Network (DILIN). Causes, clinical features, and outcomes from a prospective study of drug-induced liver injury in the United States. *Gastroenterology.* 2008;135:1924–34. PubMed PMID: 18955056.

(Among 300 cases of drug induced liver disease in the US collected from 2004 to 2008, antidepressants accounted for 12 cases [4%]: duloxetine [6], bupropion [2], fluoxetine [2], amitriptyline [1], sertraline [1]; no mention of trazodone).

Detry O, Delwaide J, De Roover A, Hans MF, Delbouille MH, Monard J, Honore P. Fulminant hepatic failure induced by venlafaxine and trazodone therapy: a case report. *Transplant Proc.* 2009;41:3435–6. PubMed PMID: 19857765.

(48 year old woman developed jaundice and liver failure, and underwent liver transplantation, following combined therapy of venlafaxine and trazodone for 4 months).

Reuben A, Koch DG, Lee WM; Acute Liver Failure Study Group. Drug-induced acute liver failure: results of a U.S. multicenter, prospective study. *Hepatology.* 2010;52:2065–76. PubMed PMID: 20949552.

(Among 1198 patients with acute liver failure enrolled in a US prospective study between 1998 and 2007, 133 were attributed to drug induced liver injury, 3 of which were linked to antidepressants: one each for nefazodone, fluoxetine and venlafaxine).

Sedky K, Nazir R, Joshi A, Kaur G, Lippmann S. Which psychotropic medications induce hepatotoxicity? *Gen Hosp Psychiatry.* 2012;34:53–61. PubMed PMID: 22133982.

(Review of the hepatotoxicity of psychotropic drugs in common use, mentions that nefazodone has a “black box” warning and that liver failure occurs at a rate of 1:250,000-300,000 patient-years of exposure; no mention of trazodone).

Park SH, Ishino R. Liver injury associated with antidepressants. *Curr Drug Saf.* 2013;8:207–23. PubMed PMID: 23914755.

(Review of drug induced liver injury due to antidepressants including trazodone and nefazodone).

Björnsson ES, Bergmann OM, Björnsson HK, Kvaran RB, Olafsson S. Incidence, presentation and outcomes in patients with drug-induced liver injury in the general population of Iceland. *Gastroenterology.* 2013;144:1419–25. PubMed PMID: 23419359.

(In a population based study of drug induced liver injury from Iceland, 96 cases were identified over a 2 year period, none of which were attributed to trazodone).

Montastruc F, Scotto S, Vaz IR, Guerra LN, Escudero A, Sáinz M, Falomir T, et al. Hepatotoxicity related to agomelatine and other new antidepressants: a case/noncase approach with information from the Portuguese, French, Spanish, and Italian pharmacovigilance systems. *J Clin Psychopharmacol.* 2014;34:327–30. PubMed PMID: 24561328.

(Among adverse event reports attributed to antidepressants submitted to 4 European pharmacovigilance databases, 3300 [10%] were for hepatotoxicity, rates being highest for agomelatine [14.6%], but was not above average for trazodone, 1.0% to 4.9%).

Voican CS, Corruble E, Naveau S, Perlemuter G. Antidepressant-induced liver injury: a review for clinicians. *Am J Psychiatry.* 2014;171:404–15. PubMed PMID: 24362450.

(Review of the hepatotoxicity of antidepressants mentions that aminotransferase elevations arise in 0.5-3.0% of patients, being highest with MAO inhibitors and lower with SSRIs; all antidepressants have the potential to cause liver injury but is highest with nefazodone, imipramine, amitriptyline, duloxetine, bupropion, trazodone, and agomelatine).

Hernández N, Bessone F, Sánchez A, di Pace M, Brahm J, Zapata R, A, Chirino R, et al. Profile of idiosyncratic drug induced liver injury in Latin America: an analysis of published reports. *Ann Hepatol.* 2014;13:231–9. PubMed PMID: 24552865.

(Among 176 reports of drug induced liver injury from Latin America published between 1996 and 2012, only one was due to an antidepressant [amitriptyline] and none to trazodone).

Chalasanani N, Bonkovsky HL, Fontana R, Lee W, Stolz A, Talwalkar J, Reddy KR, et al; United States Drug Induced Liver Injury Network. Features and outcomes of 899 patients with drug-induced liver injury: The DILIN Prospective Study. *Gastroenterology.* 2015;148:1340–52.e7. PubMed PMID: 25754159.

(Among 899 cases of drug induced liver injury enrolled in a US prospective study between 2004 and 2013, 20 [15%] were attributed to antidepressants, most frequently to duloxetine [n=7], bupropion [n=4], escitalopram [n=3], and 1 each for imipramine, fluoxetine, nefazodone and trazodone).

Gahr M, Zeiss R, Lang D, Connemann BJ, Hiemke C, Schönfeldt-Lecuona C. Drug-Induced Liver Injury Associated with antidepressive psychopharmacotherapy: an explorative assessment based on quantitative signal detection using different MedDRA terms. *J Clin Pharmacol.* 2016;56:769–78. PubMed PMID: 26470856.

(Using data on adverse drug reaction reports from the Uppsala Monitoring Center of WHO, there were higher relative hepatotoxicity reports for nefazodone, agomelatine, many tricyclics and mirtazapine).

Friedrich ME, Akimova E, Huf W, Konstantinidis A, Papageorgiou K, Winkler D, Toto S, et al. Drug-induced liver injury during antidepressant treatment: results of AMSP, a drug surveillance program. *Int J Neuropsychopharmacol.* 2016;19:pyv126. pii. PubMed PMID: 26721950.

(Among 184,234 psychiatric inpatients from 80 hospitals, 149 cases [0.08%] of drug induced liver injury were reported but only one of them was attributed to trazodone).

Chen VC, Lin CF, Hsieh YH, Liang HY, Huang KY, Chiu WC, Lee Y, McIntyre RS, et al. Hepatocellular carcinoma and antidepressants: a nationwide population-based study. *Oncotarget.* 2017;8:30464–70. PubMed PMID: 27783998.

(Among almost 50,000 cases of hepatocellular carcinoma registered in the Taiwan National Health Insurance Research Database, the rate of antidepressant use was lower than in approximately 250,000 matched controls from the database).

Bunchorntavakul C, Reddy KR. Drug hepatotoxicity: newer agents. *Clin Liver Dis.* 2017;21:115–34. PubMed PMID: 27842767.

(Review of hepatotoxicity of recently approved medications mentions that liver injury in recently approved agents and only rare instances have been linked to antidepressant use, highest rates associated with duloxetine).

Carvalho S, Oliveira A, Ferreira P, Resende M, Perdigoto R, Barroso E. Acute liver failure due to trazodone and diazepam. *GE Port J Gastroenterol.* 2017;24:40–2. PubMed PMID: 28848778.

(63 year old man developed acute liver failure 3 months after starting trazodone and diazepam [bilirubin 12.0 mg/dL, ALT 4638 U/L, Alk P 122 U/L, INR 1.84], with worsening liver failure and transplant two weeks later).

Ferrajolo C, Scavone C, Donati M, Bortolami O, Stoppa G, Motola D, Vannacci A, et al; DILI-IT Study Group. Antidepressant-induced acute liver injury: a case-control study in an Italian inpatient population. *Drug Saf.* 2018;41:95–102. PubMed PMID: 28770534.

- (Among 179 cases of hospitalizations for unexplained acute liver injury enrolled in an Italian prospective study between 2010 and 2014, 17 had been exposed to antidepressants including citalopram [n=4], sertraline [n=3], amitriptyline [n=3] and paroxetine [n=2], and trazodone [n=1], and another was exposed to both trazodone and mirtazapine).*
- Billioti de Gage S, Collin C, Le-Tri T, Pariente A, Bégaud B, Verdoux H, Dray-Spira R, et al. Antidepressants and hepatotoxicity: a cohort study among 5 million individuals registered in the French National Health Insurance Database. *CNS Drugs*. 2018;32:673–84. PubMed PMID: 29959758.
- (Using the French National Health Insurance Database, 382 serious liver injuries were found in approximately 5 million persons initiating antidepressant therapy, rates being 32.8 per 100,000 with mirtazapine, 22.2 with venlafaxine, 19.2 for SSRIs and 12.6 with duloxetine; trazodone is not specifically discussed).*
- Drugs for anxiety disorders. *Med Lett Drugs Ther*. 2019;61(1578):121–6. PubMed PMID: 31386647.
- (Concise review of drugs for anxiety including SSRIs, SNRIs and benzodiazepines including mechanism of action, clinical efficacy, safety and costs; does not mention ALT elevations or hepatotoxicity).*
- Pladevall-Vila M, Pottegård A, Schink T, Reutfors J, Morros R, Poblador-Plou B, Timmer A, et al. Risk of acute liver injury in agomelatine and other antidepressant users in four European countries: a cohort and nested case-control study using automated health data sources. *CNS Drugs*. 2019;33:383–95. PubMed PMID: 30830574.
- (Analysis of data sources from 4 European countries identified 3.2 million persons initiating antidepressant therapy among whom there was no increased risk for acute liver injury for agomelatine compared to citalopram, an SSRI with a low rate of hepatotoxicity).*
- Schwasinger-Schmidt TE, Macaluso M. Other antidepressants. *Handb Exp Pharmacol*. 2019;250:325–55. PubMed PMID: 30194544.
- (Review of the pharmacology of antidepressants mentions that the common side effects of trazodone are drowsiness, dizziness and dry mouth but does not mention hepatotoxicity or ALT elevations).*
- Drugs for depression. *Med Lett Drugs Ther*. 2020;62(1592):25–32.
- (Concise review of the mechanism of action, clinical efficacy, safety and costs of drugs for depression; hepatotoxicity is mentioned only for nefazodone [now rarely used because of severe hepatotoxicity] and duloxetine [in heavy drinkers]).*