



Chlorzoxazone

Updated: January 30, 2017.

OVERVIEW

Introduction

Chlorzoxazone is a centrally acting muscle relaxant commonly used for low back pain. Chlorzoxazone has been linked to rare instances of acute liver injury, a few of which have been fatal.

Background

Chlorzoxazone (klor zox' a zone) acts centrally rather than directly on muscles to relieve muscle spasms, either through its sedative effects or other unknown mechanisms. Chlorzoxazone is indicated for therapy of low back pain and muscle spasms, although its overall efficacy is considered only fair. Chlorzoxazone was approved for use in the United States in 1958 and is still widely used. It is available in various generic forms as well as under the brand names of Parafon Forte and Remular in tablets of 250 or 500 mg. The usual recommended dose in adults is 250 to 750 mg orally three to four times daily, reducing the dose to lowest effective level once a response occurs. Chlorzoxazone is typically given for 1 to 4 weeks only. Common side effects of chlorzoxazone include dizziness, drowsiness, headache, fatigue and tremor.

Hepatotoxicity

There have been no adequate prospective studies demonstrating the rates of ALT or AST elevations on chlorzoxazone therapy. Rare instances of clinical apparent liver disease possibly attributable to chlorzoxazone have appeared, including fatal cases. Such cases must be very rare, as this agent is widely used. While case reports have been few, in many instances chlorzoxazone was clearly implicated; furthermore, a related muscle relaxant with similar structure (zoxazolamine) was withdrawn from use in 1961, largely because of hepatotoxicity. The usual latency period is 1 to 4 weeks and the pattern of disease typically hepatocellular with marked elevations in ALT levels and jaundice, with minimal increases in alkaline phosphatase. Cholestatic enzyme elevations after exposure to chlorzoxazone have also been described. Allergic manifestations (rash and fever) are common, particularly in cases with a short latency (Case 1); autoantibodies are rare. Recovery is rapid once chlorzoxazone is stopped, but fatal cases have been reported, with disease progression despite early discontinuation of the agent (Case 2). There is rapid recurrence of injury with reexposure, often accompanied by fever.

Likelihood score: B (Highly likely cause of clinically apparent liver injury).

Mechanism of Injury

The cause of acute hepatic injury from chlorzoxazone is unknown, but is clearly idiosyncratic and likely due to hypersensitivity.

Outcome and Management

The idiosyncratic liver injury due to chlorzoxazone ranges from mild, self-limited hepatitis to severe, protracted liver injury leading to death or need for liver transplantation. Rechallenge leads to rapid return of hepatic injury and should be avoided. No cross reactivity with other muscle relaxants has been identified.

Drug Class: [Muscle Relaxants](#)

CASE REPORTS

Case 1. Skin rash and cholestatic pattern of serum enzyme elevations from chlorzoxazone.

[Modified from: Lindholm L. (Fever, skin and liver reactions in a patient treated with Paraflex comp.) [Lakartidningen 1979; 76: 2795-6. PubMed Citation](#)]

A 77 year old woman was treated with a combination of chlorzoxazone, dextropropoxyphene and aspirin ("Paraflex Compound") for acute neck pains and developed fever and rash four days later. The medications were continued and one week later she was still febrile and was found to have abnormal liver tests with marked elevations in alkaline phosphatase (6.5 fold elevated) and gamma glutamyl transpeptidase (8-fold increased), with minimal increases in ALT and AST and normal bilirubin. Chlorzoxazone was stopped. The rash was considered to be erythema multiforme. She had a past medical history of osteoporosis and had received aspirin and nonsteroid antiinflammatory agents in the past. She tested negative for hepatitis markers and for autoantibodies. The fever and rash resolved within 1 to 2 weeks of stopping the medication. In follow up, all laboratory tests returned to normal. She later received aspirin without untoward reaction.

Key Points

| | |
|--------------------|--------------------------------|
| Medication: | Chlorzoxazone (in combination) |
| Pattern: | Cholestatic (R=0.3) |
| Severity: | 1+ (enzyme elevations only) |
| Latency: | 1 week |
| Recovery: | Complete within several months |
| Other medications: | Aspirin, dextropropoxyphene |

Laboratory Values

| Time After Starting | Time After Stopping | ALT (U/L)* | Alk P (U/L)* | Bilirubin (mg/dL)* | Other |
|-------------------------------------|---------------------|------------|--------------|--------------------|----------------|
| Fever and rash arising after 4 days | | | | | |
| 11 days | 0 | 84 | 750 | 0.6 | Rash and fever |
| 2 weeks | 3 days | 60 | 600 | 0.4 | |
| 3 weeks | 8 | 24 | 500 | 0.5 | |
| | 11 | 12 | 350 | 0.4 | Asymptomatic |
| 5 weeks | 4 weeks | 12 | 167 | 0.5 | |

Table continued from previous page.

| Time After Starting | Time After Stopping | ALT (U/L)* | Alk P (U/L)* | Bilirubin (mg/dL)* | Other |
|----------------------|---------------------|---------------|----------------|--------------------|-------|
| 8 weeks | 7 weeks | 18 | 142 | 0.4 | |
| 10 weeks | 9 weeks | 12 | 122 | 0.6 | |
| Normal Values | | <42 | <115 | <1.2 | |

* Converted from $\mu\text{kat/L}$ ($0.7=42$) and $\mu\text{mol/L}$ ($17=1.0$).

Comment

This case was identified when the patient developed drug rash and fever. She was not jaundiced, but serum alkaline phosphatase levels were high typical of a cholestatic reaction (also confirmed by the elevations in GGT). Once the medication was stopped, she became asymptomatic within a few weeks, but alkaline phosphatase levels took longer to return to normal. Because she also received dextropropoxyphene, one cannot consider the case definitely due to chlorzoxazone.

Case 2. Acute liver failure due to chlorzoxazole.

[Modified from: Jackson J, Anania FA. Chlorzoxazone as a cause of acute liver failure requiring liver transplantation. *Dig Dis Sci* 2007; 52: 3389-91. [PubMed Citation](#)]

A 38 year old woman developed nausea, vomiting and progressive jaundice 6 weeks after starting chlorzoxazone (500 mg twice daily) for low back pain. Her other medical conditions included hypertension, gastrointestinal reflux and atopic dermatitis. Her medications included hydrochlorothiazide, pantoprazole, iron sulfate and skin creams. She denied taking herbal remedies or other over-the-counter products. She had no history of liver disease, alcohol abuse, risk factors for viral hepatitis or drug allergies. When initially seen she was jaundiced and lethargic. Laboratory results showed total bilirubin of 19.9 mg/dL, ALT 1029 U/L, AST 846 U/L and prothrombin time 32.6 seconds. Because of progressive symptoms and worsening, she was referred to a liver transplant center. On admission, she was deeply jaundiced and had mild asterixis. She had no fever or rash. Tests for hepatitis A, B and C were negative as were antinuclear and smooth muscle antibodies. A CT scan of the abdomen showed a mild amount of ascites and a nodular liver, but no evidence of biliary obstruction. Two weeks later and within 16 days of onset she underwent emergency liver transplantation. The transplant was successful and she left the hospital in good condition.

Key Points

| | |
|---------------------------|-------------------------------|
| Medication: | Chlorzoxazone (1000 mg daily) |
| Pattern: | Hepatocellular |
| Severity: | 5+ (liver transplantation) |
| Latency: | 6 weeks |
| Recovery: | Incomplete |
| Other medications: | HCTZ, iron, pantoprazole |

Laboratory Values

| Time After Starting | Time After Stopping | ALT (U/L) | Prottime (sec) | Bilirubin (mg/dL) | Other |
|---|---------------------|-----------|----------------|-------------------|-----------|
| Nausea and vomiting starting 6 weeks after starting chlorzoxazone | | | | | |
| 6 weeks | 0 | 1029 | 32.6 | 19.9 | Admission |
| | 4 days | 1014 | 32.6 | 17.9 | Transfer |

Table continued from previous page.

| Time After Starting | Time After Stopping | ALT (U/L) | Protime (sec) | Bilirubin (mg/dL) | Other |
|----------------------|---------------------|-----------------------|---------------|-------------------|-------|
| 8 weeks | 16 days | 93 | 36.8 | 4.8 | |
| 9 weeks | 19 days | Liver transplantation | | | |
| Normal Values | | <42 | <14 | <1.2 | |

Comment

A young woman developed acute liver failure with an abrupt onset and progressive course 6 weeks after starting chlorzoxazone. Medical evaluation showed no other cause for the acute liver failure. Despite prompt discontinuation of the muscle relaxant, she had a rapidly progressive course.

PRODUCT INFORMATION

REPRESENTATIVE TRADE NAMES

Chlorzoxazone – Generic, Parafon Forte®

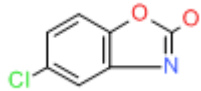
DRUG CLASS

Autonomic Agents: Muscle Relaxants, Central

COMPLETE LABELING

Product labeling at DailyMed, National Library of Medicine, NIH

CHEMICAL FORMULA AND STRUCTURE

| DRUG | CAS REGISTRY NO | MOLECULAR FORMULA | STRUCTURE |
|---------------|-----------------|-------------------|--|
| Chlorzoxazone | 95-25-0 | C7-H4-Cl-N-O2 |  |

ANNOTATED BIBLIOGRAPHY

References updated: 30 January 2017

Zimmerman HJ. Muscle spasmolytics. In, *Hepatotoxicity: The Adverse Effects of Drugs and Other Chemicals on the Liver*. 2nd Ed. Philadelphia: Lippincott, 1999. p. 544-45.

(Expert review of hepatotoxicity published in 1999 mentions that chlorzoxazone was incriminated in at least 33 instances of liver injury which were usually hepatocellular).

Hibbs RE, Zambon AC. Agents acting at the neuromuscular junction and autonomic ganglia. In, Brunton LL, Chabner BA, Knollman BC, eds. *Goodman & Gilman's The pharmacological basis of therapeutics*, 12th ed. New York: McGraw-Hill, 2011. p. 255-76.

(Textbook of pharmacology and therapeutics).

Lindholm L. [Fever, skin and liver reactions in a patient treated with Paraflex comp.] *Lakartidningen* 1979; 76: 2795-6. Swedish. PubMed PMID: 160967.

(77 year old woman developed fever, rash after 4 days and cholestatic enzyme elevations after 11 days of a combination of chlorzoxazone, propoxyphene and aspirin without jaundice, resolving in 8 weeks: Case 1).

[Effects on liver of analgesics containing dextropropoxyphene and/or chlorzoxazone.] Lakartidningen 1982; 79: 3823. Swedish. PubMed PMID: 7154757.

(Reports to Swedish Registry of 13 cases of hepatic injury due to Paraflex Comp that included aspirin and dextropropoxyphene in combination with chlorzoxazone).

Powers BJ, Cattau EL Jr, Zimmerman HJ. Chlorzoxazone hepatotoxic reactions. An analysis of 21 identified or presumed cases. Arch Intern Med 1986; 146: 1183-6. PubMed PMID: 3521519.

(Case report and review of FDA reports; 55 year old woman developed jaundice 3-4 weeks after starting chlorzoxazone [peak bilirubin 9.0 mg/dL, ALT 720 U/L] and had a positive rechallenge with fever, nausea and jaundice within day of receiving one pill; review of 23 FDA cases, average age 45, latency either <1 month or variable hepatocellular enzyme pattern; 60% jaundiced, 22% fatal).

Nightingale SL. Chlorzoxazone warning on hepatotoxicity is strengthened. JAMA 1995; 274: 1903. PubMed PMID: 8568972.

(FDA report that warning on hepatotoxicity has been added to labeling of chlorzoxazone; based largely on analysis of Powers [1986]).

Chlorzoxazone hepatotoxicity. Med Lett Drugs Ther 1996; 38: 46. PubMed PMID: 8628182.

(Brief review of chlorzoxazone concludes that it is largely ineffective and can cause liver injury and therefore should be avoided).

Pillans PI. Drug associated hepatic reactions in New Zealand: 21 years experience. N Z Med J 1996; 109: 315-9. PubMed PMID: 8816722.

(In a large registry of cases of drug induced liver injury from New Zealand, chlorzoxazone is not listed among the 20 most common causes).

Kronenberg A, Krohenbohl S, Zimmermann A, Streuli R. [Severe hepatocellular damage after administration of paracetamol and chlorzoxazone in therapeutic dosage.] Schweiz Rundsch Med Prax 1998; 87: 1356-60. German. PubMed PMID: 9828666.

(64 year old man developed jaundice 3-4 weeks after starting chlorzoxazone and acetaminophen combination tablets [bilirubin 35.5 mg/dL, ALT 2796 U/L, Alk P 180 U/L, INR 1.7], with centrozonal necrosis on liver biopsy and ultimate recovery).

Bielecki JW, Schraner C, Briner V, Kuhn M. [Rhabdomyolysis and cholestatic hepatitis under treatment with simvastatin and chlorzoxazone.] Schweiz Med Wochenschr 1999; 129: 514-8. German. PubMed PMID: 10322565.

(73 year old woman developed myositis and liver injury 2 weeks after starting chlorzoxazone and 1 year after starting simvastatin [bilirubin 8.4 mg/dL, ALT 766 U/L, Alk P 160 U/L], with rapid resolution upon stopping both).

Tanaka E, Terada M, Misawa S. Cytochrome P450 2E1: its clinical and toxicological role. J Clin Pharm Ther 2000; 25: 165-75. PubMed PMID: 10886461.

(Chlorzoxazone is one of at least 70 substrates metabolized by CYP 2E1; its metabolism can be used as a test of liver function and to assess the activity of this enzyme that is induced by many toxins).

Chou R, Peterson K, Helfand M. Comparative efficacy and safety of skeletal muscle relaxants for spasticity and musculoskeletal conditions: a systematic review. J Pain Symptom Manage 2004; 28: 140-75. PubMed PMID: 15276195.

(Systematic review of safety and efficacy of muscle relaxants, including chlorzoxazone for which there is limited or inconsistent data regarding its effectiveness).

Russo MW, Galanko JA, Shrestha R, Fried MW, Watkins P. Liver transplantation for acute liver failure from drug-induced liver injury in the United States. *Liver Transpl* 2004; 10: 1018-23. PubMed PMID: 15390328.

(Among ~50,000 liver transplants done in the US between 1990 and 2002, 270 [0.5%] were done for drug induced acute liver failure, but none were attributed to chlorzoxazone).

Orellana M, Rodrigo R, Varela N, Araya J, Poniachi KJ, Csendes A, Smok G, et al. Relationship between in vivo chlorzoxazone hydroxylation, hepatic cytochrome P450 2E1 content and liver injury in obese non-alcoholic fatty liver disease patients. *Hepatol Res* 2006; 34: 57-63. PubMed PMID: 16321567.

(Chlorzoxazone is metabolized by CYP 2E1 activity and can be used to assess CYP 2E1 activity; among obese patients undergoing bariatric surgery, those with NASH had increased metabolism and increased CYP 2E1 activity).

Jackson J, Anania FA. Chlorzoxazone as a cause of acute liver failure requiring liver transplantation. *Dig Dis Sci* 2007; 52: 3389-91. PubMed PMID: 17390222.

(38 year old woman developed acute liver failure requiring transplantation 6 weeks after starting chlorzoxazone [bilirubin 17.9 mg/dL, ALT 1014 U/L, Alk P not given, INR 3.6]; first published report in ~10 years).

Reuben A, Koch DG, Lee WM; Acute Liver Failure Study Group. Drug-induced acute liver failure: results of a U.S. multicenter, prospective study. *Hepatology* 2010; 52: 2065-76. PubMed PMID: 20949552.

(Among 1198 patients with acute liver failure enrolled in a US prospective study between 1998 and 2007, 133 were attributed to drug induced liver injury, but none were due to chlorzoxazone or other muscle relaxants).

Björnsson ES, Bergmann OM, Björnsson HK, Kvaran RB, Olafsson S. Incidence, presentation and outcomes in patients with drug-induced liver injury in the general population of Iceland. *Gastroenterology* 2013; 144: 1419-25. PubMed PMID: 23419359.

(In a population based study of drug induced liver injury from Iceland, 96 cases were identified over a 2 year period, but none were attributed to chlorzoxazone or other muscle relaxants).

Hernández N, Bessone F, Sánchez A, di Pace M, Brahm J, Zapata R, A Chirino R, et al. Profile of idiosyncratic drug induced liver injury in Latin America. An analysis of published reports. *Ann Hepatol* 2014; 13: 231-9. PubMed PMID: 24552865.

(Systematic review of literature of drug induced liver injury in Latin American countries published from 1996 to 2012 identified 176 cases, but none were attributed to chlorzoxazine or other muscle relaxants).

Chalasani N, Bonkovsky HL, Fontana R, Lee W, Stolz A, Talwalkar J, Reddy KR, et al.; United States Drug Induced Liver Injury Network. Features and outcomes of 899 patients with drug-induced liver injury: The DILIN Prospective Study. *Gastroenterology* 2015; 148: 1340-1352.e7. PubMed PMID: 25754159.

(Among 899 cases of drug induced liver injury enrolled in a US prospective study between 2004 and 2013, 5 [0.7%] were attributed to muscle relaxants, including one due to chlorzoxazone: a 46 year old man who developed jaundice 4 weeks after starting chlorzoxazone [bilirubin 3.0 rising to 10.2 mg/dL, ALT 4064 U/L, Alk P 123 U/L], with recovery after stopping).