



TP63-Related Disorders

V Reid Sutton, MD¹ and Hans van Bokhoven, PhD²

Created: June 8, 2010; Updated: April 1, 2021.

Summary

Clinical characteristics

The *TP63*-related disorders comprise six overlapping phenotypes:

- Ankyloblepharon-ectodermal defects-cleft lip/palate (AEC) syndrome (which includes Rapp-Hodgkin syndrome)
- Acro-dermo-ungual-lacrima-tooth (ADULT) syndrome
- Ectrodactyly, ectodermal dysplasia, cleft lip/palate syndrome 3 (EEC3)
- Limb-mammary syndrome
- Split-hand/foot malformation type 4 (SHFM4)
- Isolated cleft lip/cleft palate (orofacial cleft 8)

Individuals typically have varying combinations of ectodermal dysplasia (hypohidrosis, nail dysplasia, sparse hair, tooth abnormalities), cleft lip/palate, split-hand/foot malformation/syndactyly, lacrimal duct obstruction, hypopigmentation, hypoplastic breasts and/or nipples, and hypospadias. Findings associated with a single phenotype include ankyloblepharon filiforme adnatum (tissue strands that completely or partially fuse the upper and lower eyelids), skin erosions especially on the scalp associated with areas of scarring, and alopecia, trismus, and excessive freckling.

Diagnosis/testing

The diagnosis of a *TP63*-related disorder is established in a proband with suggestive findings and a heterozygous pathogenic variant in *TP63* identified by molecular genetic testing.

Management

Treatment of manifestations: A multidisciplinary team of specialists in clinical genetics, dermatology, ophthalmology, otolaryngology, audiology, dentistry and prosthodontics, plastic surgery, nutrition/

Author Affiliations: 1 Professor, Department of Molecular and Human Genetics Baylor College of Medicine; Texas Children's Hospital Houston, Texas; Email: vrsutton@texaschildrens.org. 2 Professor, Molecular Neurogenetics Department of Human Genetics Radboud University Medical Center Nijmegen, the Netherlands; Email: hans.vanbokhoven@radboudumc.nl.

gastroenterology, and psychology is recommended. Skin erosions are treated with gentle wound care and periodic, dilute bleach soaks to prevent secondary infection, and infants with severe skin erosions are monitored and treated aggressively for dehydration, electrolyte imbalances, malnutrition, and infection. Wigs can be used for sparse hair and alopecia; dentures may be considered in early childhood and dental implants in the teens or early adulthood. Cleft lip/palate is managed per routine protocols; limb malformations are treated with occupational therapy and surgery as needed to optimize function.

Surveillance: Regular attention to dental needs and possible hearing loss.

Genetic counseling

The *TP63*-related disorders are inherited in an autosomal dominant manner. Approximately 30% of individuals diagnosed with a *TP63*-related disorder have an affected parent. The proportion of individuals with a *TP63*-related disorder caused by a *de novo* *TP63* pathogenic variant is approximately 70%. If a parent of the proband is affected and/or is known to have the pathogenic variant identified in the proband, the risk to the sibs is 50%. Once the *TP63* pathogenic variant has been identified in an affected family member, prenatal and preimplantation genetic testing are possible.

GeneReview Scope

<i>TP63</i> -Related Disorders: Included Phenotypes ¹
<ul style="list-style-type: none"> • Ankyloblepharon-ectodermal defects-cleft lip/palate syndrome (AEC syndrome) <ul style="list-style-type: none"> ◦ Rapp-Hodgkin syndrome • Acro-dermo-ungual-lacrimal-tooth syndrome (ADULT syndrome) • Ectrodactyly, ectodermal dysplasia, cleft lip/palate syndrome 3 (EEC3) • Limb-mammary syndrome • Split-hand/foot malformation type 4 (SHFM4) • Isolated cleft lip/cleft palate (orofacial cleft 8)

For synonyms and outdated names see Nomenclature.

1. For other genetic causes of these phenotypes, see Differential Diagnosis.

Diagnosis

Suggestive Findings

A *TP63*-related disorder **should be suspected/considered** in individuals with a combination of the following findings.

Clinical findings

- Ankyloblepharon filiforme adnatum
- Dermal erosions
- Signs of ectodermal dysplasia
 - Hypohidrosis
 - Nail dysplasia
 - Sparse hair
 - Tooth abnormalities
- Freckles in sun-exposed areas
- Cleft lip/palate
- Split-hand/foot malformation and/or syndactyly
- Lacrimal duct obstruction
- Hypopigmentation

- Hypospadias
- Hypoplastic nipples/breasts

Family history is consistent with autosomal dominant inheritance (e.g., affected males and females in multiple generations). Absence of a known family history does not preclude the diagnosis.

Note: The *TP63*-related disorders include five overlapping phenotypes as well as isolated cleft lip/palate (see Clinical Description and Table 2 for details on the phenotypes).

Establishing the Diagnosis

The diagnosis of a *TP63*-related disorder is **established** in a proband with suggestive findings and a heterozygous pathogenic variant in *TP63* identified by molecular genetic testing (see Table 1). Identification of a heterozygous *TP63* variant of uncertain significance does not establish or rule out the diagnosis of this disorder.

Molecular genetic testing approaches can include a combination of **gene-targeted testing** (single-gene testing and multigene panel) and **comprehensive genomic testing** (exome sequencing, genome sequencing) depending on the phenotype.

Gene-targeted testing requires that the clinician determine which gene(s) are likely involved, whereas genomic testing does not. Individuals with the distinctive findings described in Suggestive Findings are likely to be diagnosed using gene-targeted testing (see Option 1), whereas those with a phenotype indistinguishable from many other inherited disorders with ectodermal dysplasia, cleft lip/palate, or split-hand/foot malformation are more likely to be diagnosed using genomic testing (see Option 2).

Option 1

Single-gene testing. Sequence analysis of *TP63* is performed first to detect small intragenic deletions/insertions and missense, nonsense, and splice site variants. Note: Depending on the sequencing method used, single-exon, multiexon, or whole-gene deletions/duplications may not be detected. If no variant is detected by the sequencing method used, the next step is to perform gene-targeted deletion/duplication analysis to detect exon and whole-gene deletions or duplications.

A multigene panel that includes *TP63* and other genes of interest (see Differential Diagnosis) is more likely to identify the genetic cause of the condition while limiting identification of variants of uncertain significance and pathogenic variants in genes that do not explain the underlying phenotype. Note: (1) The genes included in the panel and the diagnostic sensitivity of the testing used for each gene vary by laboratory and are likely to change over time. (2) Some multigene panels may include genes not associated with the condition discussed in this *GeneReview*. (3) In some laboratories, panel options may include a custom laboratory-designed panel and/or custom phenotype-focused exome analysis that includes genes specified by the clinician. (4) Methods used in a panel may include sequence analysis, deletion/duplication analysis, and/or other non-sequencing-based tests.

For an introduction to multigene panels click [here](#). More detailed information for clinicians ordering genetic tests can be found [here](#).

Option 2

Comprehensive genomic testing does not require the clinician to determine which gene is likely involved. **Exome sequencing** is most commonly used; **genome sequencing** is also possible.

For an introduction to comprehensive genomic testing click [here](#). More detailed information for clinicians ordering genomic testing can be found [here](#).

Table 1. Molecular Genetic Testing Used in *TP63*-Related Disorders

Gene ¹	Method	Proportion of Probands with a Pathogenic Variant ² Detectable by Method
<i>TP63</i>	Sequence analysis ³	99% ⁴
	Gene-targeted deletion/duplication analysis ⁵	Rare ^{4, 6}

1. See Table A. Genes and Databases for chromosome locus and protein.

2. See Molecular Genetics for information on variants detected in this gene.

3. Sequence analysis detects variants that are benign, likely benign, of uncertain significance, likely pathogenic, or pathogenic. Variants may include small intragenic deletions/insertions and missense, nonsense, and splice site variants; typically, exon or whole-gene deletions/duplications are not detected. For issues to consider in interpretation of sequence analysis results, click [here](#).

4. Data derived from the subscription-based professional view of Human Gene Mutation Database [Stenson et al 2017]

5. Gene-targeted deletion/duplication analysis detects intragenic deletions or duplications. Methods used may include quantitative PCR, long-range PCR, multiplex ligation-dependent probe amplification (MLPA), and a gene-targeted microarray designed to detect single-exon deletions or duplications.

6. A single case report of a four-exon deletion of *TP63* has been reported in an individual with EEC3 [Aradhya et al 2012]. Partial deletions of *TP63* have been reported in families with orofacial cleft (with or without other findings of a *TP63*-related disorder) [Khandelwal et al 2019].

Clinical Characteristics

Clinical Description

The *TP63*-related disorders include the overlapping phenotypes summarized in Table 2 and fully described in the text that follows.

Table 2. *TP63*-Related Disorders: Comparison of Phenotypes by Select Features

Feature	<i>TP63</i> -Related Disorder					
	AEC	ADULT	EEC3	Limb-mammary	SHFM4	Orofacial cleft ⁸
Ankyloblepharon filiforme adnatum	X					
Ectodermal dysplasia	X	X	X		Rare	
<div style="display: flex; align-items: center;"> <div style="width: 20px; height: 20px; border: 1px solid black; margin-right: 5px;"></div> <div style="flex-grow: 1;"> <p>Hypohidrosis ¹</p> <p>Nail dysplasia</p> <p>Sparse hair</p> <p>Tooth abnormalities</p> </div> </div>	X	X		X		
	X	X	Mild	X		
	X	X	X			
	X	X	X	X		
Cleft lip/palate	X		X	X		X
Split-hand/foot malformation / syndactyly	X	X	X	X	X	
Lacrimal duct obstruction	X	X	X	X		
Dermal erosions	X					
Hypopigmentation	X	X	X			
Hypospadias	X		X			
Trismus	X					
Excessive freckling		X				

Table 2. continued from previous page.

Feature	TP63-Related Disorder					
	AEC	ADULT	EEC3	Limb-mammary	SHFM4	Orofacial cleft 8
Hypoplastic breasts		X		X		
Hypoplastic nipples		X		X		

ADULT = acro-dermato-ungual-lacrimar-tooth; AEC = ankyloblepharon-ectodermal defects-cleft lip/palate; EEC3 = ectrodactyly (split-hand/foot malformation), ectodermal dysplasia, cleft lip/palate syndrome 3; SHFM4 = split-hand/foot malformation type 4
 1. Mostly subjective

AEC Syndrome

The manifestations of ankyloblepharon-ectodermal defects-cleft lip/palate (AEC) syndrome are typically present at birth.

Ankyloblepharon is present in 70% of neonates. While the upper- and lower-eyelid adhesions can be obvious, partial adhesion of the upper and lower eyelids can be subtle and the filiform adhesions can spontaneously lyse before they are recognized as such.

Lacrimal puncta are frequently absent, often leading to chronic conjunctivitis and blepharitis, which is often not recognized in infancy but seen in early childhood [Sutton et al 2009].

Ectodermal defects

- **Skin.** Nearly 100% of affected neonates have superficial skin erosions that vary from very limited to severe, life-threatening full-body involvement. The erosions most typically affect the scalp at birth and during infancy. Severe scalp erosions often lead to scarring alopecia and hypotrichosis. This is NOT seen in other TP63-related disorders.

The skin erosions tend to be recurrent and intermittent throughout childhood and into adulthood with frequent involvement of the head and neck, palms, soles, and skin folds.

Congenital erythroderma (i.e., diffuse erythema with associated erosions) is observed in 70%-90% of infants. The skin can also appear shiny with a collodion membrane (red, shiny, membranous skin changes) [Siegfried et al 2005].

Children typically manifest cutaneous depigmentation and scarring, most likely due to postinflammatory pigmentary changes related to previous erythroderma and associated underlying erosions that may or may not be appreciated clinically. African American infants can have facial hypopigmentation in a mask pattern that improves with age. Affected individuals with fair skin typically have a reticulated hyperpigmentation on the neck and intertriginous areas that progresses with age to cribriform, reticulate, stellate, or punctate scarring most commonly on the shoulders, upper back, and chest.

Histopathologic features of skin biopsies may reveal epidermal atrophy, pigment incontinence, and a prominent superficial perivascular plexus with limited lymphocytic infiltrate [Dishop et al 2009].

- **Hair changes** become more obvious with age. Hair is typically light colored and coarse, wiry, and brittle with a spun-glass/gold or "uncombable" appearance. Eyebrows and eyelashes are sparse. Light and scanning microscopy may reveal structural and pigmentary alterations of the hair including kinking, grooves, and discontinuous pigmentation.
- **Nail changes**, present in all and more obvious with age, vary among individuals. Most affected individuals have nail dystrophy (abnormal nail plate texture) and hyperconvex nail plates. Micronychia (abnormally

small nail plates), distal frayed edges with nail plate resorption, and absent nails are also frequent [Julapalli et al 2009].

- **Dental anomalies.** Malformed teeth (conical shape with small occlusal tables) and hypodontia (reduced number of teeth) also become evident during childhood and adolescence. Affected adults have an average of 4.75 secondary teeth [Farrington & Lausten 2009].
- **Sweating.** In certain cases, there are fewer sweat pores and decreased sweating [Ferstl et al 2018]; however, this does NOT lead to hyperthermia or fevers as seen in [hypohidrotic ectodermal dysplasia](#).

Clefting is present in all. Clefting can include submucous cleft palate only, cleft of the soft and/or the hard palate only, cleft lip only, or the combination of cleft lip and cleft palate [Cole et al 2009].

Other findings include the following:

- **Limb anomalies** were initially not considered to be part of the syndrome, but syndactyly of fingers and toes and/or camptodactyly (permanent and irreducible flexion of the fingers) of hands have been seen. Split-hand/foot malformation was observed in two of 17 individuals (12%) with AEC syndrome [Sutton et al 2009].
- **Hypospadias** has been reported in 78% of males with AEC syndrome [Sutton et al 2009].
- **Facial features** become more distinctive with age. Findings commonly include maxillary hypoplasia, micrognathia, broad nasal root, underdeveloped alae nasi, thin vermilion of the upper lip, and short philtrum.
- **Trismus** has been reported in 35% of individuals with AEC syndrome [Sutton et al 2009].
- **Hearing loss.** More than 90% of children have conductive hearing loss, often with secondary speech delay [Cole et al 2009].
- **Growth.** Poor weight gain and failure to thrive should be anticipated. When treated appropriately with nutritional supplementation poor weight gain improves with age.
Linear growth abnormalities are observed in early childhood with a significantly lower height for age compared to the reference population. The growth pattern in AEC is similar to that reported for hypohidrotic ectodermal dysplasia [Motil & Fete 2009].
- **Psychological impact** related to the phenotypic features of the disease can include a reduced quality of life with negative impact on both child and family. In one study, a variable degree of psychological functioning was noted with some families reporting few ill effects from the disease while others reported significant impact [Lane et al 2009].

ADULT Syndrome

The manifestations of acro-dermato-ungual-lacrima-tooth (ADULT) syndrome are typically present at birth (although they may become more prominent with age), with the exception of skin freckling.

Limb anomalies. Syndactyly of fingers and toes is most commonly seen.

Ectodermal defects

- **Skin** tends to be dry but erosions are not present.
- **Hair changes** are more obvious with age. Hair is typically light colored and fine. Eyebrows and eyelashes are sparse.
- **Nail dysplasia** is commonly reported.

- **Dental anomalies.** Malformed teeth (conical shape with small occlusal tables) and hypodontia (reduced number of teeth) also become evident during childhood and adolescence.
- **Sweating.** Subjective decreased sweat production is universal and is reported as heat intolerance; however, this does NOT lead to hyperthermia or fevers as seen in [hypohidrotic ectodermal dysplasia](#).

Lacrimal duct atresia is frequent and often leads to chronic conjunctivitis and blepharitis, which are often not recognized until early childhood [Sutton et al 2009].

Breast and/or nipple hypoplasia is seen commonly and most notably in females. This feature is characteristic of ADULT and limb-mammary syndrome and NOT typically seen in other TP63-related disorders.

Excessive freckling in sun-exposed areas is seen in a subset of affected individuals and progresses with age and sun exposure. This feature is NOT seen in other TP63-related disorders.

EEC3

The manifestations of ectrodactyly, ectodermal dysplasia, cleft lip/palate syndrome 3 (EEC3) are typically present at birth.

Limb anomalies are seen in 68%-90% of individuals with 60% having tetramelic involvement. A wide variety of limb abnormalities are reported including syndactyly, oligodactyly, split-hand/foot malformation, and digital duplication. A cohort of 152 individuals with EEC syndrome showed split-hand/foot malformation in 68% and syndactyly in 43% [Rinne et al 2006a].

Ectodermal defects

- **Skin** tends to be dry but erosions are not present.
- **Hair changes** become more obvious with age and are seen in 60%-80% of individuals with EEC syndrome [Rinne et al 2006a]. Hair is typically silvery blond, coarse, and dry; 20% have sparse hair. Light microscopy has been reported to be normal in EEC syndrome [Pashayan et al 1974]. Eyebrows and eyelashes are sparse.
- **Nail dysplasia** is commonly reported.
- **Dental anomalies.** Malformed teeth (conical shape with small occlusal tables) and hypodontia (reduced number of teeth) also become evident during childhood and adolescence.
- **Sweating.** Hypohidrosis is uncommon in EEC3 [Ferstl et al 2018].

Cleft lip with or without cleft palate is present in 60%-75% and is bilateral in half of cases. Clefting can include submucous cleft palate only, cleft of the soft and/or the hard palate only, cleft lip only, or the combination of cleft lip and cleft palate [Buss et al 1995].

Absent lacrimal puncta is reported in 90% of individuals and results in tearing, blepharitis, dacryocystitis, keratoconjunctivitis, and photophobia and often leads to corneal ulceration and scarring [Buss et al 1995].

Genitourinary malformations are reported in 45% and may include hypospadias and developmental abnormalities of the kidneys and urinary collecting system.

Limb-Mammary Syndrome

The manifestations of limb-mammary syndrome are typically present at birth.

Limb anomalies including split-hand/foot malformation and syndactyly are reported in 75%-85% of individuals.

Breast and/or nipple hypoplasia is seen commonly with almost all individuals having nipple aplasia or hypoplasia and 90% of females having mammary gland aplasia or hypoplasia. This feature is characteristic of ADULT and limb-mammary syndrome and NOT typically seen in other *TP63*-related disorders.

Lacrimal duct atresia is seen in about half leading to chronic conjunctivitis and blepharitis, which are often not recognized until early childhood [van Bokhoven et al 1999].

Ectodermal defects

- **Nail dysplasia** is reported in 30% of individuals.
- **Dental anomalies.** Hypodontia (reduced number of teeth) also becomes evident during childhood and adolescence and is seen in 10%-15%.

Note: Skin and hair abnormalities are NOT typically seen, in contrast to other *TP63*-related disorders.

Cleft lip with or without cleft palate is present in 25%-30% of individuals and can include submucous cleft palate only, cleft of the soft and/or the hard palate only, cleft lip only, or the combination of cleft lip and cleft palate.

SHFM4

The manifestations of split-hand/foot malformation-4 (SHFM4) are typically present at birth.

Limb abnormalities include median clefts of the hands and feet; aplasia/hypoplasia of phalanges, metacarpals, and metatarsals; and some syndactyly.

Ectodermal abnormalities and cleft lip/palate are considered to be exclusion criteria for making the diagnosis SHFM4.

Isolated Cleft Lip/Palate (Orofacial Cleft 8)

Identification of a *TP63* pathogenic variant in three individuals - a girl age 4 years; a boy age 3 years and his father; all with apparent nonsyndromic cleft lip/palate - have been reported by Leoyklang et al [2006] and Basha et al [2018], respectively. Further evaluations revealed no other features of *TP63*-related disorders in these individuals.

Khandelwal et al [2019] identified partial deletions of *TP63* in individuals from three families with orofacial cleft and/or hypodontia and minor anomalies of the skin and nails.

Genotype-Phenotype Correlations

Note: Pathogenic variants have been described on two *TP63* isoforms: the TAp63 α isoform, encoded by [NM_003722.4](#), and the Δ Np63 α isoform, encoded by [NM_001114982.1](#), which is 39 amino acids shorter and has an alternate N-terminal TA domain. See Figure 1 for details.

AEC syndrome. All pathogenic variants associated with AEC syndrome occur in either the sterile alpha motif (SAM) domain (82%) or the Δ Np63-specific N-terminal domain (18%). Pathogenic variants in the N-terminal domain that introduce premature termination codons lead to the use of an alternative start codon [Rinne et al 2008] and to the consequent production of Δ Np63 α isoforms lacking the N-terminal domain, which are specifically associated with AEC syndrome. This isoform of p63 is the predominant isoform in mature epidermis, and it has been shown to repress ZNF750, leading to impaired epidermal differentiation [Zarnegar et al 2012].

ADULT syndrome is typically associated with pathogenic variants in the DNA binding domain. Other pathogenic variants have been reported in isolated individuals with features reminiscent of ADULT syndrome,

but also of other *TP63*-associated syndromes in $\Delta Np63\alpha$ (an alternative TA domain), in TAp63 α between the TA and DNA binding domains [Rinne et al 2006b, Rinne et al 2007], and at other locations in TAp63 α [van Zelst-Stams & van Steensel 2009].

EEC3. All EEC3-causing pathogenic variants are missense variants in the DNA binding domain and have been demonstrated to disrupt DNA binding [Rinne et al 2006b]. Splice changes and frameshifts associated with EEC3 have been reported [Celli et al 1999, van Bokhoven et al 2001, Barrow et al 2002, Monti et al 2013].

Limb-mammary syndrome is caused by pathogenic missense variants that are located between the transactivation domain and the DNA binding domain (p.Gly115, p.Ser129, and p.Gly173 residues in TAp63 α) or by truncating variants in the SAM domain of *TP63* [van Bokhoven et al 2001, Rinne et al 2007].

SHFM4. Pathogenic missense variants in the TA and DNA binding domains have been associated with SHFM4 [Rinne et al 2007].

Orofacial cleft 8 has been associated with a *TP63* variant in the DNA binding domain [Leoyklang et al 2006, Basha et al 2018].

Penetrance

Reduced penetrance or possible germline mosaicism has been documented in a small number of individuals and families.

- Reduced penetrance for SHFM4 [Spranger & Schapera 1988] and ADULT syndrome [Amiel et al 2001] has been reported.
- A few individuals who do not appear to be clinically affected have had more than one child with AEC syndrome. These occurrences may be the result of reduced penetrance, but are more likely the result of somatic and germline mosaicism in one parent.

In one family, the *TP63* pathogenic variant present in affected fraternal twins was also present in the phenotypically normal mother. The data suggested somatic mosaicism in the mother [van Bokhoven, unpublished data] with presumed germline mosaicism.

Nomenclature

Ankyloblepharon-ectodermal defects-cleft lip/palate (AEC) syndrome is also known as Hay-Wells syndrome, after the physicians who first described the condition in 1976.

Rapp-Hodgkin syndrome (RHS), once considered a separate entity, is now considered to be part of the spectrum of the AEC syndrome because of the overlap of clinical manifestations and *TP63* pathogenic variants in the two conditions [Cambiaghi et al 1994, McGrath et al 2001].

EEC3 is thought to be genetically unrelated to EEC1 (which has been mapped to chromosome 7q11q21). An entity called EEC2 was initially mapped to chromosome 19 [O'Quinn et al 1998]; however, pathogenic variants in *TP63* were ultimately identified [Celli et al 1999].

Prevalence

TP63-related disorders are rare. The prevalence of disorders individually or collectively is unknown.

Genetically Related (Allelic) Disorders

No phenotypes other than those discussed in this *GeneReview* are known to be associated with a heterozygous germline pathogenic variant in *TP63*.

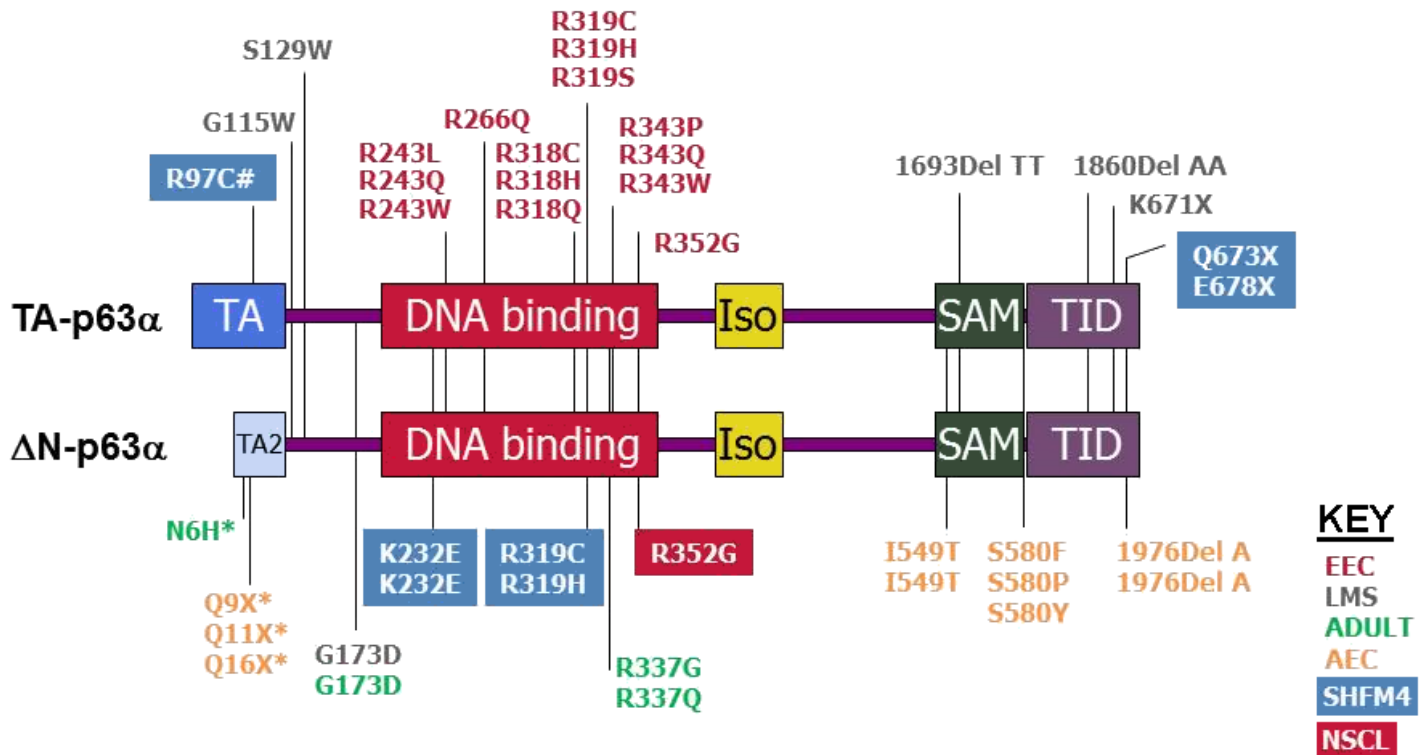


Figure 1. Typical and common *TP63* pathogenic variants identified in various disorders as indicated by color key. Pathogenic variants indicated by * are specific for the Δ Np63 α isoform and their numbering is based on the respective reference sequences (NM_001114982.1, NP_001108454.1). The numbering of other pathogenic variants is based on the reference sequences for TAp63 α (NM_003722.5, NP_003713.3). Note that the variant indicated by # (R97C) is specific for TAp63 α .

EEC = ectrodactyly, ectodermal dysplasia, cleft lip/palate syndrome

LMS = limb-mammary syndrome

ADULT = acro-dermo-ungual-lacrimal-tooth syndrome

AEC = ankyloblepharon-ectodermal defects-cleft lip/palate syndrome

SHFM4 = split-hand/foot malformation type 4

NSCL = nonsyndromic cleft lip

Differential Diagnosis

Table 3. Genes of Interest in the Differential Diagnosis of *TP63*-Related Disorders

<i>TP63</i> -Related Disorder	Differential Diagnosis	Gene/Genetic Mechanism	MOI	Overlapping Features	Distinguishing Features
AEC syndrome	Epidermolysis bullosa simplex (EBS)	<i>EXPH5</i> <i>KRT5</i> <i>KRT14</i> <i>TGM5</i>	AR AD	Skin erosions at birth	<ul style="list-style-type: none"> Erosions in AEC syndrome are typically more superficial & not assoc w/formation of bullae. Nondermatologic features & dermatopathology also distinguish EBS from AEC syndrome.

Table 3. continued from previous page.

TP63-Related Disorder	Differential Diagnosis	Gene/ Genetic Mechanism	MOI	Overlapping Features	Distinguishing Features
	Autosomal recessive congenital ichthyosis	<i>ABCA12</i> <i>ALOX12B</i> <i>ALOXE3</i> <i>CASP14</i> <i>CERS3</i> <i>CYP4F22</i> <i>LIPN</i> <i>NIPAL4</i> <i>PNPLA1</i> <i>SDR9C7</i> <i>SLC27A4</i> <i>TGM1</i>	AR	Erythroderma w/ collodion membrane in newborn period ¹	AEC is not assoc w/collodion membrane or ichthyosis.
	Curly hair-ankyloblepharon-nail dysplasia syndrome (CHANDS) (OMIM 214350)	<i>RIPK4</i>	AR	Ankyloblepharon & hair changes	CHANDS typically does not incl significant facial/oral clefting or skin erosions that are virtually universal in AEC syndrome.
	Cocoon syndrome ²	<i>CHUK</i>	AR AD	Ankyloblepharon, cleft lip/palate, ectodermal dysplasia	Cocoon syndrome is assoc w/ hypogammaglobulinemia & recurrent infections (features not observed in AEC syndrome)
SHFM4	SHFM1 (OMIM 183600)	<i>DLX5</i>	AD	Split-hand/foot malformation	<ul style="list-style-type: none"> SHFM1 is assoc w/high incidence of hearing loss. Findings are largely restricted to limbs. Dental & lacrimal duct abnormalities are seen in <10% of persons. ³
	SHFM3 (OMIM 246560)	10q24 contiguous gene duplication	AD		SHFM3 is not assoc w/lacrimal, dental, or ectodermal abnormalities (beyond nail abnormalities assoc w/ developmental defects of the digits). ⁴
	SHFM6 (OMIM 225300)	<i>WNT10B</i> ⁵	AR		SHFM6 is not assoc w/lacrimal, dental, or ectodermal abnormalities.
TP63-related disorders generally	Hypohidrotic ectodermal dysplasia (HED)	<i>EDA</i> <i>EDAR</i> <i>EDARADD</i> <i>WNT10A</i>	AD AR XL	Hypotrichosis, hypohidrosis, hypodontia	<ul style="list-style-type: none"> Hypohidrosis in HED is severe enough to impair body temperature regulation, a problem not seen in TP63-related disorders. Orofacial clefting, universal in AEC syndrome, is not typically seen in HED.

AEC = ankyloblepharon-ectodermal defects-cleft lip/palate; AD = autosomal dominant; AR = autosomal recessive; MOI = mode of inheritance; SHFM = split-hand/foot malformation; XL = X-linked

1. Siegfried et al [2005]

2. Cadieux-Dion et al [2018]

3. Elliott & Evans [2006]

4. de Mollerat et al [2003], Elliott & Evans [2006]

5. Interestingly, all but one of the affected individuals in the initial pedigree also had promoter polymorphism in TP63 [Ugur & Tolun 2008].

Hereditary disorders of unknown genetic cause to consider in the differential diagnosis of *TP63*-related disorders

- **Differential diagnosis of ectrodactyly, ectodermal dysplasia, cleft lip/palate syndrome (EEC).** EEC1 (OMIM 129900) is suspected to be caused by pathogenic variants in a gene on chromosome 7q21-q22 based on a series of individuals with various cytogenetically visible chromosomal abnormalities. Other EEC-like phenotypes that do not appear to involve the EEC1 and EEC3 loci have been described.
- **Differential diagnosis of split-hand/foot malformation type 4 (SHFM4).** SHFM2 (OMIM 313350) has been mapped to Xq26, and while both males and females are affected, males tend to have a more severe phenotype. Cleft lip/palate and ectodermal defects are not seen in this condition.

Management

No clinical practice guidelines for *TP63*-related disorders have been published.

Evaluations Following Initial Diagnosis

To establish the extent of disease and needs in an individual diagnosed with a *TP63*-related disorder, the evaluations summarized in Table 4 (if not performed as part of the evaluation that led to the diagnosis) are recommended.

Table 4. Recommended Evaluations Following Initial Diagnosis in Individuals with a *TP63*-Related Disorder

System/Concern	Evaluation	Comment
Ocular issues	Ophthalmologic eval	Evaluate for ankyloblepharon, lacrimal duct atresia/obstruction, dry eyes, & blepharitis.
Skin, hair, & nail issues	Dermatologic eval	
Dental anomalies	Dental & prosthodontics evals	Assess for need for implants.
Cleft lip/palate	Eval by multispecialty cleft team	
Hearing loss	Otolaryngologic eval & auditory evoked responses	
Breast/nipple asymmetry	Plastic surgery eval	
Growth delay	Nutritional eval	Further assessment by gastroenterologist may be needed.
Developmental delay	Developmental assessment	
Limb malformations	<ul style="list-style-type: none"> • OT/PT evals • Hand surgery eval 	
Genetic counseling	By genetics professionals ¹	To inform affected persons & their families re nature, MOI, & implications of a <i>TP63</i> -related disorder to facilitate medical & personal decision making

Table 4. continued from previous page.

System/Concern	Evaluation	Comment
Family support/resources	Assess: <ul style="list-style-type: none"> • Use of community or online resources such as Parent to Parent; • Need for social work involvement for parental support; • Impact of phenotype on normal life & need for counseling. 	

MOI = mode of inheritance; OT = occupational therapy; PT = physical therapy

I. Medical geneticist, certified genetic counselor, certified advanced genetic nurse

Treatment of Manifestations

Management by multidisciplinary specialists, including clinical genetics, dermatology, ophthalmology, otolaryngology, audiology, dentistry and prosthodontics, plastic surgery, nutrition/gastroenterology, and psychology, is recommended.

Table 5. Treatment of Manifestations in Individuals with a TP63-Related Disorder

Manifestation/Concern	Treatment	Considerations/Other
Ankyloblepharon filiforme adnatum	These strands of tissue between upper & lower eyelids are often small & autolyse shortly after birth; larger ones may require surgical separation by ophthalmologist.	
Lacrimal duct atresia/obstruction	Possible need for probing or surgical intervention per ophthalmologist	
Dry eyes / blepharitis	Hydrating ocular drops or gels	
Skin erosions	Gentle wound care & periodic, dilute bleach soaks (Dakins solution) to prevent secondary infection	Occlusive dressings should not be used, as they tend to stimulate granulation tissue.
	Treat secondary infections w/topical or oral antibiotics or antifungal agents when appropriate.	Empiric treatment (i.e., use of antibiotic w/o culture-proven infection) is not recommended.
	Infants w/severe skin erosions: monitor & treat aggressively for dehydration, electrolyte imbalances, malnutrition, & secondary infection & sepsis.	
Sparse hair / alopecia	Wigs can be used as desired.	
Hypodontia	<ul style="list-style-type: none"> • Childhood: consider dentures. • Teen or early-adult: consider dental implants. 	
Cleft lip/palate	Care managed by a multispecialty cleft team	
Hearing loss	Myringotomy for conductive hearing loss from chronic otitis media	
Breast/nipple asymmetry	Females: significant breast asymmetry may be corrected w/plastic surgery.	
Growth delay	Optimization of oral caloric intake	Gastrostomy tube placement may be considered.

Table 5. continued from previous page.

Manifestation/Concern	Treatment	Considerations/Other
Developmental delay	Assessment & treatment by developmental pediatrician &/or child neuropsychologist	
Limb malformations	OT & hand/foot surgery as needed to optimize function	
Psychological impact of phenotypic features	Referral for psychological support/counseling as necessary	

OT = occupational therapy

Surveillance

Table 6. Recommended Surveillance for Individuals with a TP63-Related Disorder

System/Concern	Evaluation	Frequency
Hypodontia	Prosthodontic assessment	Per dental specialist
Hearing loss	Audiologic testing	Per audiologist/otolaryngologist

Agents/Circumstances to Avoid

Prolonged exposure to sunlight should be avoided to:

- Prevent sunburn of hypopigmented areas and increase in contrast between the patchy areas of hyper- and hypopigmentation seen in AEC syndrome;
- Minimize freckling of skin in individuals with ADULT syndrome.

Evaluation of Relatives at Risk

It is appropriate to clarify the genetic status of apparently asymptomatic at-risk relatives in order to identify as early as possible those who would benefit from regular evaluation for disease manifestations with attention to dental needs and possible hearing loss.

See Genetic Counseling for issues related to testing of at-risk relatives for genetic counseling purposes.

Therapies Under Investigation

Search [ClinicalTrials.gov](https://clinicaltrials.gov) in the US and [EU Clinical Trials Register](https://european-clinical-trials-register.eu) in Europe for access to information on clinical studies for a wide range of diseases and conditions. Note: There may not be clinical trials for this disorder.

Genetic Counseling

Genetic counseling is the process of providing individuals and families with information on the nature, mode(s) of inheritance, and implications of genetic disorders to help them make informed medical and personal decisions. The following section deals with genetic risk assessment and the use of family history and genetic testing to clarify genetic status for family members; it is not meant to address all personal, cultural, or ethical issues that may arise or to substitute for consultation with a genetics professional. —ED.

Mode of Inheritance

TP63-related disorders are inherited in an autosomal dominant manner.

Risk to Family Members

Parents of a proband

- Approximately 30% of individuals diagnosed with AEC have an affected parent. This appears to be true for the other *TP63*-related disorders as well [H van Bokhoven, AF Bree, VR Sutton, unpublished data].
- The proportion of individuals with AEC caused by a *de novo TP63* pathogenic variant is approximately 70%. This appears to be true for the other *TP63*-related disorders as well [H van Bokhoven, AF Bree, VR Sutton, unpublished data].
- If the proband appears to be the only affected family member (i.e., a simplex case), molecular genetic testing is recommended for the parents of the proband to confirm their genetic status and to allow reliable recurrence risk counseling.
- If the pathogenic variant identified in the proband is not identified in either parent, the following possibilities should be considered:
 - The proband has a *de novo* pathogenic variant. Note: A pathogenic variant is reported as "*de novo*" if: (1) the pathogenic variant found in the proband is not detected in parental DNA; and (2) parental identity testing has confirmed biological maternity and paternity. If parental identity testing is not performed, the variant is reported as "assumed *de novo*" [Richards et al 2015].
 - The proband inherited a pathogenic variant from a parent with germline (or somatic and germline) mosaicism * [Enriquez et al 2016; van Bokhoven, unpublished data]. Note: Testing of parental leukocyte DNA may not detect all instances of somatic mosaicism.
 - * A parent with somatic and germline mosaicism for a *TP63* pathogenic variant may be mildly/minimally affected.
- The family history of some individuals diagnosed with a *TP63*-related disorder may appear to be negative because of failure to recognize the disorder in family members or reduced penetrance. Therefore, an apparently negative family history cannot be confirmed unless molecular genetic testing has demonstrated that neither parent is heterozygous for the *TP63* pathogenic variant identified in the proband.

Sibs of a proband. The risk to the sibs of the proband depends on the genetic status of the proband's parents:

- If a parent of the proband is affected and/or is known to have the pathogenic variant identified in the proband, the risk to the sibs is 50%. There can be a significant range of clinical variability in affected family members.
- If the *TP63* pathogenic variant identified in the proband cannot be detected in the leukocyte DNA of either parent, the recurrence risk to sibs is slightly greater than that of the general population because of the possibility of parental germline mosaicism [Enriquez et al 2016; van Bokhoven, unpublished data].
- If the parents have not been tested for the *TP63* pathogenic variant but are clinically unaffected, the risk to the sibs of a proband appears to be low. However, sibs of a proband with clinically unaffected parents are still presumed to be at increased risk for a *TP63*-related disorder because of the possibility of reduced penetrance in a heterozygous parent or the possibility of parental germline mosaicism.

Offspring of a proband. Each child of an individual with a *TP63*-related disorder has a 50% chance of inheriting the *TP63* pathogenic variant.

Other family members. The risk to other family members depends on the genetic status of the proband's parents: if a parent has the *TP63* pathogenic variant, his or her family members may be at risk.

Related Genetic Counseling Issues

See Management, Evaluation of Relatives at Risk for information on evaluating at-risk relatives for the purpose of early diagnosis and treatment.

Family planning

- The optimal time for determination of genetic risk and discussion of the availability of prenatal/preimplantation genetic testing is before pregnancy.
- It is appropriate to offer genetic counseling (including discussion of potential risks to offspring and reproductive options) to young adults who are affected or at risk.

Prenatal Testing and Preimplantation Genetic Testing

Once the *TP63* pathogenic variant has been identified in an affected family member, prenatal and preimplantation genetic testing are possible.

Differences in perspective may exist among medical professionals and within families regarding the use of prenatal testing. While most centers would consider use of prenatal testing to be a personal decision, discussion of these issues may be helpful.

Resources

GeneReviews staff has selected the following disease-specific and/or umbrella support organizations and/or registries for the benefit of individuals with this disorder and their families. GeneReviews is not responsible for the information provided by other organizations. For information on selection criteria, click [here](#).

- **National Foundation for Ectodermal Dysplasias (NFED)**

Phone: 618-566-2020

Email: info@nfed.org

www.nfed.org

- **American Cleft Palate-Craniofacial Association**

Phone: 919-933-9044

acpa-cpf.org

- **Children's Craniofacial Association**

Phone: 800-535-3643

Email: contactCCA@ccakids.com

www.ccakids.org

- **Ectodermal Dysplasia Society**

United Kingdom

Phone: 01242 261332

Email: info@edsociety.co.uk

www.edsociety.co.uk

- **Face Equality International**

United Kingdom

faceequalityinternational.org

- **National Library of Medicine Genetics Home Reference**

[Ankyloblepharon-ectodermal defects-cleft lip/palate syndrome](#)

- **Selbsthilfegruppe Ektodermale Dysplasie e.V.**

Consumer health-oriented organization for Germany, Austria, and Switzerland

Germany

Phone: 7127 969691

Email: andrea@ektodermale-dysplasie.de

www.ektodermale-dysplasie.de

- **Ectodermal Dysplasias International Registry**

Email: info@nfed.org

[Ectodermal Dysplasias International Registry](#)

Molecular Genetics

Information in the Molecular Genetics and OMIM tables may differ from that elsewhere in the GeneReview: tables may contain more recent information. —ED.

Table A. TP63-Related Disorders: Genes and Databases

Gene	Chromosome Locus	Protein	Locus-Specific Databases	HGMD	ClinVar
<i>TP63</i>	3q28	Tumor protein 63	TP63 @ LOVD	TP63	TP63

Data are compiled from the following standard references: gene from [HGNC](#); chromosome locus from [OMIM](#); protein from [UniProt](#). For a description of databases (Locus Specific, HGMD, ClinVar) to which links are provided, click [here](#).

Table B. OMIM Entries for TP63-Related Disorders ([View All in OMIM](#))

103285	ADULT SYNDROME
106260	ANKYLOBLEPHARON-ECTODERMAL DEFECTS-CLEFT LIP/PALATE; AEC
129400	RAPP-HODGKIN SYNDROME; RHS
603273	TUMOR PROTEIN p63; TP63
603543	LIMB-MAMMARY SYNDROME; LMS
604292	ECTRODACTYLY, ECTODERMAL DYSPLASIA, AND CLEFT LIP/PALATE SYNDROME 3; EEC3
605289	SPLIT-HAND/FOOT MALFORMATION 4; SHFM4
618149	OROFACIAL CLEFT 8; OFC8

Molecular Pathogenesis

Transcription factor p63 encoded by *TP63* is a key regulator in epithelial commitment and development. *TP63* encodes a large number of p63 isoforms, which are engaged in dimeric and tetrameric complexes regulating a network of genes important for development of ectodermal structures [Khandelwal et al 2019]. Different p63 isoforms have been shown to play roles in various cells and tissues, such as the epidermis, oocytes, muscles, and cochlea. TP63 is a master regulator of the embryonic development and differentiation of ectodermal cells

[Shalom-Feuerstein et al 2013]. Additionally, it plays a critical role in the development of the apical ectodermal ridge of the limb bud in collaboration with the signaling molecule FGF8 [Restelli et al 2014]. The ΔN promoter is the only active promoter and the 3' exon is the first expressed exon detected in epidermal cells throughout epidermal stratification in many epithelial cells, such as those from skin, oral tissues, and the mammary gland [Sethi et al 2015, Soares & Zhou 2018]. In contrast, the TA isoform is generally expressed at a low level in a range of nonepithelial cells. Thus, TAp63 is expressed in oocytes and plays an important role in controlling apoptosis in response to DNA damage [Deutsch et al 2011]. In the cochlea, the TA isoform is also expressed and regulates the Notch signaling pathway, which is required for proper cochlea development [Terrinoni et al 2013]. Additionally, TAp63 has been found to be expressed in late-stage myogenesis [Cefalù et al 2015] and in cardiomyocyte development [Rouleau et al 2011].

Mechanism of disease causation. Variants in *TP63* lead to three major phenotypes: ectodermal dysplasia, orofacial clefting (OFC), and split-hand/foot malformation (SHFM) [Celli et al 1999]. Heterozygous *TP63* variants have been associated with five different syndromes with overlapping phenotypic features: ectrodactyly, ectodermal dysplasia, cleft lip/palate syndrome (EEC), ankyloblepharon-ectodermal defects-cleft lip/palate (AEC) syndrome, Rapp-Hodgkin syndrome (RHS), acro-dermo-ungual-lacrimal-tooth (ADULT) syndrome, and limb-mammary syndrome (LMS). Rare *TP63* variants are causative for OFC with variable mild ectodermal features (OFC8) [Leoyklang et al 2006], and for nonsyndromic SHFM4.

A broad spectrum of different heterozygous variants has been reported in *TP63*, leading to the developmental disorders stated above. The vast majority of variants give rise to amino acid substitutions. A striking genotype-phenotype correlation for *TP63* missense variants is apparent in EEC and AEC syndrome / RHS [Rinne et al 2006a, Figure 1]. Variants underlying EEC and AEC syndrome / RHS exert dominant-negative effects by interfering with normal p63 proteins in dimeric and tetrameric complexes. Variants in LMS affect yet another region of the p63 protein, and probably have dominant-negative effects. Causative variants in ADULT syndrome typically give rise to amino acid substitution of arginine 337 in the DNA-binding domain (DBD) but appear to exert gain-of-function effects, in contrast to dominant-negative DBD missense variants seen in EEC syndrome. Deletions encompassing large parts of *TP63* generating loss-of-function alleles are associated with OFC8 [Khandelwal et al 2019].

Notable *TP63* variants. Figure 1 demonstrates typical and common *TP63* pathogenic variants identified with the various phenotypes.

Chapter Notes

Author Notes

[Dr Sutton's web page](#)

[Dr van Bokhoven's web page](#)

Acknowledgments

The authors would like to thank the National Foundation for Ectodermal Dysplasias and Executive Director Mary Fete, who organized the International Research Symposium on AEC syndrome, and all the individuals and families who participated in the research that contributed to this review. Additionally, we would like to express our gratitude to Dr John Carey and the *American Journal of Medical Genetics* for publishing these research results in a unified special issue of the journal.

Author History

Alanna F Bree, MD; Dermatology Specialists of Houston (2010-2015)

V Reid Sutton, MD (2010-present)

Hans van Bokhoven, PhD (2010-present)

Revision History

- 1 April 2021 (ha) Comprehensive update posted live
- 5 December 2019 (vrs) Revision: correction to SHFM4
- 6 August 2015 (me) Comprehensive update posted live
- 8 June 2010 (me) Review posted live
- 2 February 2010 (vrs) Original submission

References

Literature Cited

- Amiel J, Bougeard G, Francannet C, Raclin V, Munnich A, Lyonnet S, Frebourg T. TP63 gene mutation in ADULT syndrome. *Eur J Hum Genet.* 2001;9:642–5. PubMed PMID: 11528512.
- Aradhya S, Lewis R, Bonaga T, Nwokekeh N, Stafford A, Boggs B, Hruska K, Smaoul N, Compton JG, Richard G, Suchy S. Exon-level array CGH in a large clinical cohort demonstrates increased sensitivity of diagnostic testing for Mendelian disorders. *Genet Med.* 2012;14:594–603. PubMed PMID: 22382802.
- Barrow LL, van Bokhoven H, Daack-Hirsch S, Andersen T, van Beersum SE, Gorlin R, Murray JC. Analysis of the p63 gene in classical EEC syndrome, related syndromes, and non-syndromic orofacial clefts. *J Med Genet.* 2002;39:559–66. PubMed PMID: 12161593.
- Basha M, Demeer B, Revencu N, Helaers R, Theys S, Bou Saba S, Boute O, Devauchelle B, Francois G, Bayet B, Vikkula M. Whole exome sequencing identifies mutations in 10% of patients with familial non-syndromic cleft lip and/or palate in genes mutated in well-known syndromes. *J Med Genet.* 2018;55:449–58. PubMed PMID: 29500247.
- Buss PW, Hughes HE, Clarke A. Twenty-four cases of the EEC syndrome: clinical presentation and management. *J Med Genet.* 1995;32:716–23. PubMed PMID: 8544192.
- Cadioux-Dion M, Safina NP, Engleman K, Saunders C, Repnikova E, Rajc N, Canty K, Farrow E, Miller N, Zellmer L, Thiffault I. Novel heterozygous pathogenic variants in CHUK in a patient with AEC-like phenotype, immune deficiencies and 1q21.1 microdeletion syndrome: a case report. *BMC Med Genet.* 2018;19:41. PubMed PMID: 29523099.
- Cambiaghi S, Tadini G, Barbareschi M, Menni S, Caputo R. Rapp-Hodgkin syndrome and AEC syndrome: Are they the same entity? *Br J Dermatol.* 1994;130:97–101. PubMed PMID: 8305327.
- Cefalù S, Lena AM, Vojtesek B, Musarò A, Rossi A, Melino G, Candi E. Tap63gamma is required for the late stages of myogenesis. *Cell Cycle.* 2015;14:894–901. PubMed PMID: 25790093.
- Celli J, Duijf P, Hamel BC, Bamshad M, Kramer B, Smits AP, Newbury-Ecob R, Hennekam RC, Van Buggenhout G, van Haeringen A, Woods CG, van Essen AJ, de Waal R, Vriend G, Haber DA, Yang A, McKeon F, Brunner HG, van Bokhoven H. Heterozygous germline mutations in the p53 homolog p63 are the cause of EEC syndrome. *Cell.* 1999;99:143–53. PubMed PMID: 10535733.
- Cole P, Hatef DA, Kaufman Y, Magruder A, Bree A, Friedman E, Sindwani R, Hollier LH Jr. Facial clefting and oroauditory pathway manifestations in ankyloblepharon-ectodermal defects-cleft lip/palate syndrome. *Am J Med Genet.* 2009;149A:1910–5. PubMed PMID: 19697430.

- de Mollerat XJ, Gurrieri F, Morgan CT, Sangiorgi E, Everman DB, Gaspari P, Amiel J, Bamshad MJ, Lyle R, Blouin JL, Allanson JE, Le Marec B, Wilson M, Braverman NE, Radhakrishna U, Delozier-Blanchet C, Abbott A, Elghouzzi V, Antonarakis S, Stevenson RE, Munnich A, Neri G, Schwartz CE. A genomic rearrangement resulting in a tandem duplication is associated with split hand-split foot malformation 3 (SHFM3) at 10q24. *Hum Mol Genet.* 2003;12:1959–71. PubMed PMID: 12913067.
- Deutsch GB, Zielonka EM, Coutandin D, Weber TA, Schäfer B, Hannewald J, Luh LM, Durst FG, Ibrahim M, Hoffmann J, Niesen FH, Sentürk A, Kunkel H, Brutschy B, Schleiff E, Knapp S, Acker-Palmer A, Grez M, McKeon F, Dötsch V. DNA damage in oocytes induces a switch of the quality control factor TAp63 α from dimer to tetramer. *Cell.* 2011;144:566–76. PubMed PMID: 21335238.
- Dishop MK, Bree AF, Hicks MJ. Pathologic changes of skin and hair in ankyloblepharon-ectodermal defects-cleft lip/palate (AEC) syndrome. *Am J Med Genet.* 2009;149A:1935–41. PubMed PMID: 19697429.
- Elliott AM, Evans JA. Genotype-phenotype correlations in mapped split hand foot malformation (SHFM) patients. *Am J Med Genet A.* 2006;140:1419–27. PubMed PMID: 16688749.
- Enriquez A, Krivanek M, Flöttmann R, Peters H, Wilson M. Recurrence of split hand/foot malformation, cleft lip/palate, and severe urogenital abnormalities due to germline mosaicism for TP63 mutation. *Am J Med Genet A.* 2016;170:2372–6. PubMed PMID: 27351625.
- Farrington F, Lausten L. Oral findings in ankyloblepharon-ectodermal dysplasia-cleft lip/palate (AEC) syndrome. *Am J Med Genet.* 2009;149A:1907–9. PubMed PMID: 19681142.
- Ferstl P, Wohlfart S, Schneider H. Sweating ability of patients with P63-associated syndromes. *Eur J Pediatr.* 2018;177:1727–31. PubMed PMID: 30088137.
- Julapalli MR, Scher RK, Sybert VP, Siegfried EC, Bree AF. Dermatologic findings of ankyloblepharon-ectodermal defects-cleft lip/palate (AEC) syndrome. *Am J Med Genet A.* 2009;149A:1900–6. PubMed PMID: 19681128.
- Khandelwal KD, van den Boogaard MH, Mehrem SL, Gebel J, Fagerberg C, van Beusekom E, van Binsbergen E, Topaloglu O, Steehouwer M, Gilissen C, Ishorst N, van Rooij IALM, Roeleveld N, Christensen K, Schoenaers J, Bergé S, Murray JC, Hens G, Devriendt K, Ludwig KU, Mangold E, Hoischen A, Zhou H, Dötsch V, Carels CEL, van Bokhoven H. Deletions and loss-of-function variants in TP63 associated with orofacial clefting. *Eur J Hum Genet.* 2019;27:1101–12. PubMed PMID: 30850703.
- Lane MM, Dalton WT 3rd, Sherman SA, Bree AF, Czyzewski DI. Psychosocial functioning and quality of life in children and families affected by AEC syndrome. *Am J Med Genet A.* 2009;149A:1926–34. PubMed PMID: 19504609.
- Leoyklang P, Siriwan P, Shotelersuk V. A mutation of the p63 gene in non-syndromic cleft lip. *J Med Genet.* 2006;43:e28. PubMed PMID: 16740912.
- McGrath JA, Duijf PH, Doetsch V, Irvine AD, de Waal R, Vanmolokot KR, Wessagowit V, Kelly A, Atherton DJ, Griffiths WA, Orlow SJ, van Haeringen A, Ausems MG, Yang A, McKeon F, Bamshad MA, Brunner HG, Hamel BC, van Bokhoven H. Hay-Wells syndrome is caused by heterozygous missense mutations in the SAM domain of TP63. *Hum Mol Genet.* 2001;10:221–9. PubMed PMID: 11159940.
- Monti P, Russo D, Bocciardi R, Foggetti G, Menichini P, Divizia MT, Lerone M, Graziano C, Wischmeijer A, Viadiu H, Ravazzolo R, Inga A, Fronza G. EEC- and ADULT-associated TP63 mutations exhibit functional heterogeneity toward P63 responsive sequences. *Hum Mutat.* 2013;34:894–904. PubMed PMID: 23463580.
- Motil KJ, Fete TJ. Growth, nutritional, and gastrointestinal aspects of ankyloblepharon-ectodermal defect-cleft lip and/or palate (AEC) syndrome. *Am J Med Genet A.* 2009;149A:1922–5. PubMed PMID: 19676058.
- O'Quinn JR, Hennekam RC, Jorde LB, Bamshad M. Syndromic ectrodactyly with severe limb, ectodermal, urogenital, and palatal defects maps to chromosome 19. *Am J Hum Genet.* 1998;62:130–5. PubMed PMID: 9443880.

- Pashayan HM, Pruzansky S, Solomon L. The EEC syndrome. Report of six patients. *Birth Defects Orig Artic Ser.* 1974;10:105–27. PubMed PMID: 4425508.
- Restelli M, Lopardo T, Lo Iacono N, Garaffo G, Conte D, Rustighi A, Napoli M, Del Sal G, Perez-Morga D, Costanzo A, Merlo GR, Guerrini L. DLX5, FGF8 and Pin1 isomerase control $\Delta Np63\alpha$ protein stability during limb development: a regulatory loop at the basis of the SHFM and EEC congenital malformations. *Hum Mol Genet.* 2014;23:3830–42. PubMed PMID: 24569166.
- Richards S, Aziz N, Bale S, Bick D, Das S, Gastier-Foster J, Grody WW, Hegde M, Lyon E, Spector E, Voelkerding K, Rehm HL, et al. Standards and guidelines for the interpretation of sequence variants: a joint consensus recommendation of the American College of Medical Genetics and Genomics and the Association for Molecular Pathology. *Genet Med.* 2015;17:405–24. PubMed PMID: 25741868.
- Rinne T, Brunner HG, van Bokhoven H. p63-associated disorders. *Cell Cycle.* 2007;6:262–8. PubMed PMID: 17224651.
- Rinne T, Clements SE, Lamme E, Duijf PH, Bolat E, Meijer R, Scheffer H, Rosser E, Tan TY, McGrath JA, Schalkwijk J, Brunner HG, Zhou H, van Bokhoven H. A novel translation re-initiation mechanism for the p63 gene revealed by amino-terminal truncating mutations in Rapp-Hodgkin/Hay-Wells-like syndromes. *Hum Mol Genet.* 2008;17:1968–77. PubMed PMID: 18364388.
- Rinne T, Hamel B, van Bokhoven H, Brunner HG. Pattern of p63 mutations and their phenotypes--update. *Am J Med Genet A.* 2006a;140:1396–406. PubMed PMID: 16691622.
- Rinne T, Spadoni E, Kjaer KW, Danesino C, Larizza D, Kock M, Huoponen K, Savontaus M-L, Aaltonen M, Duijf P, Brunner HG, Penttinen M, van Bokhoven H. Delineation of the ADULT syndrome phenotype due to arginine 298 mutations of the p63 gene. *Eur J Hum Genet.* 2006b;14:904–10. PubMed PMID: 16724007.
- Rouleau M, Medawar A, Hamon L, Shvitiel S, Wolchinsky Z, Zhou H, De Rosa L, Candi E, de la Forest Divonne S, Mikkola ML, van Bokhoven H, Missero C, Melino G, Puc at M, Aberdam D. TAp63 is important for cardiac differentiation of embryonic stem cells and heart development. *Stem Cells.* 2011;29:1672–83. PubMed PMID: 21898690.
- Sethi I, Romano R-A, Gluck C, Smalley K, Vojtesek B, Buck MJ, Sinha S. A global analysis of the complex landscape of isoforms and regulatory networks of p63 in human cells and tissues. *BMC Genomics.* 2015;16:584. PubMed PMID: 26251276.
- Shalom-Feuerstein R, Serror L, Aberdam E, M uller FJ, van Bokhoven H, Wiman KG, Zhou H, Aberdam D, Petit I. Impaired epithelial differentiation of induced pluripotent stem cells from ectodermal dysplasia-related patients is rescued by the small compound APR-246/PRIMA-1MET. *Proc Natl Acad Sci U S A.* 2013;110:2152–6. PubMed PMID: 23355677.
- Siegfried E, Bree A, Fete M, Sybert V. Skin erosions and wound healing in ankyloblepharon-ectodermal defect – cleft lip and/or palate. *Arch Dermatol.* 2005;141:1591–4. PubMed PMID: 16365264.
- Soares E, Zhou H. Master regulatory role of p63 in epidermal development and disease. *Cell Mol Life Sci.* 2018;75:1179–90. PubMed PMID: 29103147.
- Spranger M, Schapera J. Anomalous inheritance in a kindred with split hand, split foot malformation. *Eur J Pediatr.* 1988;147:202–5. PubMed PMID: 3366140.
- Stenson PD, Mort M, Ball EV, Evans K, Hayden M, Heywood S, Hussain M, Phillips AD, Cooper DN. The Human Gene Mutation Database: towards a comprehensive repository of inherited mutation data for medical research, genetic diagnosis and next-generation sequencing studies. *Hum Genet.* 2017;136:665–77. PubMed PMID: 28349240.
- Sutton VR, Plunkett K, Dang DX, Lewis RA, Bree AF, Bacino CA. Craniofacial and anthropometric phenotype in ankyloblepharon-ectodermal defects-cleft lip/palate syndrome (Hay-Wells syndrome) in a cohort of 17 patients. *Am J Med Genet A.* 2009;149A:1916–21. PubMed PMID: 19676059.

- Terrinoni A, Serra V, Bruno E, Strasser A, Valente E, Flores ER, van Bokhoven H, Lu X, Knight RA, Melino G. Role of p63 and the Notch pathway in cochlea development and sensorineural deafness. *Proc Natl Acad Sci USA*. 2013;110:7300–5. PubMed PMID: 23589895.
- Ugur SA, Tolun A. Homozygous WNT10b mutation and complex inheritance in Split-Hand/Foot Malformation. *Hum Mol Genet*. 2008;17:2644–53. PubMed PMID: 18515319.
- van Bokhoven H, Hamel BC, Bamshad M, Sangiorgi E, Gurrieri F, Duijf PH, Vanmolkot KR, van Beusekom E, van Beersum SE, Celli J, Merkx GF, Tenconi R, Fryns JP, Verloes A, Newbury-Ecob RA, Raas-Rotschild A, Majewski F, Beemer FA, Janecke A, Chitayat D, Crisponi G, Kayserili H, Yates JR, Neri G, Brunner HG. p63 Gene mutations in eec syndrome, limb-mammary syndrome, and isolated split hand-split foot malformation suggest a genotype-phenotype correlation. *Am J Hum Genet*. 2001;69:481–92. PubMed PMID: 11462173.
- van Bokhoven H, Jung M, Smits AP, van Beersum S, Rüschen-dorf F, van Steensel M, Veenstra M, Tuerlings JH, Mariman EC, Brunner HG, Wienker TF, Reis A, Ropers HH, Hamel BC. Limb mammary syndrome: a new genetic disorder with mammary hypoplasia, ectrodactyly, and other Hand/Foot anomalies maps to human chromosome 3q27. *Am J Hum Genet*. 1999;64:538–46. PubMed PMID: 9973291.
- van Zelst-Stams WA, van Steensel MA. A novel TP63 mutation in family with ADULT syndrome presenting with eczema and hypothelia. *Am J Med Genet A*. 2009;149A:1558–60. PubMed PMID: 19530185.
- Zarnegar BJ, Webster DE, Lopez-Pajares V, Vander Stoep Hunt B, Qu K, Yan KJ, Berk DR, Sen GL, Khavari PA. Genomic profiling of a human organotypic model of AEC syndrome reveals ZNF750 as an essential downstream target of mutant TP63. *Am J Hum Genet*. 2012;91:435–43. PubMed PMID: 22922031.

License

GeneReviews® chapters are owned by the University of Washington. Permission is hereby granted to reproduce, distribute, and translate copies of content materials for noncommercial research purposes only, provided that (i) credit for source (<http://www.genereviews.org/>) and copyright (© 1993-2024 University of Washington) are included with each copy; (ii) a link to the original material is provided whenever the material is published elsewhere on the Web; and (iii) reproducers, distributors, and/or translators comply with the [GeneReviews® Copyright Notice and Usage Disclaimer](#). No further modifications are allowed. For clarity, excerpts of GeneReviews chapters for use in lab reports and clinic notes are a permitted use.

For more information, see the [GeneReviews® Copyright Notice and Usage Disclaimer](#).

For questions regarding permissions or whether a specified use is allowed, contact: admasst@uw.edu.