



NKX2-1-Related Disorders

Neepa Jayant Patel, MD¹ and Joseph Jankovic, MD²

Created: February 20, 2014; Updated: June 29, 2023.

Summary

Clinical characteristics

NKX2-1-related disorders range from benign hereditary chorea (BHC) to choreoathetosis, congenital hypothyroidism, and neonatal respiratory distress syndrome (also known as brain-lung-thyroid syndrome). Childhood-onset chorea, the hallmark feature of *NKX2-1*-related disorders, may or may not be associated with pulmonary disease or congenital hypothyroidism. Age of onset of chorea varies from early infancy (most commonly) to late childhood or adolescence and may progress into the second decade, after which it remains static or (rarely) remits. Pulmonary disease, the second most common manifestation, can include respiratory distress syndrome in neonates, interstitial lung disease in young children, and pulmonary fibrosis in older individuals. The risk for pulmonary carcinoma is increased in young adults with *NKX2-1*-related disorders. Thyroid dysfunction, occurring as a result of thyroid dysgenesis, can present as congenital or compensated hypothyroidism. In one review, 50% of affected individuals had the full brain-lung-thyroid syndrome, 30% had brain and thyroid involvement only, and 13% had chorea only.

Diagnosis/testing

The diagnosis of *NKX2-1*-related disorders is established in a proband with a heterozygous pathogenic variant in *NKX2-1* identified by molecular genetic testing.

Management

Treatment of manifestations: Tetrabenazine, deutetrabenazine, or valbenazine starting at low doses and gradually increasing to control chorea. Levodopa, reported to improve chorea in children with gait abnormalities (including frequent falls), can be considered as second-line therapy for the treatment of chorea and as first-line therapy in children with gait impairment. Pulmonary manifestations are treated per standard recommendations including respiratory support as needed during the neonatal period, RSV vaccination in infancy, and early treatment of asthma and interstitial lung disease. Standard treatment for pulmonary carcinoma. Thyroid

Author Affiliations: 1 Associate Professor, Division of Movement Disorders, Department of Neurological Sciences, RUSH University Medical Center, Chicago, Illinois; Email: neepa_patel@rush.edu. 2 Professor of Neurology, Distinguished Chair in Movement Disorders, Director, Parkinson's Disease Center and Movement Disorders Clinic, Department of Neurology, Baylor College of Medicine, Houston, Texas; Email: josephj@bcm.edu.

replacement therapy for hypothyroidism. Early intervention and physical therapy for motor and gait abnormalities. Standard treatments for neuropsychiatric issues.

Surveillance: Annual neurologic evaluation or more frequently as needed, depending on symptoms. Annual pulmonary evaluations including pulmonary function tests and chest x-ray or chest CT scan to screen for pulmonary malignancy. Annual endocrine evaluations including thyroid function tests (serum thyroxine and thyroid-stimulating hormone) and physical examination (including thyroid palpation) to screen for thyroid cancer.

Agents/circumstances to avoid: Dopamine receptor blockers due to the risk of developing tardive dyskinesia, which can worsen choreiform movements.

Evaluation of relatives at risk: Testing at-risk relatives prenatally or as soon as possible after birth for early identification and treatment of infants at risk for congenital hypothyroidism (and associated neurodevelopmental consequences) as well as pulmonary disease.

Pregnancy management: Prior to pregnancy or early in gestation, assess the safety of medications used for the treatment of chorea.

Genetic counseling

NKX2-1-related disorders are inherited in an autosomal dominant manner. Most individuals with an *NKX2-1*-related disorder have an affected parent. Each child of an individual with an *NKX2-1*-related disorder has a 50% chance of inheriting the pathogenic variant. Once the *NKX2-1* pathogenic variant has been identified in an affected family member, prenatal testing for a pregnancy at increased risk is possible.

GeneReview Scope

NKX2-1-Related Disorders: Included Phenotypes ¹

- Benign hereditary chorea (BHC)
- Choreoathetosis, congenital hypothyroidism, and neonatal respiratory distress syndrome (collectively also known as brain-lung-thyroid syndrome)

For synonyms and outdated names see Nomenclature.

1. For other genetic causes of these phenotypes see Differential Diagnosis.

Diagnosis

Suggestive Findings

NKX2-1-related disorders **should be suspected** in probands with the following clinical and laboratory findings and family history.

Clinical findings

- Infancy- or childhood-onset non-progressive chorea that may or may not be associated with:
 - Mild neurologic symptoms including axial hypotonia, ataxia, developmental delays, impaired mobility of upper and lower limbs;
 - Congenital hypothyroidism;
 - Respiratory distress syndrome;

OR

- A history of congenital hypothyroidism and:

- Neurologic manifestations including hypotonia, neurodevelopmental delay, seizures; and/or
- Respiratory dysfunction including interstitial lung disease in children.

Laboratory findings

- Congenital hypothyroidism (i.e., low thyroid hormone production with elevated thyroid-stimulating hormone)
- Compensated hypothyroidism (i.e., low-to-normal thyroid hormone production with elevated thyroid-stimulating hormone)

Family history is consistent with autosomal dominant inheritance (e.g., affected males and females in multiple generations). Absence of a known family history does not preclude the diagnosis.

Establishing the Diagnosis

The diagnosis of an *NKX2-1*-related disorder **is established** in a proband with suggestive findings and a heterozygous pathogenic (or likely pathogenic) variant in *NKX2-1* identified by molecular genetic testing [Inzelberg et al 2011] (see Table 1).

Note: (1) Per ACMG/AMP variant interpretation guidelines, the terms "pathogenic variant" and "likely pathogenic variant" are synonymous in a clinical setting, meaning that both are considered diagnostic and can be used for clinical decision making [Richards et al 2015]. Therefore, reference to "pathogenic variant" in this section is understood to include any likely pathogenic variant. (2) Identification of a heterozygous *NKX2-1* variant of uncertain significance does not establish or rule out the diagnosis.

Molecular genetic testing approaches can include a combination of **gene-targeted testing** (single-gene testing, multigene panel) and **comprehensive genomic testing** (chromosomal microarray analysis, exome sequencing, genome sequencing). Gene-targeted testing requires that the clinician determine which gene(s) are likely involved (see Option 1), whereas genomic testing does not (see Option 2).

Option 1

When the phenotypic and laboratory findings suggest the diagnosis of an *NKX2-1*-related disorder, molecular genetic testing approaches can include **single-gene testing** or a **multigene panel**.

- **Single-gene testing.** Sequence analysis of *NKX2-1* is performed first to detect missense, nonsense, and splice site variants and small intragenic deletions/insertions. Note: Depending on the sequencing method used, single-exon, multiexon, or whole-gene deletions/duplications may not be detected. If no variant is detected by the sequencing method used, the next step is to perform gene-targeted deletion/duplication analysis to detect exon and whole-gene deletions or duplications.
- **A multigene panel** that includes *NKX2-1* and other genes of interest (see Differential Diagnosis) is most likely to identify the genetic cause of the condition while limiting identification of variants of uncertain significance and pathogenic variants in genes that do not explain the underlying phenotype. Note: (1) The genes included in the panel and the diagnostic sensitivity of the testing used for each gene vary by laboratory and are likely to change over time. (2) Some multigene panels may include genes not associated with the condition discussed in this *GeneReview*. (3) In some laboratories, panel options may include a custom laboratory-designed panel and/or custom phenotype-focused exome analysis that includes genes specified by the clinician. (4) Methods used in a panel may include sequence analysis, deletion/duplication analysis, and/or other non-sequencing-based tests.

For an introduction to multigene panels click [here](#). More detailed information for clinicians ordering genetic tests can be found [here](#).

Option 2

When the diagnosis of an *NKX2-1*-related disorder has not been considered because an individual has atypical phenotypic features, **comprehensive genomic testing** does not require the clinician to determine which gene is likely involved. **Exome sequencing** is most commonly used; **genome sequencing** is also possible. To date, the majority of reported *NKX2-1* pathogenic variants are within the coding region and are likely to be identified on exome sequencing.

For an introduction to comprehensive genomic testing click [here](#). More detailed information for clinicians ordering genomic testing can be found [here](#).

Chromosomal microarray analysis (CMA) uses oligonucleotide or SNP arrays to detect genome-wide large deletions/duplications (including *NKX2-1*) that cannot be detected by sequence analysis (see Table 1). CMA is recommended for the evaluation of childhood-onset chorea if multigene panel and comprehensive genomic testing are negative.

For an introduction to CMA click [here](#). More detailed information for clinicians ordering genetic tests can be found [here](#).

Table 1. Molecular Genetic Testing Used in *NKX2-1*-Related Disorders

Gene ¹	Method	Proportion of Probands/Families with a Pathogenic Variant ² Detectable by Method	
		Probands	Families
<i>NKX2-1</i>	Sequence analysis ³	82% ⁴	73% ⁴
	Deletion/duplication analysis ⁵	16% ^{4, 6}	21% ^{4, 6}
	CMA ⁷	2% ^{4, 6, 8}	6% ^{4, 6, 8}

1. See Table A. Genes and Databases for chromosome locus and protein.

2. See Molecular Genetics for information on variants detected in this gene.

3. Sequence analysis detects variants that are benign, likely benign, of uncertain significance, likely pathogenic, or pathogenic. Variants may include small intragenic deletions/insertions and missense, nonsense, and splice site variants; typically, exon or whole-gene deletions/duplications are not detected. For issues to consider in interpretation of sequence analysis results, click [here](#).

4. Data derived from the subscription-based professional view of Human Gene Mutation Database [Stenson et al 2020]

5. Gene-targeted deletion/duplication analysis detects intragenic deletions or duplications. Methods used may include a range of techniques such as quantitative PCR, long-range PCR, multiplex ligation-dependent probe amplification (MLPA), and a gene-targeted microarray designed to detect single-exon deletions or duplications. Gene-targeted deletion/duplication testing will detect deletions ranging from a single exon to the whole gene; however, breakpoints of large deletions and/or deletion of adjacent genes may not be detected by these methods. Exome and genome sequencing may be able to detect deletions/duplications using breakpoint detection or read depth; however, sensitivity can be lower than gene-targeted deletion/duplication analysis.

6. Partial and whole-gene deletions have been reported [Devos et al 2006, Teissier et al 2012, Invernizzi et al 2018].

7. Chromosomal microarray analysis (CMA) uses oligonucleotide or SNP arrays to detect genome-wide large deletions/duplications (including *NKX2-1*) that cannot be detected by sequence analysis. The ability to determine the size of the deletion/duplication depends on the type of microarray used and the density of probes in the 14q13.3 region.

8. Several large contiguous deletions have been identified in individuals with clinical features of *NKX2-1*-related disorders, including an individual with choreiform movements, neonatal respiratory distress, and hypothyroidism and a 3.5-Mb deletion adjacent to but not interrupting *NKX2-1* [Barnett et al 2012]. A large 14q12-q21.1 deletion that included *NKX2-1* was reported in a newborn with respiratory distress syndrome, hypothyroidism, and seizures [Villamil-Osorio et al 2021]. A deletion in a noncoding region downstream of *NKX2-1* was also identified in three unrelated families with benign hereditary chorea [Liao et al 2021]. See Molecular Genetics.

Clinical Characteristics

Clinical Description

NKX2-1-related disorders include benign hereditary chorea (BHC) and choreoathetosis, congenital hypothyroidism, and neonatal respiratory distress syndrome (collectively known as brain-lung-thyroid syndrome). Individuals can have one or more of several features associated with this spectrum (see Figure 1). To date, more than 120 individuals have been identified with a pathogenic variant in *NKX2-1* [Gras et al 2012, Peall & Kurian 2015, Kharbanda et al 2017]. In a review of 46 affected individuals, Carré et al [2009] found that 50% had the full brain-lung-thyroid syndrome, 30% had only brain and thyroid involvement, and 13% had isolated chorea. The following description of the phenotypic features associated with this condition is based on these reports.

Table 2. *NKX2-1*-Related Disorders: Frequency of Select Features

System ¹	Feature	% of Persons w/Feature
Neurologic	Benign hereditary chorea	Most common neurologic feature
	Hypotonia, motor delays, incoordination	Common in infants/neonates; typically resolves in childhood/adulthood
	Other movement abnormalities incl myoclonus, dystonia, intention tremor, &/or ataxia	Rare
Pulmonary	Neonatal respiratory distress	~50%
Thyroid	Congenital hypothyroidism ²	~67%

Based on Gras et al [2012], Peall et al [2014], Kharbanda et al [2017]

1. When all three organ systems are involved, this is also known as "brain-lung-thyroid syndrome" (see Figure 1).

2. The neurodevelopmental complications of congenital hypothyroidism can be prevented with thyroid hormone replacement in the neonatal period to prevent early neurodevelopmental consequences of untreated hypothyroidism (see Management).

Neurologic Manifestations

Chorea, an involuntary, random, irregular, jerk-like, and continuous movement, is a classic early finding in BHC and other *NKX2-1*-related disorders. The onset of chorea generally occurs during one of the following time periods:

- Early infancy or within the first year of life (most common)
- Late childhood or adolescence

Chorea progresses into the second decade, after which it remains static or may spontaneously remit [Kleiner-Fisman et al 2003, Peall & Kurian 2015]. Although originally referred to as "benign" hereditary chorea, the neurologic manifestations of *NKX2-1*-related disorders can be quite disabling, due to chorea as well as gait and balance abnormalities, hypotonia, and a variety of other motor and non-motor manifestations [Parnes et al 2018].

Chorea typically involves all body regions (e.g., face, tongue, neck, trunk, limbs) and may be associated with motor and gait abnormalities, possibly secondary to the choreiform movements. The movements are jerk-like and spread randomly from one body part to another; they often worsen with stress and may disappear with sleep. Children with BHC may fall frequently [Kleiner-Fisman et al 2003]. Although affected children may be delayed in walking, persistent gait abnormalities are rare [McMichael et al 2013]. Rosati et al [2015] described two unrelated children presenting with spontaneous falls without loss of consciousness preceding the development of chorea.

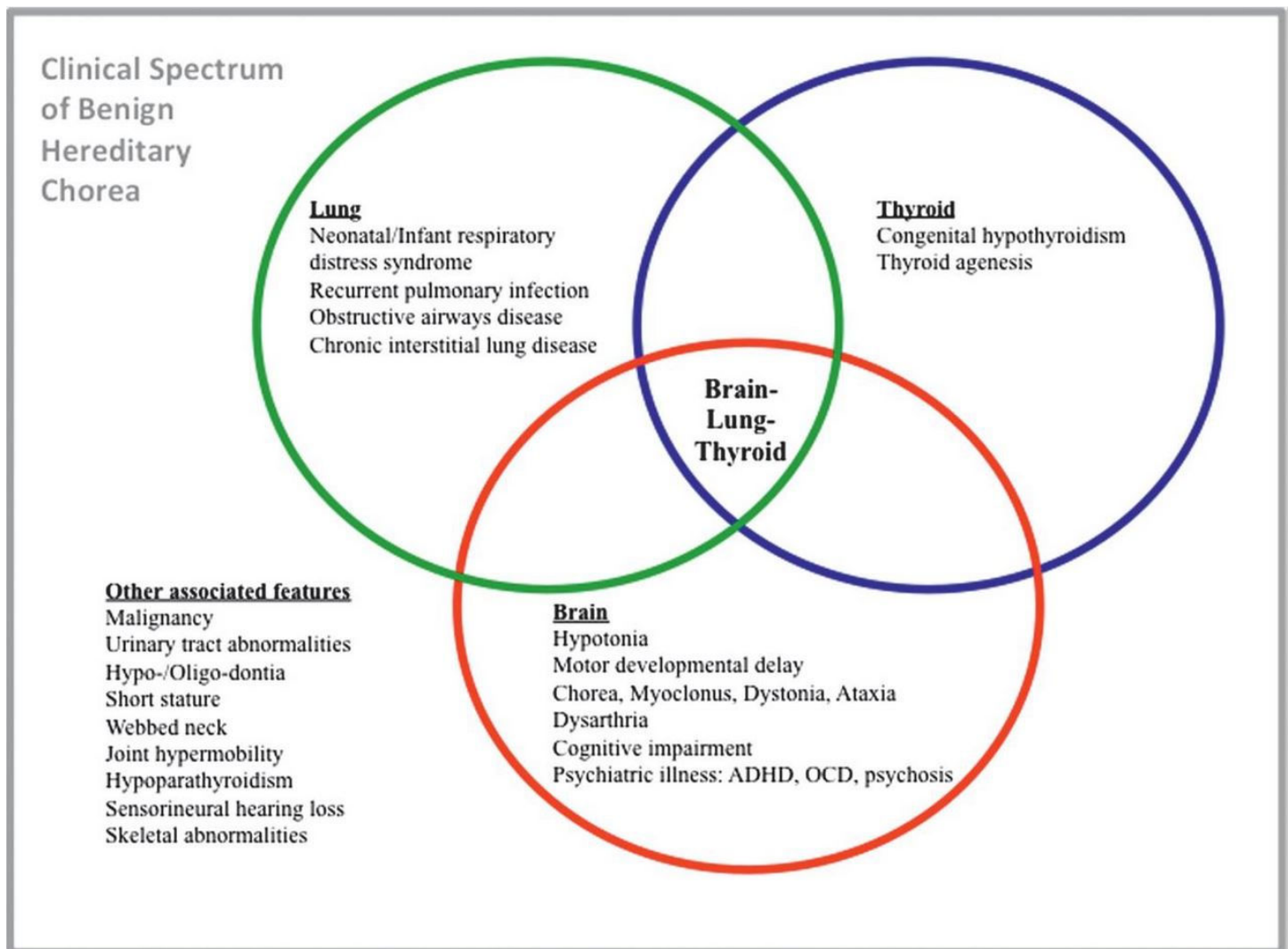


Figure 1. Phenotypic spectrum of *NKX2-1*-related disorders. *NKX2-1*-related disorders may manifest as abnormalities in a single organ system or as any combination of brain, thyroid, and lung involvement. "Brain-lung-thyroid syndrome" refers to involvement of all three organ systems. Other associated features increasingly recognized in individuals with *NKX2-1*-related disorders are listed outside the rings. Note: Structural cardiac anomalies have also been reported (see Clinical Description).

Reprinted from Peall & Kurian [2015]

The prevalence of chorea in *NKX2-1*-related disorders is unknown. In one study, all 28 affected individuals from 13 families with a heterozygous *NKX2-1* pathogenic variant had chorea and hypotonia [Gras et al 2012].

However, in a retrospective study of 21 individuals with *NKX2-1*-related disorders presenting with pulmonary dysfunction, at least two unrelated individuals and three members of one family did not have any neurologic symptoms [Hamvas et al 2013].

Other less common neurologic manifestations

- Hypotonia, incoordination, and motor delays, which are common during the neonatal period / infancy but rarely reported in childhood/adulthood [Peall et al 2014, Veneziano et al 2014]
- Myoclonus, dystonia, and/or ataxia [Peall et al 2014, de Gusmao et al 2015]
- Intention tremor [Peall et al 2014]
- Dysarthria [Peall et al 2014]
- Restless leg syndrome [Iodice et al 2019]

- Neurocognitive changes, including learning difficulties and reduced working memory and attention [Gras et al 2012, Peall et al 2014, Parnes et al 2018, Graziola et al 2021]
- Seizures [Villamil-Osorio et al 2021]

In one report, two sibs initially diagnosed with ataxic dyskinetic cerebral palsy were later found to have a pathogenic variant in *NKX2-1* [McMichael et al 2013].

Neuropsychiatric manifestations including attention-deficit/hyperactivity disorder have been reported [Gras et al 2012]. Although psychiatric disorders are rare in individuals with an *NKX2-1* pathogenic variant, schizophrenia [Glik et al 2008], postpartum psychosis [Salvatore et al 2010], and obsessive-compulsive disorder [Peall et al 2014] have been reported.

Neuroimaging is usually normal. Structural brain abnormalities have been rarely reported, including abnormal sella turcica [Krude et al 2002, Balicza et al 2018], agenesis of the corpus callosum [Carré et al 2009], cavum septum pellucidum, and microcephaly [Iwatani et al 2000]. Hypoplastic pallidum and lack of differentiation of medial and lateral components of the pallidum were reported in a single individual, and bilateral pallidal signal hyperintensities on T₂-weighted MRI were described in another individual [Kleiner-Fisman & Lang 2007]. An expanding pituitary cyst was reported in two related individuals with a novel *NKX2-1* pathogenic variant [Veneziano et al 2014]. Chiari I malformation was also reported in one female at age 24 months [Gonçalves et al 2019].

Single-photon emission computed tomography (SPECT) has demonstrated reduced cerebral blood flow to the basal ganglia bilaterally, and more specifically to the caudate nuclei, in three affected individuals [Uematsu et al 2012]. Subtle abnormalities in presynaptic dopamine transporter function utilizing positron emission tomography (PET) imaging have also been reported in two affected individuals [Konishi et al 2013].

Neuropathology. Autopsies of two individuals with *NKX2-1*-related disorders did not identify gross or microscopic abnormalities of the brain, but showed reduced number of striatal and neocortical interneurons consistent with a defect in neuronal migration and supporting the theory that these disorders are due to abnormalities in brain development rather than neurodegeneration [Kleiner-Fisman et al 2003].

Pulmonary Manifestations

Pulmonary dysfunction is the second most common manifestation of *NKX2-1*-related disorders. In a meta-analysis of 29 published reports of *NKX2-1*-related disorders, up to 49% (61/124) of affected individuals had pulmonary manifestations of varying severity [Gras et al 2012]. Clinical presentation and course vary among affected individuals.

- Respiratory distress syndrome (RDS) with or without pulmonary hypertension is most common in the neonatal period.
- Neuroendocrine cell hyperplasia, a distinct form of childhood interstitial lung disease (ILD), can be present in infancy; it typically improves with age [Young et al 2013]. ILD can occur between the ages of four months to seven years.
- Pulmonary fibrosis can occur in older individuals [Hamvas et al 2013].

The highest risk for respiratory distress is in the neonatal period. Affected infants often require mechanical ventilation [Carré et al 2009]. Although usually not fatal, *NKX2-1*-related disorders have resulted in death from respiratory failure in three infants in the immediate postnatal period to date [Maquet et al 2009, Kleinlein et al 2011, Gillett et al 2013]. However, in most infants, respiratory function typically improves over time [Young et al 2013].

As a result of pulmonary involvement, individuals with *NKX2-1*-related disorders are at increased risk for recurrent pulmonary infections and chronic interstitial lung disease [Carré et al 2009, Inzelberg et al 2011, Peca

et al 2011]. High-resolution CT scan of six children with pathogenic variants in *NKX2-1* identified ground-glass opacities and pulmonary consolidation [LeMoine et al 2019].

Pulmonary histologic abnormalities. In one retrospective study of individuals with known pulmonary dysfunction and a pathogenic variant in *NKX2-1*, histologic abnormalities included interstitial widening and pneumocyte hyperplasia, desquamative interstitial pneumonia, accumulation of foamy alveolar macrophages, and pulmonary alveolar proteinosis [Hamvas et al 2013].

Pulmonary carcinoma. The risk for pulmonary carcinoma is increased in young adults (early 20s) with *NKX2-1*-related disorders [Fernandez et al 2001, Willemsen et al 2005, Glik et al 2008]. Screening for pulmonary carcinoma in adolescence is recommended (see Surveillance).

Thyroid Manifestations

Thyroid dysfunction, which results from thyroid dysgenesis, can present as congenital hypothyroidism (i.e., reduced or absent production of thyroid hormone) or compensated hypothyroidism (i.e., low-to-normal thyroid hormone production with elevated thyroid-stimulating hormone) [Moya et al 2006, Montanelli & Tonacchera 2010, Gras et al 2012]. Of note, thyroid dysgenesis can manifest structurally as thyroid hypoplasia or hemiagenesis (11/31) or complete absence of the thyroid gland (3/31) [Carré et al 2009].

Thyroid dysfunction varies between individuals with *NKX2-1*-related disorders and within families of multiple affected individuals. In a meta-analysis of 46 individuals reported with *NKX2-1*-related disorders, 40 had documented overt or subclinical hypothyroidism, and only six had normal thyroid function [Carré et al 2009].

Currently, newborn screening for hypothyroidism is available in most countries and includes measuring levels of thyroid-stimulating hormone with or without measuring thyroxine levels. Of note, congenital hypothyroidism can be the only manifestation of an *NKX2-1*-related disorder.

Other Features

Other features reported in single individuals or families include the following:

- Hypo- or oligodontia [Devos et al 2006, Guala et al 2008]
- Urinary tract abnormalities:
 - Vesicoureteral reflux [Ferrara et al 2008, Salvatore et al 2010]
 - Megacystis [Ferrara et al 2008, Salvatore et al 2010]
- Endocrine abnormalities:
 - Hypogonadotropic hypogonadism [Balicza et al 2018]
 - Growth hormone deficiency [Balicza et al 2018, Trevisani et al 2021]
- Short stature (without documented growth hormone deficiency) [Glik et al 2008]
- Webbed neck [Thorwarth et al 2014]
- Cardiac abnormalities:
 - Structural cardiac defects (ventricular or atrial septal defects) [Thorwarth et al 2014]
 - Patent foramen ovale [Ferrara et al 2008, Salvatore et al 2010]
- Joint laxity [Parnes et al 2018]
- Pes cavus [Peall et al 2014]
- Kyphosis [Peall et al 2014]

Prognosis and Progression

Life expectancy in individuals with *NKX2-1*-related disorders is expected to be normal [Fernandez et al 2001].

A retrospective study describing 28 individuals with 13 novel *NKX2-1* pathogenic variants over a mean duration of 24.5 years reported a homogeneous progression of neurologic manifestations. Hypotonia is present in the first

year of life with or without delays in motor milestones or early chorea. Chorea is generally mild and improves until puberty through early adulthood, when it typically stabilizes. In some individuals, it resolves entirely in adulthood [Gras et al 2012].

There is limited information on the long-term prognosis of pulmonary and thyroid manifestations. Progression is rare and features may improve in adulthood [Gras et al 2012]. Individuals with lung involvement are at risk of respiratory failure in early infancy, as well as recurrent infections and asthma throughout life. Compensated hypothyroidism is typically well controlled in individuals with *NKX2-1*-related disorders.

Genotype-Phenotype Correlations

Manifestations of *NKX2-1*-related disorders vary among individuals even within the same family.

Missense *NKX2-1* variants have been associated with milder phenotypes, though a systematic analysis of published reports revealed no clear correlation between variant type and protein function [Gras et al 2012, Monti et al 2015].

Penetrance

No studies have evaluated the penetrance of *NKX2-1* pathogenic variants to date. Published case series provide limited descriptions of penetrance across families, though intrafamilial variation has been reported.

Nomenclature

Before the molecular basis was known, the disorder now known to be caused by a heterozygous pathogenic variant in *NKX2-1* [Inzelberg et al 2011] was referred to as benign hereditary chorea (BHC) based on the original description of non-progressive familial chorea in a five-generation family [Haerer et al 1967]. The broad phenotypic spectrum associated with pathogenic variants in *NKX2-1* (including BHC and a variable combination of lung, thyroid, and neurologic abnormalities) led Willemsen et al [2005] to coin the term "brain-lung-thyroid syndrome." Considering the variable manifestations of individuals with pathogenic variants in *NKX2-1*, the authors suggest that these disorders be referred to as *NKX2-1*-related disorders.

Of note, *NKX2-1* was previously known as *TITF-1*; thus, early literature describing the molecular basis of this disorder uses this gene designation [Breedveld et al 2002, Kleiner-Fisman et al 2003, Costa et al 2005, Devos et al 2006, Kleiner-Fisman & Lang 2007, Glik et al 2008].

Prevalence

More than 120 individuals with *NKX2-1*-related disorders have been described in the literature. The prevalence of *NKX2-1*-related disorders is unknown.

Genetically Related (Allelic) Disorders

No phenotypes other than those discussed in this *GeneReview* are known to be associated with pathogenic variants in *NKX2-1*.

Somatic variants in *NKX2-1* have been identified in sporadic papillary thyroid and sporadic pulmonary carcinomas (lung adenocarcinoma, non-small cell lung cancer) in individuals without any other findings of *NKX2-1*-related disorders [Ngan et al 2009, Matsuse et al 2011, Watanabe et al 2013, Tsai et al 2014]. In these instances, the *NKX2-1* variant is **not** present in the germline and therefore predisposition to these tumors is not heritable.

Differential Diagnosis

The differential diagnosis of *NKX2-1*-related disorders includes hereditary (see Table 3a) and acquired (see Table 3b) causes of chorea, congenital hypothyroidism, and respiratory insufficiency.

Table 3a. Selected Hereditary Disorders in the Differential Diagnosis of *NKX2-1*-Related Disorders

Gene(s)	Disorder	MOI	Comment
Chorea¹			
<i>ADCY5</i>	<i>ADCY5</i> dyskinesia	AD (AR)	Hyperkinetic movement disorder (more prominent in face & arms than legs) characterized by infantile- to late adolescent-onset of chorea, athetosis, dystonia, myoclonus, or combination of these features.
<i>ATN1</i>	DRPLA	AD	Rare disorder assoc w/adult-onset chorea, myoclonic epilepsy, dementia, & ataxia. Not typically seen in infants or children.
<i>ATP13A2</i> <i>C19orf12</i> <i>COASY</i> <i>CP</i> <i>DCAF17</i> <i>FA2H</i> <i>FTL</i> <i>GNAO1</i> <i>PANK2</i> <i>PLA2G6</i> <i>WDR45</i>	Neurodegeneration with brain iron accumulation	AR AD XL ²	Neurologic disorders characterized by abnormal accumulation of iron in basal ganglia. Hallmark clinical manifestations are progressive dystonia & dysarthria, spasticity, parkinsonism, neuropsychiatric abnormalities, & optic atrophy or retinal degeneration. Although cognitive decline occurs in some genetic subtypes, more often cognition is relatively spared. Age of onset ranges from infancy to adulthood.
<i>ATP7B</i>	Wilson disease	AR	Disorder of copper metabolism that, when untreated, can present w/hepatic, neurologic, or psychiatric disturbances – or combination of these – in persons ages 3 yrs to >70 yrs. Neurologic presentations can incl dysarthria, movement disorders (tremors, involuntary movements, chorea, choreoathetosis), dystonia, dysautonomia, seizures, sleep disorders, or insomnia.
<i>HTT</i>	Huntington disease	AD	Progressive disorder of motor, cognitive, & psychiatric disturbances. Mean age of onset is 35-44 yrs.
<i>JPH3</i>	Huntington disease-like 2	AD	Similar presentation to Huntington disease. Assoc w/progressive course of chorea, rigidity, & cognitive & psychiatric disturbances. Typically presents in midlife.
<i>PNKD</i>	Familial paroxysmal nonkinesigenic dyskinesia	AD	Unilateral or bilateral involuntary movements. Attacks – typically precipitated by coffee, tea, or alcohol – involve dystonic posturing w/choreic & ballistic movements, may be accompanied by preceding aura, occur while person is awake, & are not assoc w/seizures. Age of onset is typically in childhood or early teens.

Table 3a. continued from previous page.

Gene(s)	Disorder	MOI	Comment
<i>TBP</i>	Spinocerebellar ataxia type 17 (Huntington disease-like 4)	AD	Similar presentation to Huntington disease. Assoc w/progressive course of chorea, rigidity, cognitive & psychiatric disturbances. Age of onset ranges from 3 to 55 yrs.
<i>PRNP</i>	Genetic prion disease	AD	Similar presentation to Huntington disease. Assoc w/progressive course of chorea, rigidity, & cognitive & psychiatric disturbances. Age at onset typically ranges from 50 to 60 yrs.
<i>PRRT2</i>	<i>PRRT2</i> -related paroxysmal kinesigenic dyskinesia (See <i>PRRT2</i> -Assoc Paroxysmal Movement Disorders.)	AD (AR)	Paroxysmal attacks are often characterized by dystonia, followed by choreoathetosis & rarely ballism. Attacks often occur bilaterally. Onset is in childhood or adolescence.
<i>SGCE</i>	<i>SGCE</i> myoclonus-dystonia	AD ³	Myoclonic jerks most often affect neck, trunk, & upper limbs w/less common involvement of legs. ~50% have additional focal or segmental dystonia. Symptom onset is usually in 1st decade of life & almost always by age 20 yrs. Most affected adults report dramatic reduction in myoclonus in response to alcohol ingestion.
<i>VPS13A</i>	<i>VPS13A</i> disease	AR	Chorea & dystonia are common presenting symptoms w/prominent orofacial movements. Assoc w/red cell acanthocytosis (acanthocytes usually comprise 5%-50% of RBC population in affected persons; however, acanthocytes may be absent or may appear only late in the disease course). Average age of onset 30s-40s.
<i>XK</i>	McLeod neuroacanthocytosis syndrome	XL	Multisystem disorder w/CNS, neuromuscular, cardiovascular, & hematologic manifestations in males. CNS manifestations incl neurodegenerative basal ganglia disease incl movement disorders, cognitive alterations, & psychiatric symptoms.
Congenital hypothyroidism⁴			
<i>SERPINA7</i>	Thyroxine-binding globulin deficiency (OMIM 314200)	XL	
<i>IRS4</i> <i>NKX2-5</i> <i>PAX8</i> <i>TBL1X</i> <i>THRA</i> <i>TRHR</i> <i>TSHB</i> <i>TSHR</i>	Congenital nongoitrous hypothyroidism (OMIM PS275200)	AR AD XL	
<i>DUOX2</i> <i>DUOXA2</i> <i>IYD</i> (DEHAL1) <i>SLC5A5</i> <i>TG</i> <i>TPO</i>	Thyroid dysmorphogenesis 1 (OMIM 274400, 274500, 274700, 274800, 274900, 607200)	AR	

Table 3a. continued from previous page.

Gene(s)	Disorder	MOI	Comment
Respiratory insufficiency			
Many monogenic & chromosomal causes	Congenital diaphragmatic hernia (CDH)	See footnote 5.	Older data using standard cytogenetic & molecular cytogenetic techniques identified a genetic cause for ~15%-20% of CDH. Genetic causes can be subdivided into monogenic causes & chromosome anomalies; though monogenic CDH can be isolated, it is more commonly syndromic.

AD = autosomal dominant; AR = autosomal recessive; CNS = central nervous system; MOI = mode of inheritance; RBC = red blood cell; XL = X-linked

1. Some individuals initially diagnosed with benign hereditary chorea are later found to have another diagnosis, such as myoclonic dystonia or Huntington disease [Schrag et al 2000].

2. Mode of inheritance depends on genetic type; see Neurodegeneration with Brain Iron Accumulation, [Genetic Counseling](#).

3. *SGCE* myoclonus-dystonia is inherited in an autosomal dominant manner with penetrance determined by the parental origin of the altered *SGCE* allele: an *SGCE* pathogenic variant on the paternally derived (expressed) *SGCE* allele generally results in disease; a pathogenic variant on the maternally derived (silenced) *SGCE* allele typically does not result in disease.

4. Newborn screening for congenital hypothyroidism typically includes measurement of serum thyroid-stimulating hormone (TSH) and thyroxine levels (T_4). *NKX2-1*-related disorders are associated with primary hypothyroidism with elevated serum TSH and low free T_4 . Additional testing with thyroid ultrasound, radionucleotide uptake scan, serum thyroglobulin, urinary iodine, and maternal TSH receptor-blocking antibodies can be obtained based on clinical suspicion and family history. Central hypothyroidism is associated with normal-to-low TSH with low free T_4 . This condition is often associated with abnormalities in other pituitary hormone levels such as adrenocorticotrophic hormone, gonadotropins, growth hormone, and prolactin.

5. Mode of inheritance depends on the genetic etiology.

Other hereditary disorders associated with chorea that can be considered in the differential diagnosis include:

- Neurometabolic disorders ([Lesch-Nyhan disease](#), lysosomal storage disorders, amino acid deficiency disorders, [Leigh syndrome](#))
- [Mitochondrial disorders](#)

Table 3b. Acquired Disorders in the Differential Diagnosis of *NKX2-1*-Related Disorders

Clinical Feature	Differential Diagnosis
Chorea	<p>In <i>NKX2-1</i>-related disorders, chorea is primarily characterized by infantile or early childhood onset and is non-progressive w/good prognosis.</p> <ul style="list-style-type: none"> • Physiologic chorea of infancy • Chorea minima • Idiopathic chorea • Bucco-oro-lingual dyskinesias
	<p><i>NKX2-1</i>-related chorea can be differentiated from chorea assoc w/ generally progressive cognitive/neurologic dysfunction.</p> <ul style="list-style-type: none"> • Drug & toxin-related chorea ¹ • Metabolic & endocrine disorders ² • Infection- & post-infection-related disorders ³ • Immunologic-related chorea ⁴ • Vascular-related chorea ⁵ • Tumor-related chorea • Trauma-related chorea • Miscellaneous causes of chorea ⁶
Congenital hypothyroidism ⁷	<p>In <i>NKX2-1</i>-related disorders, congenital hypothyroidism is similar to idiopathic congenital hypothyroidism.</p> <ul style="list-style-type: none"> • Hypopituitarism & panhypopituitarism • Iodine deficiency • Maternal antibody-mediated congenital hypothyroidism

Table 3b. continued from previous page.

Clinical Feature		Differential Diagnosis
Respiratory insufficiency ⁸	In <i>NKX2-1</i> -related disorders, neonatal pulmonary hypertension is a characteristic form of respiratory distress.	<ul style="list-style-type: none"> • Respiratory distress syndrome (hyaline membrane disease) • Meconium aspiration syndrome • Persistent pulmonary hypertension • Pneumothorax • Transient tachypnea of the newborn • Polycythemia • Non-pulmonary causes

1. Neuroleptic exposure, anoxia, cerebral palsy (anoxia), carbon monoxide exposure, heavy metal poisoning

2. Hypo- and hyperglycemia (non-ketotic), kidney failure, nutritional causes

3. Sydenham chorea, other infectious and post-infectious encephalitis (Lyme disease, mycoplasma)

4. Acute disseminated encephalomyelitis (ADEM), acquired immunodeficiency syndrome (AIDS)

5. Infarction or hemorrhage, arteriovenous malformation, antiphospholipid syndrome, following cardiac surgery with hypothermia and extracorporeal circulation in children (i.e., CHAP [choreoathetosis and orofacial dyskinesia, hypotonia, and pseudobulbar signs] syndrome)

6. Kernicterus, sarcoidosis, multiple sclerosis

7. Screening for congenital hypothyroidism is performed by checking serum thyroid-stimulating hormone (TSH) and thyroxine levels (T₄). *NKX2-1*-related disorders are associated with primary hypothyroidism with elevated serum TSH and low free T₄. Additional testing with thyroid ultrasound, radionucleotide uptake scan, serum thyroglobulin, urinary iodine, and maternal TSH receptor-blocking antibodies can be obtained based on clinical suspicion and family history. Central hypothyroidism is associated with normal-to-low TSH with low free T₄. This condition is often associated with abnormalities in other pituitary hormone levels such as adrenocorticotropic hormone, gonadotropins, growth hormones, and prolactin.

8. The etiology of respiratory insufficiency and respiratory distress syndrome in neonates is determined by perinatal risk factors such as gestational age, method of delivery, risk of infection, and associated complications such as presence of meconium in amniotic fluid or exposure to bacterial infections in the perinatal period. Chest radiograph can aid in determining the presence of a pneumothorax and other structural abnormalities in the chest.

Management

No clinical practice guidelines for *NKX2-1*-related disorders have been published.

Evaluations Following Initial Diagnosis

To establish the extent of disease and needs in an individual diagnosed with an *NKX2-1*-related disorder, the evaluations summarized in Table 4 (if not performed as part of the evaluation that led to the diagnosis) are recommended.

Table 4. *NKX2-1*-Related Disorders: Recommended Evaluations Following Initial Diagnosis

System/Concern	Evaluation	Comment
Neurologic	Neurologic eval	<ul style="list-style-type: none"> • Evaluate for chorea (especially benign hereditary chorea), as well as other neurologic manifestations (e.g., tone abnormalities, other abnormal movements). • Brain MRI eval
Pulmonary	Pulmonary eval	<ul style="list-style-type: none"> • Evaluate & treat pulmonary dysfunction • Pulmonary function tests • Initial screening for pulmonary malignancy w/ chest x-ray or CT scan of chest during early adolescence (age 13 yrs)

Table 4. continued from previous page.

System/Concern	Evaluation	Comment
Thyroid	<ul style="list-style-type: none"> Thyroid function tests (TSH, T₄, T₃) for eval of hypothyroidism Initial eval for thyroid malignancy by physical exam incl thyroid palpation. Thyroid ultrasound & imaging is only indicated if an abnormality is found on palpation of thyroid gland. 	Initial screening for thyroid cancer in childhood (age 5 yrs)
Developmental	Eval by neurodevelopmental pediatrician &/or physical therapist	<ul style="list-style-type: none"> In early childhood (age 12 mos) Evaluate for gross motor issues & gait abnormalities, which can occur in early course of disease.
Neuropsychiatric	Neuropsychiatric eval	Evaluate for ADHD & other psychiatric manifestations
Genetic counseling	By genetics professionals ¹	To inform affected persons & their families re nature, MOI, & implications of <i>NKX2-1</i> -related disorders to facilitate medical & personal decision making
Family support & resources	Assess need for: <ul style="list-style-type: none"> Community or online resources such as Parent to Parent; Social work involvement for parental support; Home nursing referral. 	

ADHD = attention-deficit/hyperactivity disorder; MOI = mode of inheritance; T₃ = triiodothyronine; T₄ = thyroxine; TSH = thyroid-stimulating hormone

1. Medical geneticist, certified genetic counselor, certified advanced genetic nurse

Treatment of Manifestations

Supportive care to improve the quality of life, maximize function, and reduce complications is recommended. This ideally involves multidisciplinary care by specialists in relevant fields (see Table 5).

Table 5. *NKX2-1*-Related Disorders: Treatment of Manifestations

Manifestation/Concern	Treatment	Considerations/Other
Chorea	Tetrabenazine, deutetrabenazine, or valbenazine starting at low doses & gradually increasing dose to optimally control symptoms	<ul style="list-style-type: none"> Considered a first-line treatment for chorea. Reported to ↓ chorea in low doses.¹ Dosage recommendation: <ul style="list-style-type: none"> Children: 0.5 mg/kg/day starting dose divided into 2-3 doses Adults: 37.5 mg/day starting dose divided into 2-3 doses
	Levodopa, esp in persons w/gait abnormalities	<ul style="list-style-type: none"> Reported to improve chorea in some children; can be considered as second-line therapy.² Has been shown to cause dramatic & substantial improvement in gait abnormalities (specifically ↓ falls); can be used as first-line therapy in children w/gait impairment.

Table 5. continued from previous page.

Manifestation/Concern	Treatment	Considerations/Other
Pulmonary dysfunction	<ul style="list-style-type: none"> Respiratory support as needed in neonatal period Early & aggressive treatment of asthma Early & aggressive treatment of respiratory infections RSV vaccination in infancy Routine vaccinations Treatment of ILD by pulmonologist 	
Pulmonary carcinoma	Standard treatment per oncologist & pulmonologist	
Hypothyroidism /Thyroid dysfunction	Thyroid hormone replacement per endocrinologist	Early initiation in neonatal period is critical to avoid neurodevelopmental consequences of untreated hypothyroidism.
Motor & gait issues	Early intervention & PT	
Neuropsychiatric issues	Standard treatment per neuropsychiatrist	

ILD = interstitial lung disease; PT = physical therapy

1. Jankovic [2009], Salvatore et al [2010], Jankovic & Clarence-Smith [2011], Gras et al [2012], Jimenez-Shahed & Jankovic [2013], Bashir & Jankovic [2018]

2. Asmus et al [2005], Rosati et al [2015]

Surveillance

To monitor existing manifestations, the individual's response to supportive care, and the emergence of new manifestations, the evaluations summarized in Table 6 are recommended.

Table 6. NKX2-1-Related Disorders: Recommended Surveillance

System/Concern	Evaluation	Frequency
Neurologic (esp chorea)	Neurologic eval	Annually or more frequently as needed (incl persons w/o neurologic manifestations)
Pulmonary	<ul style="list-style-type: none"> Pulmonary eval Pulmonary function tests Lung imaging (chest x-ray or chest CT scan) to screen for pulmonary malignancy 	Annually or more frequently as needed (incl persons w/o pulmonary manifestations)
Thyroid	<ul style="list-style-type: none"> Eval w/endocrinologist Thyroid function tests (T₄, TSH) Physical exam incl palpation of thyroid to assess for thyroid cancer 	Annually or more frequently as needed (incl persons w/o endocrine manifestations)

T₄ = thyroxine; TSH = thyroid-stimulating hormone

Agents/Circumstances to Avoid

Although Glik et al [2008] reported amelioration of choreic movements in an individual with benign hereditary chorea treated with olanzapine for psychosis, dopamine receptor blockers are not recommended as a first-line therapy for the treatment of chorea. Olanzapine and dopamine receptor blockers, while effective in treating choreiform movements, are associated with a small risk of developing tardive dyskinesia, which can worsen choreiform movements long term.

Due to the risk of pulmonary disease in *NKX2-1*-related disorders, exposure to smoking may exacerbate pulmonary dysfunction and increase the risk of lung cancer in affected individuals.

Evaluation of Relatives at Risk

It is appropriate to clarify the genetic status of at-risk relatives prenatally or as soon as possible after birth to identify infants at high risk for congenital hypothyroidism and pulmonary disease, establish the diagnosis and initiate medical management early, and, importantly, prevent the neurodevelopmental consequences of untreated congenital hypothyroidism. In most countries, newborn screening for congenital hypothyroidism is performed; however, if this is not routine practice, it is recommended to screen at-risk newborns for congenital hypothyroidism.

See Genetic Counseling for issues related to testing of at-risk relatives for genetic counseling purposes.

Pregnancy Management

There is no known increased risk during pregnancy for a woman with an *NKX2-1*-related disorder.

Prior to pregnancy or early in gestation, it is recommended that a woman work with her physician to determine whether any medication she is taking for chorea is safe for the fetus.

See [MotherToBaby](#) for further information on medication use during pregnancy.

Therapies Under Investigation

Search [ClinicalTrials.gov](#) in the US and [EU Clinical Trials Register](#) in Europe for access to information on clinical studies for a wide range of diseases and conditions. Note: There may not be clinical trials for this disorder.

Genetic Counseling

Genetic counseling is the process of providing individuals and families with information on the nature, mode(s) of inheritance, and implications of genetic disorders to help them make informed medical and personal decisions. The following section deals with genetic risk assessment and the use of family history and genetic testing to clarify genetic status for family members; it is not meant to address all personal, cultural, or ethical issues that may arise or to substitute for consultation with a genetics professional. —ED.

Mode of Inheritance

NKX2-1-related disorders are inherited in an autosomal dominant manner.

Risk to Family Members

Parents of a proband

- Most individuals diagnosed with an *NKX2-1*-related disorder have an affected parent.
- A proband with an *NKX2-1*-related disorder may have the disorder as the result of a *de novo* pathogenic variant; however, the proportion of probands who have a *de novo* pathogenic variant is unknown.
- If the proband appears to be the only affected family member (i.e., a simplex case), molecular genetic testing is recommended for the parents of the proband to confirm their genetic status and to allow reliable recurrence risk counseling.
- If the pathogenic variant identified in the proband is not identified in either parent and parental identity testing has confirmed biological maternity and paternity, the following possibilities should be considered:
 - The proband has a *de novo* pathogenic variant.

- The proband inherited a pathogenic variant from a parent with germline (or somatic and germline) mosaicism. Note: Testing parental leukocyte DNA may not detect all instances of somatic mosaicism and will not detect a pathogenic variant that is present in the germ cells only.
- The family history of some individuals diagnosed with an *NKX2-1*-related disorder may appear to be negative because of failure to recognize the disorder in family members due to mild manifestations, early death of the parent before the onset of symptoms, or late onset of the disease in the affected parent. Therefore, an apparently negative family history cannot be confirmed unless molecular genetic testing has demonstrated that neither parent is heterozygous for the pathogenic variant identified in the proband.

Sibs of a proband. The risk to the sibs of the proband depends on the genetic status of the proband's parents:

- If a parent of the proband is affected and/or is known to have the pathogenic variant identified in the proband, the risk to the sibs of inheriting the pathogenic variant is 50%.
- If the *NKX2-1* pathogenic variant found in the proband cannot be detected in the leukocyte DNA of either parent, the recurrence risk to sibs is estimated to be 1% because of the theoretical possibility of parental germline mosaicism [Rahbari et al 2016].
- If the parents have not been tested for the *NKX2-1* pathogenic variant but are clinically unaffected, the risk to the sibs of a proband appears to be low. However, sibs of a proband with clinically unaffected parents are still presumed to be at increased risk for an *NKX2-1*-related disorder because of the possibility of reduced penetrance in a heterozygous parent or the theoretical possibility of parental germline mosaicism.

Offspring of a proband. Each child of an individual with an *NKX2-1*-related disorder has a 50% chance of inheriting the pathogenic variant.

Other family members. The risk to other family members depends on the status of the proband's parents: if a parent has the *NKX2-1* pathogenic variant, the parent's family members may be at risk.

Related Genetic Counseling Issues

See Management, Evaluation of Relatives at Risk for information on evaluating at-risk relatives for the purpose of early diagnosis and treatment.

Predictive testing for at-risk asymptomatic family members requires prior identification of the pathogenic variant in the family.

Family planning

- The optimal time for determination of genetic risk and discussion of the availability of prenatal/preimplantation genetic testing is before pregnancy.
- It is appropriate to offer genetic counseling (including discussion of potential risks to offspring and reproductive options) to young adults who are affected or at risk.

Prenatal Testing and Preimplantation Genetic Testing

Once the *NKX2-1* pathogenic variant has been identified in an affected family member, prenatal and preimplantation genetic testing are possible.

Differences in perspective may exist among medical professionals and within families regarding the use of prenatal testing. While most centers would consider use of prenatal testing to be a personal decision, discussion of these issues may be helpful.

Resources

GeneReviews staff has selected the following disease-specific and/or umbrella support organizations and/or registries for the benefit of individuals with this disorder and their families. GeneReviews is not responsible for the information provided by other organizations. For information on selection criteria, click [here](#).

- **MedlinePlus**
Brain-lung-thyroid syndrome
- **Newborn Screening in Your State**
Health Resources & Services Administration
www.newbornscreening.hrsa.gov/your-state

Molecular Genetics

Information in the Molecular Genetics and OMIM tables may differ from that elsewhere in the GeneReview: tables may contain more recent information. —ED.

Table A. NKX2-1-Related Disorders: Genes and Databases

Gene	Chromosome Locus	Protein	Locus-Specific Databases	HGMD	ClinVar
NKX2-1	14q13.3	Homeobox protein Nkx-2.1	NKX2-1 database	NKX2-1	NKX2-1

Data are compiled from the following standard references: gene from [HGNC](#); chromosome locus from [OMIM](#); protein from [UniProt](#). For a description of databases (Locus Specific, HGMD, ClinVar) to which links are provided, click [here](#).

Table B. OMIM Entries for NKX2-1-Related Disorders ([View All in OMIM](#))

118700	CHOREA, BENIGN HEREDITARY; BHC
600635	NK2 HOMEODOMAIN 1; NKX2-1
610978	CHOREOATHETOSIS AND CONGENITAL HYPOTHYROIDISM WITH OR WITHOUT PULMONARY DYSFUNCTION; CAHTP

NKX2-1 encodes the homeobox protein Nkx-2.1. This protein, also known as thyroid transcription factor 1 (TTF-1), plays a critical role during organogenesis of the basal ganglia, lungs, and thyroid [Guillot et al 2010]. In vivo studies have shown that *NKX2-1* is implicated in the development of the globus pallidus and striatal cholinergic neurons [Flandin et al 2010], as well as development of the lungs, surfactant production, and maintenance of surfactant homeostasis [Kleinlein et al 2011, Peca et al 2011]. Supporting the role of *NKX2-1* in lung development, pathogenic variants in *NKX2-1* are commonly associated with impaired pulmonary branching and reduced alveolar counts [Galambos et al 2010]. *NKX2-1* is also important for early thyroid development in addition to maintenance of the architecture and function of the fully developed thyroid gland [Kusakabe et al 2006, Fagman & Nilsson 2011, Kimura 2011].

Mechanism of disease causation. Loss of function (due to haploinsufficiency)

***NKX2-1*-specific laboratory technical considerations.** In individuals without a pathogenic variant identified by *NKX2-1* sequencing and deletion/duplication analysis, chromosomal microarray should be performed, as large deletions downstream of *NKX2-1* have been described [Villamil-Osorio et al 2021].

There are several *NKX2-1* transcripts. The longer transcript (NM_001079668.2) comprises three exons. Most pathogenic variants in *NKX2-1* have been reported in this transcript. A shorter transcript has been identified (NM_003317.3).

Chapter Notes

Author Notes

Joseph Jankovic, MD

USH University Medical Center Parkinson's Disease and Movement Disorders Care

Revision History

- 29 June 2023 (gm) Comprehensive update posted live
- 29 July 2016 (ha) Comprehensive updated posted live
- 20 February 2014 (me) Review posted live
- 9 September 2013 (np) Original submission

References

Literature Cited

- Asmus F, Horber V, Pohlentz J, Schwabe D, Zimprich A, Munz M, Schöning M, Gasser T. A novel TITF-1 mutation causes benign hereditary chorea with response to levodopa. *Neurology* 2005;64:1952-4 PubMed PMID: 15955952.
- Balicza P, Grosz Z, Molnár V, Illés A, Csabán D, Gézsi A, Dézsi L, Zádori D, Vécsei L, Molnár MJ. NKX2-1 new mutation associated with myoclonus, dystonia, and pituitary involvement. *Front Genet.* 2018;9:335. PubMed PMID: 30186310.
- Barnett CP, Mencil JJ, Gecz J, Waters W, Kirwin SM, Vinette KM, Uppill M, Nicholl J. Choreoathetosis, congenital hypothyroidism and neonatal respiratory distress syndrome with intact NKX2-1. *Am J Med Genet A.* 2012;158A:3168-73. PubMed PMID: 23169673.
- Bashir H, Jankovic J. Treatment options for chorea. *Expert Rev Neurother.* 2018;18:51-63. PubMed PMID: 29120264.
- Breedveld GJ, van Dongen JW, Danesino C, Guala A, Percy AK, Dure LS, Harper P, Lazarou LP, van der Linde H, Joosse M, Grütters A, MacDonald ME, de Vries BB, Arts WF, Oostra BA, Krude H, Heutink P. Mutations in TITF-1 are associated with benign hereditary chorea. *Hum Mol Genet* 2002;11:971-9. PubMed PMID: 11971878.
- Carré A, Szinnai G, Castanet M, Sura-Trueba S, Tron E, Broutin-L'Hermite I, Barat P, Goizet C, Lacombe D, Moutard ML, Raybaud C, Raynaud-Ravni C, Romana S, Ythier H, Léger J, Polak M. Five new TTF1/NKX2.1 mutations in brain-lung-thyroid syndrome: rescue by PAX8 synergism in one case. *Hum Mol Genet.* 2009;18:2266-76. PubMed PMID: 19336474.
- Costa MC, Costa C, Silva AP, Evangelista P, Santos L, Ferro A, Segeiros J, Maciel P. Nonsense mutation in TITF1 in a Portuguese family with benign hereditary chorea. *Neurogenetics.* 2005;6:209-15. PubMed PMID: 16220345.
- de Gusmao CM, Kok F, Casella EB, Waugh JL. Benign hereditary chorea related to NKX2-1 with ataxia and dystonia. *Neurol Genet.* 2015;2:e40. PubMed PMID: 27066577.
- Devos D, Vuillaume I, de Becdelievre A, de Martinville B, Dhaenens CM, Cuvelier JC, Cuisset JM, Vallee L, Lemaitre MP, Bourteel H, Hachulla E, Wallaert B, Destee A, Defebvre L, Sablonniere B. New syndromic form

- of benign hereditary chorea is associated with a deletion of TITF-1 and PAX-9 contiguous genes. *Mov Disord.* 2006;21:2237-40. PubMed PMID: 17044090.
- Fagman H, Nilsson M. Morphogenetics of early thyroid development. *J Mol Endocrinol.* 2011; 46:R33-42. PubMed PMID: 21322126.
- Fernandez M, Raskind W, Matsushita M, Wolff J, Lipe H, Bird T. Hereditary benign chorea: clinical and genetic features of a distinct disease. *Neurology.* 2001;57:106-10. PubMed PMID: 11445636.
- Ferrara AM, De Michele G, Salvatore E, Di Maio L, Zampella E, Capuano S, Del Prete G, Fenzi G, Filla A, Macchia PE. A novel NKX2.1 mutation in a family with hypothyroidism and benign hereditary chorea. *Thyroid.* 2008;18:1005-9. PubMed PMID: 18788921.
- Flandin P, Kimura S, Rubenstein JL. The progenitor zone of the ventral medial ganglionic eminence requires Nkx2-1 to generate most of the globus pallidus but few neocortical interneurons. *J Neurosci.* 2010;30:2812-23. PubMed PMID: 20181579.
- Galambos C, Levy H, Cannon CL, Vargas SO, Reid LM, Cleveland R, Lindeman R, deMello DE, Wert SE, Whitsett JA, Perez-Atayde AR, Kozakewich H. Pulmonary pathology in thyroid transcription factor-1 deficiency syndrome. *Am J Respir Crit Care Med.* 2010;182:549-54. PubMed PMID: 20203240.
- Gillett ES, Deutsch GH, Bamshad MJ, McAdams RM, Mann PC. Novel NKX2.1 mutation associated with hypothyroidism and lethal respiratory failure in a full-term neonate. *J Perinatol.* 2013;33:157-60. PubMed PMID: 23361500.
- Glik A, Vuillaume I, Devos D, Inzelberg R. Psychosis, short stature in benign hereditary chorea: a novel thyroid transcription factor-1 mutation. *Mov Disord.* 2008;23:1744-7. PubMed PMID: 18661567.
- Gonçalves D, Lourenço L, Guardiano M, Castro-Correia C, Sampaio M, Leão M. Chiari malformation type I in a patient with a novel NKX2-1 mutation. *J Pediatr Neurosci.* 2019;14:169-72. PubMed PMID: 31649781.
- Gras D, Jonard L, Roze E, Chantot-Bastarud S, Koht J, Motte J, Rodriguez D, Louha M, Caubel I, Kemlin I, Lion-Francois L, Goizet C, Guillot L, Moutard ML, Epaud R, Heron B, Charles P, Tallot M, Camuzat A, Durr A, Polak A, Devos D, Sanlaville D, Vuillaume I, Billette de Villemeur T, Vidailhet M, Doummar D. Benign hereditary chorea: phenotype, prognosis, therapeutic outcome and long term follow-up in a large series with new mutations in the TITF1/NKX2-1 gene. *J Neurol Neurosurg Psychiatry.* 2012;83:956-62. PubMed PMID: 22832740.
- Graziola F, Garone G, Grasso M, Schirinzi T, Capuano A. Working memory, attention and planning abilities in NKX2.1-related chorea. *Parkinsonism Relat Disord.* 2021;88:24-7. PubMed PMID: 34091414.
- Guala A, Falco V, Breedveld G, De Filippi P, Danesino C. Deletion of PAX9 and oligodontia: a third family and review of the literature. *Int J Paediatr Dent.* 2008;18:441-5. PubMed PMID: 18445003.
- Guillot L, Carre A, Szinnai G, Castanet M, Tron E, Jaubert F, Broutin I, Counil F, Feldmann D, Clement A, Polak M, Epaud R. NKX2-1 mutations leading to surfactant protein promoter dysregulation cause interstitial lung disease in "brain-lung-thyroid syndrome". *Hum Mutat.* 2010;31:E1146-62. PubMed PMID: 20020530.
- Haerer AF, Currier RD, Jackson JF. Hereditary nonprogressive chorea of early onset. *N Engl J Med.* 1967;276:1220-4. PubMed PMID: 4225827.
- Hamvas A, Deterding RR, Wert SE, White FV, Dishop MK, Alfano DN, Halnower A, Planer B, Stephan MJ, Uchinda DA, Williams LD, Rosenfeld JA, Lebel RR, Young LR, Cole FS, Noguee LM. Heterogeneous pulmonary phenotypes associated with mutations in the thyroid transcription factor gene NKX2-1. *Chest.* 2013;144:794-804. PubMed PMID: 23430038.
- Invernizzi F, Zorzi G, Legati A, Coppola G, D'Adamo P, Nardocci N, Garavaglia B, Ghezzi D. Benign hereditary chorea and deletions outside NKX2-1: what's the role of MBIP? *Eur J Med Genet.* 2018;61:581-4. PubMed PMID: 29621620.

- Inzelberg R, Weinberger M, Gak E. Benign hereditary chorea: an update. *Parkinsonism Relat Disord*. 2011;17:301-7. PubMed PMID: 21292530.
- Iodice A, Carecchio M, Zorzi G, Garavaglia B, Spagnoli C, Salerno GG, Frattini D, Mencacci NE, Invernizzi F, Veneziano L, Mantuano E, Angriman M, Fusco C. Restless legs syndrome in NKX2-1-related chorea: an expansion of the disease spectrum. *Brain Dev*. 2019;41:250-6. PubMed PMID: 30352709.
- Iwatani N, Mabe H, Devriendt K, Kodama M, Miike T. Deletion of NKX2.1 gene encoding thyroid transcription factor-1 in two siblings with hypothyroidism and respiratory failure. *J Pediatr*. 2000;137:272-6. PubMed PMID: 10931427.
- Jankovic J. Treatment of hyperkinetic movement disorders. *Lancet Neurol* 2009;8:844-56. PubMed PMID: 19679276.
- Jankovic J, Clarence-Smith K. Tetrabenazine for the treatment of chorea and other hyperkinetic movement disorders. *Expert Rev Neurother* 2011;11:1509-23. PubMed PMID: 22014129.
- Jimenez-Shahed J, Jankovic J. Tetrabenazine for treatment of chorea associated with Huntington's disease. *Expert Opin Orphan Drugs* 2013;1:423-36.
- Kharbanda M, Hermanns P, Jones J, Pohlenz J, Horrocks I, Donaldson M. A further case of brain-lung-thyroid syndrome with deletion proximal to NKX2-1. *Eur J Med Genet*. 2017;60:257-60. PubMed PMID: 28286255.
- Kimura S. Thyroid-specific transcription factors and their roles in thyroid cancer. *J Thyroid Res*. 2011;2011:710213. PubMed PMID: 21687604.
- Kleiner-Fisman G, Lang AE. Benign hereditary chorea revisited: a journey to understanding. *Mov Disord* 2007;22:2297-305. PubMed PMID: 17702033.
- Kleiner-Fisman G, Rogaeva E, Halliday W, Houle S, Kawarai T, Sato C, Medeiros H, St George-Hyslop PH, Lang AE. Benign hereditary chorea: clinical, genetic, and pathological findings. *Ann Neurol* 2003;54:244-7. PubMed PMID: 12891678.
- Kleinlein B, Griese M, Liebisch G, Krude H, Lohse P, Aslanidis C, Schmitz G, Pters J, Holzinger A. Fatal neonatal respiratory failure in an infant with congenital hypothyroidism due to haploinsufficiency of the NKX2-1 gene: alteration of pulmonary surfactant homeostasis. *Arch Dis Child Fetal Neonatal Ed*. 2011;96:F453-6. PubMed PMID: 20584796.
- Konishi T, Kono S, Fujimoto M, Terada T, Matsushita K, Ouchi Y, Miyajima H. Benign hereditary chorea: dopaminergic brain imaging in patients with a novel intronic NKX2.1 gene mutation. *J Neurol*. 2013;260:207-13. PubMed PMID: 22825795.
- Krude H, Schutz B, Biebermann H, von Moers A, Schnabel D, Neitzel H, Tonnies H, Weise D, Lafferty A, Schwarz S, Defelice M, Von Deimling A, Van Langeghem F, Dilauro R, Gruters A. Choreoathetosis, hypothyroidism, and pulmonary alterations due to human NKX2-1 haploinsufficiency. *J Clin Invest*. 2002;109:475-80. PubMed PMID: 11854319.
- Kusakabe T, Kawaguchi A, Hoshi N, Kawaguchi R, Hoshi S, Kimura S. Thyroid-specific enhancer-binding protein/NKX2.1 is required for the maintenance of ordered architecture and function of the differentiated thyroid. *Mol Endocrinol*. 2006; 20:1796-809. PubMed PMID: 16601074.
- LeMoine BD, Browne LP, Liptzin DR, Deterding RR, Galambos C, Weinman JP. High-resolution computed tomography findings of thyroid transcription factor 1 deficiency (NKX2-1 mutations). *Pediatr Radiol*. 2019;49:869-75. PubMed PMID: 30927038.
- Liao J, Coffman KA, Locker J, Padiath QS, Nmezi B, Filipink RA, Hu J, Sathanoori M, Madan-Khetarpal S, McGuire M, Schreiber A, Moran R, Friedman N, Hoffner L, Rajkovic A, Yatsenko SA, Surti U. Deletion of conserved non-coding sequences downstream from NKX2-1: a novel disease-causing mechanism for benign hereditary chorea. *Mol Genet Genomic Med*. 2021;9:e1647. PubMed PMID: 33666368.

- Maquet E, Costagliola S, Parma J, Christophe-Hobertus C, Oligny LL, Fournet JC, Robitaille Y, Vuissoz JM, Payot A, Laberge S, Van Vliet G, Deladoey J. Lethal respiratory failure and mild primary hypothyroidism in a term girl with a de novo heterozygous mutation in the TITF1/NKX2.1 gene. *J Clin Endocrinol Metab*. 2009;94:197-203. PubMed PMID: 18957494.
- Matsuse M, Takashashi M, Mitsutake N, Nishihara E, Hirokawa M, Kawaguchi T, Rogonovitch T, Saenko V, Bychkov A, Suzuki K, Matsuo K, Tajima K, Miyauchi A, Yamada R, Matsuda F, Yamashita S. The FOXE1 and NKX2-1 loci are associated with susceptibility to papillary thyroid carcinoma in the Japanese population. *J Med Genet*. 2011;48:645-8. PubMed PMID: 21730105.
- McMichael G, Haan E, Gardner A, Yap TY, Thompson S, Ouvrier R, Dale RC, Gecz J, MacLennan AH. NKX2-1 mutation in a family diagnosed with ataxic dyskinetic cerebral palsy. *Eur J Med Genet*. 2013;56:506-9. PubMed PMID: 23911641.
- Montanelli L, Tonacchera M. Genetics and phenomics of hypothyroidism and thyroid dys- and agenesis due to PAX8 and TTF1 mutations. *Mol Cell Endocrinol* 2010;322:64-71. PubMed PMID: 20302910.
- Monti S, Nicoletti A, Cantasano A, Krude H, Cassio A. NKX2.1-related disorders: a novel mutation with mild clinical presentation. *Ital J Pediatr*. 2015;41:45. PubMed PMID: 26103969.
- Moya CM, Perez de Nanclares G, Castano L, Potau N, Bilbao JR, Carrascosa A, Bargada M, Coya R, Martul P, Vicens-Calvet E, Santisteban P. Functional study of a novel single deletion in the TITF1/NKX2.1 homeobox gene that produces congenital hypothyroidism and benign chorea but not pulmonary distress. *J Clin Endocrinol Metab*. 2006;91:1832-41. PubMed PMID: 16507635.
- Ngan ES, Lang BH, Liu T, Shum CK, So MT, Lau DK, Leon TY, Cherny SS, Tsai SY, Lo CY, Khoo US, Tam PK, Garcia-Barceló MM. A germline mutation (A339V) in thyroid transcription factor-1 (TITF-1/NKX2.1) in patients with multinodular goiter and papillary thyroid carcinoma. *J Natl Cancer Inst*. 2009;101:162-75. PubMed PMID: 19176457.
- Parnes M, Bashir H, Jankovic J. Is benign hereditary chorea really benign? brain-lung-thyroid syndrome caused by NKX2-1 mutations. *Mov Disord Clin Pract*. 2018; 6:34-9. PubMed PMID: 30746413.
- Peall KJ, Kurian MA. Benign hereditary chorea: an update. *Tremor Other Hyperkinet Mov (N Y)*. 2015;5:314. PubMed PMID: 26196025.
- Peall KJ, Lumsden D, Kneen R, Madhu R, Peake D, Gibbon F, Lewis H, Hedderly T, Meyer E, Robb SA, Lynch B, King MD, Lin JP, Morris HR, Jungbluth H, Kurian MA. Benign hereditary chorea related to NK2-1: expansion of genotypic and phenotypic spectrum. *Dev Med Child Neurol*. 2014;56:642-8. PubMed PMID: 24171694.
- Peca D, Petrini S, Tzialla C, Boldrini R, Morini F, Stronati M, Carnielli VP, Cogo PE, Danhaive O. Altered surfactant homeostasis and recurrent respiratory failure secondary to TTF-1 nuclear targeting defect. *Respir Res*. 2011;12:115. PubMed PMID: 21867529.
- Rahbari R, Wuster A, Lindsay SJ, Hardwick RJ, Alexandrov LB, Turki SA, Dominiczak A, Morris A, Porteous D, Smith B, Stratton MR, Hurles ME, et al. Timing, rates and spectra of human germline mutation. *Nat Genet*. 2016;48:126-33. PubMed PMID: 26656846.
- Richards S, Aziz N, Bale S, Bick D, Das S, Gastier-Foster J, Grody WW, Hegde M, Lyon E, Spector E, Voelkerding K, Rehm HL, et al. Standards and guidelines for the interpretation of sequence variants: a joint consensus recommendation of the American College of Medical Genetics and Genomics and the Association for Molecular Pathology. *Genet Med*. 2015;17:405-24. PubMed PMID: 25741868.
- Rosati A, Berti B, Melani F, Cellini E, Procopio E, Guerrini R. Recurrent drop attacks in early childhood as presenting symptom of benign hereditary chorea caused by TITF 1 gene mutations. *Dev Med Child Neurol*. 2015;57:777-9. PubMed PMID: 25412988.

- Salvatore E, Di Maio L, Filla A, Ferrara AM, Rinaldi C, Sacca F, Peluso S, Macchia PE, Pappata S, De Michele G. Benign hereditary chorea: clinical and neuroimaging features in an Italian family. *Mov Disord* 2010;25:1491-6. PubMed PMID: 20544814.
- Schrag A, Quinn NP, Bhatia KP, Marsden CD. Benign hereditary chorea--entity or syndrome? *Mov Disord* 2000;15:280-8. PubMed PMID: 10752577.
- Stenson PD, Mort M, Ball EV, Chapman M, Evans K, Azevedo L, Hayden M, Heywood S, Millar DS, Phillips AD, Cooper DN. The Human Gene Mutation Database (HGMD®): optimizing its use in a clinical diagnostic or research setting. *Hum Genet*. 2020;139:1197-207. PubMed PMID: 32596782.
- Teissier R, Guillot L, Carre A, Melina M, Stuckens C, Ythier H, Munnich A, Szinnai G, de Blic J, Clement A, Leger J, Castanet M, Epaud R, Polak M. Multiplex ligation-dependent probe amplification improves the detection rate of NKX2.1 mutations in patients affected by brain-lung-thyroid syndrome. *Horm Res Paediatr*. 2012;77:146-51. PubMed PMID: 22488412.
- Thorwarth A, Schnitter-Hubener S, Schrupf P, Muller I, Jyrch S, Dame C, Biebermann H, Katchanov J, Schuelke M, Ebert G, Steininger A, Bonnemann C, Brockmann K, Christen HJ, Crock P, deZegher F, Griese M, Hewitt J, Huber C, Kapelari K, Plecko B, Rating D, Stoeva I, Ropers HH, Gruters A, Ullmann R, Krude H. Comprehensive genotyping and clinical characterization reveals 27 novel NKX2-1 mutations and expand the phenotypic spectrum. *J Med Genet*. 2014;51:375-87. PubMed PMID: 24714694.
- Trevisani V, Predieri B, Madeo SF, Fusco C, Garavelli L, Caraffi S, Iughetti L. Growth hormone deficiency in a child with benign hereditary chorea caused by a de novo mutation of the TITF1/NKX2-1 gene. *J Pediatr Endocrinol Metab*. 2021;35:411-5. PubMed PMID: 34710315.
- Tsai LH, Chen PM, Cheng YW, Chen CY, Sheu GT, Wu TC, Lee H. LKB1 loss by alteration of the NKX2-1/p53 pathway promotes tumor malignancy and predicts poor survival and relapse in lung adenocarcinomas. *Oncogene*. 2014;33:3851-60. PubMed PMID: 23995788.
- Uematsu M, Haginoya K, Kikuchi A, Nakayama T, Numata Y, Kobayashi T, Hino-Fukuo N, Fujiwara I, Kure S. Hypoperfusion in caudate nuclei in patients with brain-lung-thyroid syndrome. *J Neurol Sci*. 2012;315:77-81. PubMed PMID: 22166853.
- Veneziano L, Parkinson MH, Mantuano E, Frontali M, Bhatia KP, Giunti P. A novel de novo mutation of the TITF1/NKX2-1 gene causing ataxia, benign hereditary chorea, hypothyroidism and a pituitary mass in a UK family and review of the literature. *Cerebellum*. 2014;13:588-95. PubMed PMID: 24930029.
- Villamil-Osorio M, Yunis LK, Quintero L, Restrepo-Gualteros S, Yunis JJ, Jaramillo L, Agudelo BI, Ladino Y. [Brain-lung-thyroid syndrome in a newborn with deletion 14q12-q21.1]. *Andes Pediatr*. 2021;92:930-6. PubMed PMID: 35506806.
- Watanabe H, Francis JM, Woo MS, Etemad B, Lin W, Fries DF, Peng S, Snyder EL, Tata PR, Izzo F, Schinzel AC, Cho J, Hammerman PS, Verhaak RG, Hahn WC, Rajagopal J, Jacks T, Meyerson M. Integrated genomic and expression analysis of amplified NKX2-1 in lung adenocarcinoma identifies LMO2 as a functional transcription target. *Genes Dev*. 2013; 27:197-210. PubMed PMID: 23322301.
- Willemsen MA, Breedveld GJ, Wouda S, Otten BJ, Yntema JL, Lammens M, de Vries BB. Brain-thyroid-lung syndrome: a patient with a severe multi-system disorder due to a de novo mutation in the thyroid transcription factor 1 gene. *Eur J Pediatr*, 2005;164:28-30. PubMed PMID: 15517377.
- Young LR, Deutsch GH, Bokulic R, Brody A, Noguee LM. A mutation in TTF1/NKX2.1 is associated with familial neuroendocrine cell hyperplasia of infancy (NEHI). *Chest*. 2013;144:1199-206. PubMed PMID: 23787483.

License

GeneReviews® chapters are owned by the University of Washington. Permission is hereby granted to reproduce, distribute, and translate copies of content materials for noncommercial research purposes only, provided that (i) credit for source (<http://www.genereviews.org/>) and copyright (© 1993-2024 University of Washington) are included with each copy; (ii) a link to the original material is provided whenever the material is published elsewhere on the Web; and (iii) reproducers, distributors, and/or translators comply with the [GeneReviews® Copyright Notice and Usage Disclaimer](#). No further modifications are allowed. For clarity, excerpts of GeneReviews chapters for use in lab reports and clinic notes are a permitted use.

For more information, see the [GeneReviews® Copyright Notice and Usage Disclaimer](#).

For questions regarding permissions or whether a specified use is allowed, contact: admasst@uw.edu.