



## Greig Cephalopolysyndactyly Syndrome

Leslie G Biesecker, MD<sup>1</sup> and Jennifer J Johnston, PhD<sup>1</sup>

Created: July 9, 2001; Revised: February 15, 2024.

### Summary

#### Clinical characteristics

Typical Greig cephalopolysyndactyly syndrome (GCPS) is characterized by macrocephaly, widely spaced eyes associated with increased interpupillary distance, preaxial polydactyly with or without postaxial polydactyly, and cutaneous syndactyly. Developmental delay, intellectual disability, or seizures appear to be uncommon manifestations (~<10%) of GCPS and may be more common in individuals with large (>300-kb) deletions that encompass *GLI3*. Approximately 20% of individuals with GCPS have hypoplasia or agenesis of the corpus callosum.

#### Diagnosis/testing

The diagnosis of GCPS is established in a proband who has typical clinical findings and either a heterozygous pathogenic variant of *GLI3* or a deletion of chromosome 7p14.1 involving *GLI3*.

#### Management

*Treatment of manifestations:* Elective surgical repair of polydactyly with greatest priority given to correction of preaxial polydactyly of the hands; for polydactyly of the feet, the cosmetic benefits and easier fitting of shoes can be outweighed by potential orthopedic complications. Syndactyly which is more than minimal is typically repaired surgically.

*Surveillance:* Monitoring for evidence of increased rate of head growth or neurologic concerns and the need of brain MRI.

#### Genetic counseling

GCPS is inherited in an autosomal dominant manner and is caused by either a pathogenic variant involving *GLI3* or a deletion of chromosome 7p14.1 involving *GLI3*. The proportion of individuals with GCPS caused by *de novo* genetic alteration is unknown. If the causative genetic alteration in the proband is a deletion of

chromosome 7p14.1, the parents of the proband are at risk of having a balanced chromosome rearrangement; if a parent has a balanced structural chromosome rearrangement, the risk to sibs of a proband depends on the specific chromosome rearrangement and the possibility of other variables. Each child of an individual with GCPS has a 50% chance of inheriting the GCPS-causing genetic alteration. Prenatal testing for pregnancies at increased risk is possible if the GCPS-causing genetic alteration has been identified in an affected family member or a parent is known to have a balanced structural chromosome rearrangement involving 7p14.1. The reliability of ultrasound examination for prenatal diagnosis is unknown.

## Diagnosis

### Suggestive Findings

Greig cephalopolysyndactyly syndrome (GCPS) **should be suspected** in individuals with the following features:

- Macrocephaly
- Widely spaced eyes associated with increased interpupillary distance (>97th centile)
- Preaxial polydactyly with or without postaxial polydactyly
- Cutaneous syndactyly

### Establishing the Diagnosis

The diagnosis of GCPS is **established** in a proband who has typical clinical findings and **one of the following** on molecular genetic testing (see Table 1):

- A heterozygous pathogenic (or likely pathogenic) variant of *GLI3* (~80% of affected individuals) [Wild et al 1997, Debeer et al 2007, Johnston et al 2010, Jamsheer et al 2012, Démurger et al 2015]
- A heterozygous deletion of chromosome 7p14.1 involving *GLI3* (~20% of affected individuals) [Debeer et al 2007, Johnston et al 2010, Jamsheer et al 2012, Démurger et al 2015]

Note: (1) Per ACMG/AMP variant interpretation guidelines, the terms "pathogenic variant" and "likely pathogenic variant" are synonymous in a clinical setting, meaning that both are considered diagnostic and can be used for clinical decision making [Richards et al 2015]. Reference to "pathogenic variants" in this *GeneReview* is understood to include likely pathogenic variants. (2) Identification of a heterozygous *GLI3* variant of uncertain significance does not establish or rule out the diagnosis.

Molecular genetic testing approaches can include a combination of **gene-targeted testing** (single-gene testing, multigene panel) and **comprehensive genomic testing** (chromosomal microarray analysis [CMA], exome sequencing, exome array, genome sequencing) depending on the phenotype.

Gene-targeted testing requires that the clinician determine which gene(s) are likely involved, whereas genomic testing does not. Individuals with the distinctive findings of GCPS described in Suggestive Findings are likely to be diagnosed using gene-targeted testing (see Option 1), whereas those with a phenotype indistinguishable from many other inherited disorders with polydactyly and/or macrocephaly are more likely to be diagnosed using genomic testing (see Option 2).

Note: If the affected individual has significant developmental delay or intellectual disability or if there is a history of recurrent pregnancy losses for the parents of the proband, CMA should be considered first, followed by sequence analysis of *GLI3*.

### Option 1

When the phenotypic findings suggest the diagnosis of GCPS, molecular genetic testing approaches can include **single-gene testing**, or use of a **multigene panel**:

- **Single-gene testing.** Sequence analysis of *GLI3* is performed first to detect missense, nonsense, and splice site variants and small intragenic deletions/insertions. Depending on the sequencing method used, single-exon, multiexon, or whole-gene deletions/duplications may not be detected. If no variant is detected by the sequencing method used, the next step is to perform gene-targeted deletion/duplication analysis to detect exon and whole-gene deletions or duplications.

Note: A small number of individuals with translocations involving 7p14.1 have been reported [Tommerup & Nielsen 1983, Krüger et al 1989, Debeer et al 2003]. **Karyotype** may be considered when single gene testing is negative.

- **A multigene panel** that includes *GLI3* and other genes of interest (see Differential Diagnosis) is most likely to identify the genetic cause of the condition while limiting identification of variants of uncertain significance and pathogenic variants in genes that do not explain the underlying phenotype. Note: (1) The genes included in the panel and the diagnostic sensitivity of the testing used for each gene vary by laboratory and are likely to change over time. (2) Some multigene panels may include genes not associated with the condition discussed in this *GeneReview*. (3) In some laboratories, panel options may include a custom laboratory-designed panel and/or custom phenotype-focused exome analysis that includes genes specified by the clinician. (4) Methods used in a panel may include sequence analysis, deletion/duplication analysis, and/or other non-sequencing-based tests. For this disorder a multigene panel that also includes deletion/duplication analysis is recommended (see Table 1).

For an introduction to multigene panels click [here](#). More detailed information for clinicians ordering genetic tests can be found [here](#).

## Option 2

When the phenotype is indistinguishable from many other inherited disorders characterized by polydactyly and/or macrocephaly, **comprehensive genomic testing** (which does not require the clinician to determine which gene[s] are likely involved) is the best option. **Exome sequencing** is most commonly used; **genome sequencing** is also possible.

If exome sequencing is not diagnostic, **exome array** (when clinically available) may be considered to detect (multi)exon deletions or duplications that may not be detected by sequence analysis.

For an introduction to comprehensive genomic testing click [here](#). More detailed information for clinicians ordering genomic testing can be found [here](#).

**Table 1.** Molecular Genetic Testing Used in Greig Cephalopolysyndactyly Syndrome

Gene <sup>1</sup>	Method	Proportion of Probands with a Pathogenic Variant <sup>2</sup> Detectable by Method
<i>GLI3</i>	Sequence analysis <sup>3</sup>	~80% <sup>4</sup>
	Gene-targeted deletion/duplication analysis <sup>5</sup>	~20% <sup>4</sup>
	Karyotype <sup>6</sup>	Rare <sup>6</sup>

1. See Table A. Genes and Databases for chromosome locus and protein.

2. See Molecular Genetics for information on variants detected in this gene.

3. Sequence analysis detects variants that are benign, likely benign, of uncertain significance, likely pathogenic, or pathogenic. Variants may include missense, nonsense, and splice site variants and small intragenic deletions/insertions. For issues to consider in interpretation of sequence analysis results, click [here](#).

4. Johnston et al [2005], Debeer et al [2007], Johnston et al [2010], Démurger et al [2015]

5. Gene-targeted deletion/duplication analysis detects intragenic deletions or duplications. Methods used may include a range of techniques such as quantitative PCR, long-range PCR, multiplex ligation-dependent probe amplification (MLPA), and a gene-targeted microarray designed to detect single-exon deletions or duplications. Some laboratories offer deletion/duplication analysis using exome or genome sequence data. Gene-targeted deletion/duplication testing will detect deletions ranging from a single exon to the whole gene; however, breakpoints of large deletions and/or deletion of adjacent genes (e.g., those described by Johnston et al [2010] and Démurger et al [2015]) may not be detected by these methods.

6. A small number of individuals with translocations involving 7p14.1 have been reported [Tommerup & Nielsen 1983, Krüger et al 1989, Debeer et al 2003].

## Clinical Characteristics

### Clinical Description

To date, more than 200 individuals with Greig cephalopolysyndactyly syndrome (GCPS) have been reported with a pathogenic variant in *GLI3* [Williams et al 1997, Kalff-Suske et al 1999, Debeer et al 2003, Johnston et al 2005, Debeer et al 2007, Schulz et al 2008, Johnston et al 2010, Hurst et al 2011, Jamsheer et al 2012, Patel et al 2014, Démurger et al 2015, Abdullah et al 2019, Siavriené et al 2019, Khan et al 2021, Polivka et al 2021, Sczakiel et al 2021, Garcia-Rodriguez et al 2022]. The following description of the phenotypic features associated with GCPS is based on these reports.

**Table 2.** Select Features of Greig Cephalopolysyndactyly Syndrome

Feature	% of Persons w/Feature	Comment
Macrocephaly	50%	
Widely spaced eyes	50%	
Preaxial polydactyly	90%	More common in the feet
Markedly broad hallux	25%	
Markedly broad thumb	30%	
Postaxial polydactyly	50%	More common in the hands
Cutaneous syndactyly	75%	

**Macrocephaly.** Occipitofrontal (head) circumference (OFC) is greater than 97th centile compared to appropriate age- and sex-matched normal standards [Allanson et al 2009]. Note: An enlarged OFC must be interpreted with caution in families in which a parent (or parents) of the proband has benign familial macrocephaly (OMIM 153470).

Some individuals with GCPS have a high anterior hairline, and a prominent (or bossed) forehead.

**Widely spaced eyes** defined as interpupillary distance  $>2$  SD above the mean (newborns 27-41 weeks' gestational age), interpupillary distance  $>97$ th centile (individuals age 0-15 years), or a subjectively increased interpupillary distance [Hall et al 2009]. Increased inner canthal distance (i.e., telecanthus, or apparent widely spaced eyes) may be present as well but is not as distinctive a finding as increased interpupillary distance. Increased interpupillary distance is often associated with a wide nasal bridge.

### Limb anomalies

- **Preaxial polydactyly.** At least one limb should manifest one of the following [Biesecker et al 2009]:
  - Preaxial polydactyly (duplication of all or part of the first ray)
  - A markedly broad hallux (visible increase in width of the hallux without an increase in the dorso-ventral dimension)
  - A markedly broad thumb (increased thumb width without increased dorso-ventral dimension)
- Other limbs may manifest preaxial or postaxial polydactyly and some limbs may have five normal digits. The postaxial polydactyly may be type A, type B, or intermediate forms.
- Postaxial polydactyly type A (PAP-A) is the presence of a well-formed digit on the ulnar or fibular aspect of the limb.
- Postaxial polydactyly type B (PAP-B) is the presence of a rudimentary digit or nubbin in the same location. The finding of postaxial polydactyly type B must be evaluated critically when present in an individual of west-central African descent as that feature is a common variant (1% prevalence).
- Some individuals have widening of the first digit apparent only on radiograph. This is difficult to assess when diagnosing a proband.
- **Cutaneous syndactyly.** The cutaneous syndactyly may be partial or complete; in occasional severely affected individuals, parts of the distal phalanges may be fused.

**Cognitive/neurologic concerns.** Developmental delay, intellectual disability, or seizures appear to be uncommon manifestations ( $\sim <10\%$ ) of GCPS. These complications are more likely if the child has central nervous system malformations (rare) or hydrocephalus (uncommon), and they may be more common in individuals with large ( $>300$ -kb) deletions that encompass *GLI3* [Johnston et al 2007].

**Hypoplasia/agenesis of the corpus callosum.** Approximately 20% of individuals with GCPS have hypoplasia or agenesis of the corpus callosum.

**Prognosis.** Several large families have been reported as having a mild form of GCPS with excellent general health and normal longevity.

## Genotype-Phenotype Correlations

Individuals who have GCPS associated with a large ( $>300$  kb) deletion have a more severe phenotype than those with single-nucleotide variants in *GLI3* [Kroisel et al 2001, Johnston et al 2007]. Individuals with large deletions appear to have a higher incidence of intellectual disability, seizures, and central nervous system anomalies. This phenomenon is presumably caused by haploinsufficiency of multiple genes in the vicinity of *GLI3*.

Hypoplasia/agenesis of the corpus callosum may be more common in individuals with truncating variants in the 3' end of the gene [Démurger et al 2015] or individuals with large deletions that encompass *GLI3* [Johnston et al 2003].

Note: GCPS has an allelic disorder, **Pallister-Hall syndrome** (PHS). Frameshift variants in *GLI3* in the first third of the gene are only known to cause GCPS (see Figure 1B). Frameshift variants in the middle third of the gene cause PHS and uncommonly cause GCPS. A single truncating variant in the middle of the PHS region, c.2374C>T (p.Arg792Ter), can cause GCPS and has been observed in nine apparently unrelated families [Johnston et al 2005, Abdullah et al 2019, Sczakiel et al 2021]. Frameshift variants in the final third of the gene

cause GCPS. There is no apparent correlation of the variant position within each of the three regions and the severity of the respective phenotype.

## Penetrance

Apparent non-penetrance has been reported [Debeer et al 2003, Démurger et al 2015]. However, it is difficult to estimate the rate of non-penetrance because the genetic status of the parents is often unknown in simplex families (i.e., families in which the proband is the only affected individual).

## Nomenclature

The term "Greig syndrome" describes the dyad of widely spaced eyes and macrocephaly. Because that dyad of anomalies is nonspecific, the term should not be used as a synonym for GCPS [Gorlin et al 2001].

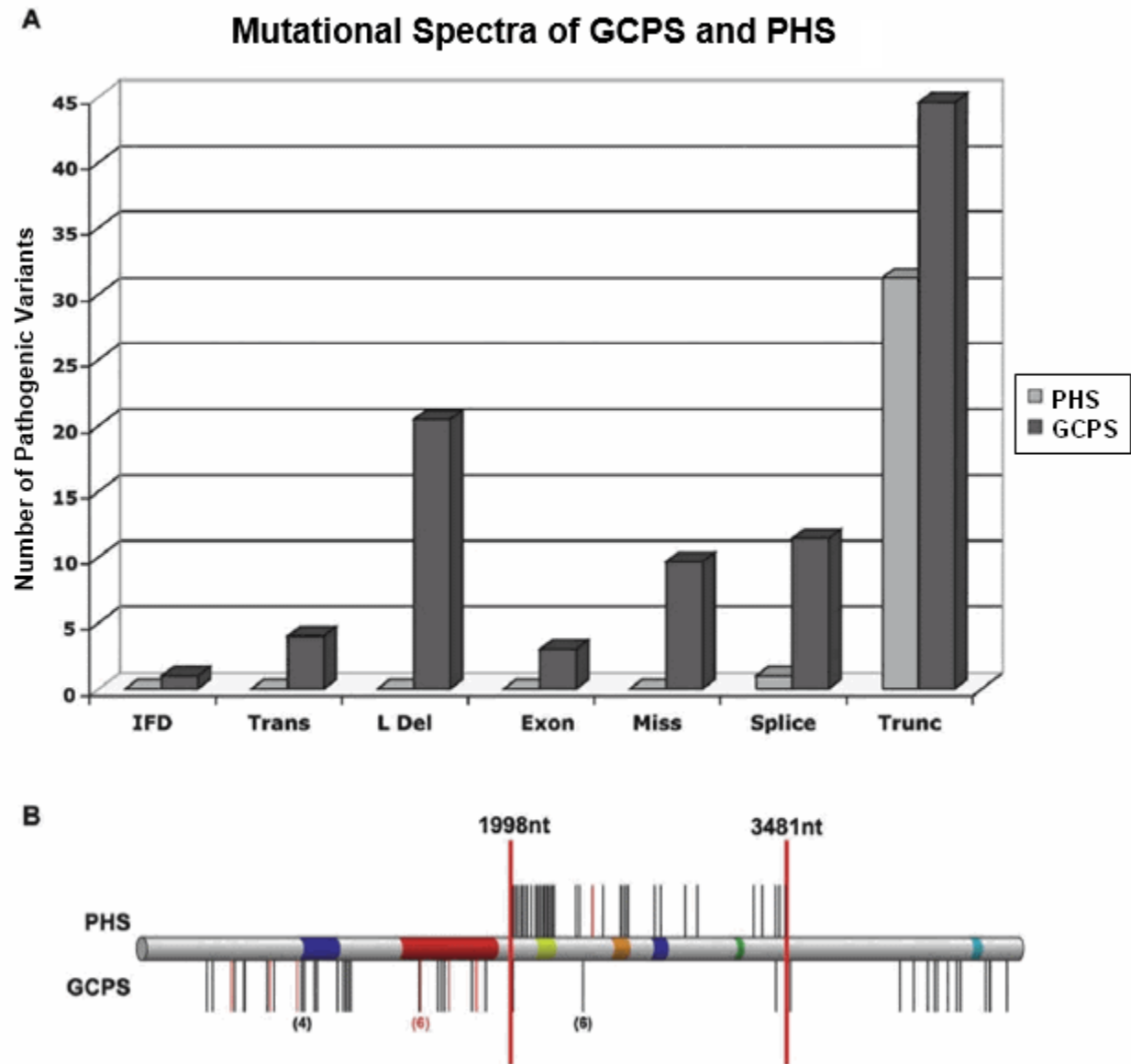
## Prevalence

GCPS is rare; the prevalence is unknown. Approximately 200 affected individuals are known to these authors. It is suspected that many individuals with preaxial polydactyly with syndactyly and mild craniofacial features are misdiagnosed as having isolated preaxial polydactyly instead of GCPS (see Genetically Related Disorders, PPD-IV); however, the distinction may be semantic [Biesecker 2008].

## Genetically Related (Allelic) Disorders

Other phenotypes known to be associated with germline pathogenic variants in *GLI3* are summarized in Table 3.

Note: Haploinsufficiency for *GLI3* causes GCPS, whereas truncating variants in the middle third of the gene, 3' of the zinc finger domain of *GLI3*, generally cause PHS [Johnston et al 2005] (Figure 1A).



**Figure 1.** A. The spectra of GCPS-associated and PHS-associated pathogenic variants are distinct. GCPS is caused by pathogenic variants of all types, whereas PHS is only caused by truncating variants and one splice variant that generates a frameshift and a truncation.

B. Within the frameshift variant category there is a correlation of the position of the truncation and the phenotype. GCPS is primarily caused by pathogenic variants 5' of nt 1998 and 3' of 3481, whereas PHS is exclusively caused by truncations between 1998 and 3481. Note that a single truncating variant in the PHS region can cause GCPS and has been observed in six apparently unrelated families.

Reproduced with permission from Johnston et al [2005]

**Table 3.** *GLI3* Allelic Disorders

Disorder	Clinical Features	Comment
Pallister-Hall syndrome (PHS)	<ul style="list-style-type: none"> <li>Wide range of severity</li> <li>Central or postaxial polydactyly, hypothalamic hamartoma, bifid epiglottis, imperforate anus or anal stenosis, &amp; other anomalies</li> <li>In a minority of individuals: multiple severe anomalies (e.g., pituitary dysplasia w/pan hypopituitarism &amp; laryngeal clefts or other airway anomalies, which may be life threatening in the neonatal period)</li> </ul>	It is often wrongly assumed that PHS is severe & GCPS is mild; most individuals w/PHS are mildly affected, w/polydactyly, asymptomatic bifid epiglottis, & hypothalamic hamartoma
Postaxial polydactyly type A (PAP-A) (OMIM 174200)	Limb malformation limited to presence of a single, well-formed supernumerary postaxial digit on 1 or both hands & feet	There is some controversy as to whether PAP-A is distinct from PHS or is instead a variant of PHS w/ mild, subtle, & asymptomatic bifid epiglottis, hypothalamic hamartoma, anal stenosis, & other signs.
Preaxial polydactyly type IV (PPD-IV) (OMIM 174700)	<ul style="list-style-type: none"> <li>Preaxial polydactyly of hands &amp;/or feet w/o other malformations (typically the same pattern of syndactyly in hands &amp; feet as those w/GCPS)</li> <li>Severity is highly variable. <sup>1</sup></li> </ul>	<ul style="list-style-type: none"> <li>PPD-IV is essentially GCPS w/o craniofacial manifestations.</li> <li>Because macrocephaly occurs in the general population &amp; is common in GCPS, the presence of macrocephaly in a person w/ apparently isolated PPD-IV may be difficult to interpret.</li> </ul>
Acrocallosal syndrome	Postaxial polydactyly, macrocephaly, agenesis of the corpus callosum, & severe developmental delay	2 individuals diagnosed w/acrocallosal syndrome have been reported w/missense variants in <i>GLI3</i> . <sup>2</sup>

GCPS = Greig cephalopolysyndactyly syndrome

*GLI3* allelic disorders described in this table are inherited in an autosomal dominant manner.

1. Everman [2006]

2. Elson et al [2002], Speksnijder et al [2013]

## Differential Diagnosis

**Table 4.** Genes of Interest in the Differential Diagnosis of Greig Cephalopolysyndactyly Syndrome

Gene(s)	Disorder	MOI	Clinical Features	Comment
<i>EFNB1</i>	Craniofrontonasal dysplasia (OMIM 304110)	XL <sup>1</sup>	<ul style="list-style-type: none"> <li>In females: frontonasal dysplasia, craniofacial asymmetry, craniosynostosis, bifid nasal tip, grooved nails, wiry hair, abnormalities of the thoracic skeleton</li> <li>In males: widely spaced eyes</li> </ul>	Craniofrontonasal dysplasia facial features in females are similar to those of GCPS. <sup>2</sup>
<i>KIF7</i>	Acrocallosal syndrome (ACLS) (OMIM 200990)	AR	Pre- or postaxial polydactyly, cutaneous syndactyly, agenesis of the corpus callosum (rare in GCPS), widely spaced eyes, macrocephaly, moderate-to-severe ID, intracerebral cysts, seizures, & umbilical & inguinal hernias	The milder end of the ACLS phenotype may overlap w/the severe end of the GCPS phenotype (See Genotype-Phenotype Correlations.).



Table 4. continued from previous page.

Gene(s)	Disorder	MOI	Clinical Features	Comment
<i>OFD1</i> <sup>3</sup>	Oral-facial-digital syndrome 1 (OFD1) (OMIM 311200)	XL	Preaxial polydactyly, widely spaced eyes, syndactyly, agenesis of the corpus callosum (rare in GCPS), cerebellar agenesis, intracerebral cysts, cleft palate, cleft lip, oral frenula, polycystic kidney disease	The milder end of the OFD1 phenotype may overlap w/the GCPS phenotype (See Genotype-Phenotype Correlations.).

AD = autosomal dominant; AR = autosomal recessive; GCPS = Greig cephalopolysyndactyly syndrome; ID = intellectual disability; MOI = mode of inheritance; XL = X-linked

1. Inheritance of *EFNB1* craniofrontonasal dysplasia is unusual for an X-linked disorder: heterozygous females are severely affected and hemizygous males are almost asymptomatic.

2. Gorlin et al [2001]

3. Oral-facial-digital syndrome type 1 is caused by pathogenic variants in *OFD1*; see [Phenotypic Series: Orofaciodigital syndrome](#) for other genes associated with this phenotype in OMIM.

## Management

### Evaluations Following Initial Diagnosis

To establish the extent of disease and needs in an individual diagnosed with Greig cephalopolysyndactyly syndrome (GCPS), the evaluations summarized in Table 5 (if not performed as part of the evaluation that led to the diagnosis) are recommended.

Table 5. Greig Cephalopolysyndactyly Syndrome: Recommended Evaluations Following Initial Diagnosis

System/Concern	Evaluation	Comment
<b>Limb anomalies</b>	Dysmorphology exam	Evaluate for any other malformations.
	Orthopedic eval	Incl radiographs to understand extent of limb anomalies.
	Occupational therapy / developmental eval	Determine any functional limitations that would benefit from therapy.
<b>Potential for developmental delay</b>	Developmental screening	Consider brain imaging if significant delays noted.
<b>Other</b>	Consultation w/clinical geneticist &/or genetic counselor	

### Treatment of Manifestations

Table 6. Greig Cephalopolysyndactyly Syndrome: Treatment of Manifestations

Manifestation/Concern	Treatment	Considerations/Other
<b>Polydactyly</b>	Surgical repair	<ul style="list-style-type: none"> <li>Undertaken on an elective basis</li> <li>Preaxial polydactyly of the hands is considered higher priority for surgical correction than postaxial polydactyly of the hand or any type of polydactyly of the foot due to importance of early &amp; proper development of prehensile grasp.</li> <li>As for any malformation of the feet, surgical correction must be carefully considered; cosmetic benefits &amp; easier fitting of shoes can be outweighed by potential orthopedic complication.</li> </ul>
<b>Cutaneous syndactyly</b>	Surgical repair	Undertaken if syndactyly is more than minimal

Table 6. continued from previous page.

Manifestation/Concern	Treatment	Considerations/Other
<b>Seizures</b>	ASM therapy as needed	

ASM = anti-seizure medication

## Surveillance

Table 7. Greig Cephalopolysyndactyly Syndrome: Recommended Surveillance

System/Concern	Evaluation	Frequency
<b>Macrocephaly</b>	Review rate of head growth in infant & child; if ↑ faster than normal or if neurologic concerns arise, brain MRI is indicated.	At each visit or at least annually

## Agents/Circumstances to Avoid

As is true for any malformation of the feet, surgical correction must be carefully considered. Cosmetic benefits and easier fitting of shoes can be outweighed by potential orthopedic complications.

## Evaluation of Relatives at Risk

See Genetic Counseling for issues related to testing of at-risk relatives for genetic counseling purposes.

## Therapies Under Investigation

Search [ClinicalTrials.gov](https://clinicaltrials.gov) in the US and [EU Clinical Trials Register](https://clinicaltrialsregister.eu) in Europe for access to information on clinical studies for a wide range of diseases and conditions. Note: There may not be clinical trials for this disorder.

## Genetic Counseling

*Genetic counseling is the process of providing individuals and families with information on the nature, mode(s) of inheritance, and implications of genetic disorders to help them make informed medical and personal decisions. The following section deals with genetic risk assessment and the use of family history and genetic testing to clarify genetic status for family members; it is not meant to address all personal, cultural, or ethical issues that may arise or to substitute for consultation with a genetics professional. —ED.*

## Mode of Inheritance

Greig cephalopolysyndactyly syndrome (GCPS) is inherited in an autosomal dominant manner and is caused by either a pathogenic variant involving *GLI3* or a deletion of chromosome 7p14.1 involving *GLI3*.

**Balanced chromosome rearrangement.** If the causative genetic alteration in the proband is a deletion of chromosome 7p14.1 [Schulz et al 2008], the parents of the proband are at risk of having a balanced chromosome rearrangement and should be offered chromosome analysis. If a parent has a balanced structural chromosome rearrangement, the risk to sibs is increased and depends on the specific chromosome rearrangement and the possibility of other variables.

## Risk to Family Members

### Parents of a proband

- Some individuals diagnosed with GCPS have the disorder as the result of a genetic alteration inherited from a parent.
- Some individuals diagnosed with GCPS have the disorder as the result of a *de novo* GCPS-causing genetic alteration. The proportion of individuals with GCPS caused by *de novo* genetic alteration is unknown, as the frequency of subtle signs of the disorder in parents has not been thoroughly evaluated and molecular genetic data are insufficient.
- Recommendations for the evaluation of parents of a child with GCPS and no known family history of GCPS consist of clinical examination and radiographs of hands and feet unless physical signs suggest the need for other studies (e.g., neuroimaging for possible hydrocephalus in a parent). Molecular genetic testing of the parents is indicated if the GCPS-causing genetic alteration has been identified in the proband.
- If the proband has a known genetic alteration that cannot be detected in the leukocyte DNA of either parent, possible explanations include a *de novo* alteration in the proband or germline mosaicism in a parent.\* Parental mosaicism has been reported in rare families [Démurger et al 2015].  
\* Misattributed parentage can also be explored as an alternative explanation for an apparent *de novo* pathogenic variant.
- The family history of some individuals diagnosed with GCPS may appear to be negative because of failure to recognize the disorder in family members or reduced penetrance in a heterozygous parent. Therefore, an apparently negative family history cannot be confirmed unless molecular genetic testing has been performed on the parents of the proband.
- If the parent is the individual in whom the pathogenic variant first occurred, the parent may have somatic and germline mosaicism for the pathogenic variant and may be mildly/minimally affected; affected offspring of a parent with mosaicism would be nonmosaic and thus could have a more severe phenotype than the parent.

**Sibs of a proband.** The risk to the sibs of a proband depends on the clinical/genetic status of the proband's parents:

- If a parent of the proband is affected and/or is known to have the genetic alteration identified in the proband, the risk to the sibs is 50%. (See Mode of Inheritance for recurrence risk information when a parent is a carrier of a balanced chromosome rearrangement.) The prognosis in a sib who inherits a familial genetic alteration is based on the degree of severity present in the family, as intrafamilial variability in GCPS appears to be low.
- If the parents of a proband are clinically unaffected but their genetic status is unknown (either because the genetic etiology in the proband is unknown or because the parents have not undergone molecular genetic testing), the risk to the sibs of a proband appears to be low. However, sibs of a proband with clinically unaffected parents are still presumed to be at increased risk for GCPS because of the possibility of reduced penetrance in a heterozygous parent or the possibility of parental germline mosaicism.

**Offspring of a proband.** Each child of an individual with GCPS has a 50% chance of inheriting the GCPS-causing genetic alteration.

**Other family members.** The risk to other family members depends on the clinical/genetic status of the proband's parents: if a parent is affected and/or is known to have a genetic alteration associated with GCPS or an increased risk of GCPS (i.e., a balanced structural chromosome rearrangement), the parent's family members may be at risk.

## Related Genetic Counseling Issues

### Family planning

- The optimal time for determination of genetic risk and discussion of the availability of prenatal/preimplantation genetic testing is before pregnancy.
- It is appropriate to offer genetic counseling (including discussion of potential risks to offspring and reproductive options) to young adults who are affected.

**DNA banking.** Because it is likely that testing methodology and our understanding of genes, pathogenic mechanisms, and diseases will improve in the future, consideration should be given to banking DNA from probands in whom a molecular diagnosis has not been confirmed (i.e., the causative pathogenic mechanism is unknown). For more information, see Huang et al [2022].

## Prenatal Testing and Preimplantation Genetic Testing

**Genetic testing.** If the GCPS-causing genetic alteration has been identified in an affected family member or a parent is known to have a balanced structural chromosome rearrangement involving 7p14.1, prenatal and preimplantation genetic testing are possible.

**Ultrasound examination.** In pregnancies at 50% risk, prenatal ultrasound examination may detect polydactyly, macrocephaly, or other central nervous system abnormalities such as hydrocephalus. However, a normal ultrasound examination does not eliminate the possibility of GCPS in the fetus.

Differences in perspective may exist among medical professionals and within families regarding the use of prenatal testing. While most centers would consider use of prenatal testing to be a personal decision, discussion of these issues may be helpful.

## Resources

*GeneReviews staff has selected the following disease-specific and/or umbrella support organizations and/or registries for the benefit of individuals with this disorder and their families. GeneReviews is not responsible for the information provided by other organizations. For information on selection criteria, click [here](#).*

- **National Library of Medicine Genetics Home Reference**  
[Greig cephalopolysyndactyly syndrome](#)
- **Children's Craniofacial Association**  
**Phone:** 800-535-3643  
**Email:** [contactCCA@ccakids.com](mailto:contactCCA@ccakids.com)  
[www.ccakids.org](http://www.ccakids.org)
- **Face Equality International**  
United Kingdom  
[faceequalityinternational.org](http://faceequalityinternational.org)
- **FACES: National Craniofacial Association**  
**Phone:** 800-332-2373; 423-266-1632  
**Email:** [info@faces-cranio.org](mailto:info@faces-cranio.org)  
[www.faces-cranio.org](http://www.faces-cranio.org)

## Molecular Genetics

Information in the Molecular Genetics and OMIM tables may differ from that elsewhere in the GeneReview: tables may contain more recent information. —ED.

**Table A.** Greig Cephalopolysyndactyly Syndrome: Genes and Databases

Gene	Chromosome Locus	Protein	Locus-Specific Databases	HGMD	ClinVar
<i>GLI3</i>	7p14.1	Transcriptional activator GLI3	GLI3 @ LOVD	GLI3	GLI3

Data are compiled from the following standard references: gene from [HGNC](#); chromosome locus from [OMIM](#); protein from [UniProt](#). For a description of databases (Locus Specific, HGMD, ClinVar) to which links are provided, click [here](#).

**Table B.** OMIM Entries for Greig Cephalopolysyndactyly Syndrome ([View All in OMIM](#))

165240	GLI-KRUPPEL FAMILY MEMBER 3; GLI3
175700	GREIG CEPHALOPOLYSYNDACTYLY SYNDROME; GCPS

## Molecular Pathogenesis

*GLI3* encodes a zinc finger transcription factor that is downstream of sonic hedgehog in the SHH pathway (*SHH-PTCH1-SMO-GLI1, GLI2, GLI3*) [Villavicencio et al 2000]. The various GLI proteins in turn regulate genes further downstream in this pathway, including *HNF3β*, bone morphogenetic proteins, and other as-yet-unknown targets. The human gene is similar to the mouse paralog *Gli3* and the vertebrate *GLI* gene family is homologous to the *Drosophila melanogaster* gene *cubitus interruptus (ci)*.

**Mechanism of disease causation.** The most common, if not sole, pathogenic mechanism for Greig cephalopolysyndactyly syndrome (GCPS) is haploinsufficiency. Deletions that remove the entire gene cause a GCPS phenotype that is not known to be different from that caused by single-nucleotide nonsense or frameshift variants. In addition, mouse models support the hypothesis that haploinsufficiency is the mechanism. Although it is clear that haploinsufficiency of *GLI3* can cause GCPS, the pathogenic mechanism of 3' frameshift or nonsense variants and missense variants is not clear.

***GLI3*-specific laboratory technical considerations.** As large deletions make up a considerable percentage of variants in GCPS, deletion/duplication analysis should be incorporated into any testing strategy.

**Table 8.** *GLI3* Pathogenic Variants Referenced in This GeneReview

Reference Sequences	DNA Nucleotide Change	Predicted Protein Change	Comment [Reference]
<a href="#">NM_000168.6</a> <a href="#">NP_000159.3</a>	c.2374C>T	p.Arg792Ter	Truncating variant in the PHS region that can cause GCPS; observed in 6 apparently unrelated families [Johnston et al 2005]

GCPS = Greig cephalopolysyndactyly syndrome; PHS = Pallister-Hall syndrome

Variants listed in the table have been provided by the authors. *GeneReviews* staff have not independently verified the classification of variants.

*GeneReviews* follows the standard naming conventions of the Human Genome Variation Society ([varnomen.hgvs.org](http://varnomen.hgvs.org)). See [Quick Reference](#) for an explanation of nomenclature.

## Chapter Notes

### Author Notes

Leslie G Biesecker's web page

### Author History

Leslie H Biesecker, MD (2001-present)

Jennifer J Johnston, PhD (2020-present)

### Revision History

- 15 February 2024 (jj) Revision: information regarding *GLI3* pathogenic variant p.Arg792Ter added to Genotype-Phenotype Correlations and Molecular Genetics; added references (Siavriené et al [2019], Khan et al [2021], Polivka et al [2021], Sczakiel et al [2021], Garcia-Rodriguez et al [2022])
- 7 May 2020 (ha) Comprehensive update posted live
- 19 June 2014 (me) Comprehensive update posted live
- 30 April 2009 (me) Comprehensive update posted live
- 20 September 2005 (me) Comprehensive update posted live
- 25 August 2003 (me) Comprehensive update posted live
- 9 July 2001 (me) Review posted live
- 20 February 2001 (lgb) Original submission

Note: Pursuant to 17 USC Section 105 of the United States Copyright Act, the *GeneReview* "Greig Cephalopolysyndactyly Syndrome" is in the public domain in the United States of America.

## References

### Literature Cited

- Abdullah, Yousaf M, Azeem Z, Bilal M, Liaqat K, Hussain S, Ahmad F, Ghous T, Ullah A, Ahmad W. Variants in *GLI3* cause Greig cephalopolysyndactyly syndrome. *Genet Test Mol Biomarkers*. 2019;23:744–50. PubMed PMID: 31573334.
- Allanson JE, Cunniff C, Hoyme HE, McGaughran J, Muenke M, Neri G. Elements of morphology: standard terminology for the head and face. *Am J Med Genet A*. 2009;149A:6–28. PubMed PMID: 19125436.
- Biesecker LG. The Greig cephalopolysyndactyly syndrome. *Orphanet J Rare Dis*. 2008;3:10. PubMed PMID: 18435847.
- Biesecker LG, Aase JM, Clericuzio C, Gurrieri F, Temple IK, Toriello H. Elements of morphology: standard terminology for the hands and feet. *Am J Med Genet A*. 2009;149A:93–127. PubMed PMID: 19125433.
- Debeer P, Peeters H, Driess S, De Smet L, Freese K, Matthijs G, Bornholdt D, Devriendt K, Grzeschik KH, Fryns JP, Kalff-Suske M. Variable phenotype in Greig cephalopolysyndactyly syndrome: clinical and radiological findings in 4 independent families and 3 sporadic cases with identified *GLI3* mutations. *Am J Med Genet A*. 2003;120A:49–58. PubMed PMID: 12794692.
- Debeer P, Devriendt K, De Smet L, Deravel T, Gonzalez-Meneses A, Grzeschik KH, Fryns JP. The spectrum of hand and foot malformations in patients with Greig cephalopolysyndactyly. *J Child Orthop*. 2007;1:143–50. PubMed PMID: 19308487.
- Démurger F, Ichkou A, Mougou-Zerelli S, Le Merrer M, Goudefroye G, Delezoide AL, Quelin C, Manouvrier S, Baujat G, Fradin M, Pasquier L, Megarbane A, Faivre L, Baumann C, Nampoothiri S, Roume J, Isidor B,

- Lacombe D, Delrue MA, Mercier S, Philip N, Schaefer E, Holder M, Krause A, Laffargue F, Sinico M, Amram D, Andre G, Liquier A, Rossi M, Amiel J, Giuliano F, Boute O, Dieux-Coeslier A, Jacquemont ML, Afenjar A, Van Maldergem L, Lackmy-Port-Lis M, Vincent-Delorme C, Chauvet ML, Cormier-Daire V, Devisme L, Genevieve D, Munnich A, Viot G, Raoul O, Romana S, Gonzales M, Encha-Razavi F, Odent S, Vekemans M, Attie-Bitach T. New insights into genotype-phenotype correlation for GLI3 mutations. *Eur J Hum Genet.* 2015;23:92–102. PubMed PMID: 24736735.
- Elson E, Perveen R, Donnai D, Wall S, Black GC. De novo GLI3 mutation in acrocallosal syndrome: broadening the phenotypic spectrum of GLI3 defects and overlap with murine models. *J Med Genet.* 2002;39:804–6. PubMed PMID: 12414818.
- Everman DB. Hands and feet. In: Stevenson RE, Hall JG, eds. *Human Malformations and Related Anomalies.* 2 ed. New York: Oxford University Press; 2006:935-96.
- Garcia-Rodriguez R, Rodriguez-Rodriguez R, Garcia-Delgado R, Romero-Requejo A, Medina-Castellano M, Garcia Cruz L, Santana Rodriguez A, Garcia-Hernandez JA. Prenatal diagnosis of Greig cephalopolysyndactyly syndrome. When to suspect it. *J Matern Fetal Neonatal Med.* 2022;35:2162-5. PubMed PMID: 32495660.
- Gorlin RJ, Cohen MM Jr, Hennekam RCM. Greig cephalopolysyndactyly syndrome. In: Gorlin RJ, Cohen MM Jr, Hennekam RCM, eds. *Syndromes of the Head and Neck.* New York: Oxford University Press; 2001:995-6.
- Hall BD, Graham JM Jr, Cassidy SB, Opitz JM. Elements of morphology: standard terminology for the periorbital region. *Am J Med Genet A.* 2009;149A:29–39. PubMed PMID: 19125427.
- Huang SJ, Amendola LM, Sternen DL. Variation among DNA banking consent forms: points for clinicians to bank on. *J Community Genet.* 2022;13:389-97. PubMed PMID: 35834113.
- Hurst JA, Jenkins D, Vasudevan PC, Kirchoff M, Skovby F, Rieubland C, Gallati S, Rittinger O, Kroisel PM, Johnson D, Biesecker LG, Wilkie AO. Metopic and sagittal synostosis in Greig cephalopolysyndactyly syndrome: five cases with intragenic mutations or complete deletions of GLI3. *Eur J Hum Genet.* 2011;19:757–62. PubMed PMID: 21326280.
- Jamsheer A, Sowinska A, Trzeciak T, Jamsheer-Bratkowska M, Geppert A, Latos-Bielenska A. Expanded mutational spectrum of the GLI3 gene substantiates genotype-phenotype correlations. *J Appl Genet.* 2012;53:415–22. PubMed PMID: 22903559.
- Johnston JJ, Sapp JC, Turner JT, Amor D, Aftimos S, Aleck KA, Bocian M, Bodurtha JN, Cox GF, Curry CJ, Day R, Donnai D, Field M, Fujiwara I, Gabbett M, Gal M, Graham JM, Hedera P, Hennekam RC, Hersh JH, Hopkin RJ, Kayserili H, Kidd AM, Kimonis V, Lin AE, Lynch SA, Maisenbacher M, Mansour S, McGaughran J, Mehta L, Murphy H, Raygada M, Robin NH, Rope AF, Rosenbaum KN, Schaefer GB, Shealy A, Smith W, Soller M, Sommer A, Stalker HJ, Steiner B, Stephan MJ, Tilstra D, Tomkins S, Trapane P, Tsai AC, Van Allen MI, Vasudevan PC, Zabel B, Zunich J, Black GC, Biesecker LG. Molecular analysis expands the spectrum of phenotypes associated with GLI3 mutations. *Hum Mutat.* 2010;31:1142–54. PubMed PMID: 20672375.
- Johnston JJ, Walker RL, Davis S, Facio F, Turner JT, Bick DP, Daentl DL, Ellison JW, Meltzer PS, Biesecker LG. Zoom-in comparative genomic hybridisation arrays for the characterisation of variable breakpoint contiguous gene syndromes. *J Med Genet.* 2007;44:e59. PubMed PMID: 17098889.
- Johnston JJ, Olivos-Glander I, Killoran C, Elson E, Turner JT, Peters KF, Abbott MH, Aughton DJ, Aylsworth AS, Bamshad MJ, Booth C, Curry CJ, David A, Dinulos MB, Flannery DB, Fox MA, Graham JM, Grange DK, Guttmacher AE, Hannibal MC, Henn W, Hennekam RC, Holmes LB, Hoyme HE, Leppig KA, Lin AE, Macleod P, Manchester DK, Marcelis C, Mazzanti L, McCann E, McDonald MT, Mendelsohn NJ, Moeschler JB, Moghaddam B, Neri G, Newbury-Ecob R, Pagon RA, Phillips JA, Sadler LS, Stoler JM, Tilstra D, Walsh Vockley CM, Zackai EH, Zadeh TM, Brueton L, Black GC, Biesecker LG. Molecular and clinical analyses of Greig cephalopolysyndactyly and Pallister-Hall syndromes: robust phenotype prediction from the type and position of GLI3 mutations. *Am J Hum Genet.* 2005;76:609–22. PubMed PMID: 15739154.

- Johnston JJ, Olivos-Glander I, Turner J, Aleck K, Bird LM, Mehta L, Schimke RN, Heilstedt H, Spence JE, Blancato J, Biesecker LG. Clinical and molecular delineation of the Greig cephalopolysyndactyly contiguous gene deletion syndrome and its distinction from acrocallosal syndrome. *Am J Med Genet A*. 2003;123A:236–42. PubMed PMID: 14608643.
- Kalff-Suske M, Wild A, Topp J, Wessling M, Jacobsen EM, Bornholdt D, Engel H, Heuer H, Aalfs CM, Ausems MG, Barone R, Herzog A, Heutink P, Homfray T, Gillessen-Kaesbach G, König R, Kunze J, Meinecke P, Müller D, Rizzo R, Strenge S, Superti-Furga A, Grzeschik KH. Point mutations throughout the GLI3 gene cause Greig cephalopolysyndactyly syndrome. *Hum Mol Genet*. 1999;8:1769–77. PubMed PMID: 10441342.
- Khan H, Abdullah, Ahmed S, Nawaz S, Ahmad W, Rafiq MA. Greig Cephalopolysyndactyly syndrome: phenotypic variability associated with variants in two different domains of GLI3. *Klin Padiatr*. 2021;233:53–8. PubMed PMID: 33339065.
- Kroisel PM, Petek E, Wagner K. Phenotype of five patients with Greig syndrome and microdeletion of 7p13. *Am J Med Genet*. 2001;102:243–9. PubMed PMID: 11484201.
- Krüger G, Gotz J, Kvist U, Dunker H, Erfurth F, Pelz L, Zech L. Greig syndrome in a large kindred due to reciprocal chromosome translocation t(6;7)(q27;p13). *Am J Med Genet*. 1989;32:411–6. PubMed PMID: 2729360.
- Patel R, Tripathi FM, Singh SK, Rani A, Bhattacharya V, Ali A. A novel GLI3c.750delC truncation mutation in a multiplex Greig cephalopolysyndactyly syndrome family with an unusual phenotypic combination in a patient. *Meta Gene*. 2014;2:880–7. PubMed PMID: 25606469.
- Polivka L, Parietti V, Bruneau J, Soucie E, Madrange M, Bayard E, Rignault R, Canioni D, Fraitag S, Lhermitte L, Feroul M, Tissandier M, Rossignol J, Frenzel L, Cagnard N, Meni C, Bouktit H, Collange AF, Gougoula C, Parisot M, Bader-Meunier B, Livideanu C, Laurent C, Arock M, Hadj-Rabia S, Rütter U, Dubreuil P, Bodemer C, Hermine O, Maouche-Chrétien L. The association of Greig syndrome and mastocytosis reveals the involvement of the hedgehog pathway in advanced mastocytosis. *Blood*. 2021;138:2396–407. PubMed PMID: 34424959.
- Richards S, Aziz N, Bale S, Bick D, Das S, Gastier-Foster J, Grody WW, Hegde M, Lyon E, Spector E, Voelkerding K, Rehm HL; ACMG Laboratory Quality Assurance Committee. Standards and guidelines for the interpretation of sequence variants: a joint consensus recommendation of the American College of Medical Genetics and Genomics and the Association for Molecular Pathology. *Genet Med*. 2015;17:405–24. PubMed PMID: 25741868.
- Siavrienė E, Mikštienė V, Radzevičius D, Maldžienė Ž, Rančelis T, Petraitytė G, Tamulytė G, Kavaliauskienė I, Šarkinas L, Utkus A, Kučinskas V, Preikšaitienė E. Novel GLI3 variant causes Greig cephalopolysyndactyly syndrome in three generations of a Lithuanian family. *Mol Genet Genomic Med*. 2019;7:e878. PubMed PMID: 31325247.
- Schulz S, Volleth M, Muschke P, Wieland I, Wieacker P. Greig cephalopolysyndactyly (GCPS) contiguous gene syndrome in a boy with a 14 Mb deletion in region 7p13–14 caused by a paternal balanced insertion (5; 7). *Appl Clin Genet*. 2008;1:19–22. PubMed PMID: 23776344.
- Szczakiel HL, Hülsemann W, Holtgrewe M, Abad-Perez AT, Elsner J, Schwartzmann S, Horn D, Spielmann M, Mundlos S, Mensah MA. GLI3 variants causing isolated polysyndactyly are not restricted to the protein's C-terminal third. *Clin Genet*. 2021;100:758–65. PubMed PMID: 34482537.
- Speksnijder L, Cohen-Overbeek TE, Knapen MF, Lunshof SM, Hoogeboom AJ, van den Ouweland AM, de Coo IF, Lequin MH, Bolz HJ, Bergmann C, Biesecker LG, Willems PJ, Wessels MW. A de novo GLI3 mutation in a patient with acrocallosal syndrome. *Am J Med Genet A*. 2013;161A:1394–400. PubMed PMID: 23633388.



- Tommerup N, Nielsen F. A familial reciprocal translocation t(3;7) (p21.1;p13) associated with the Greig polysyndactyly-craniofacial anomalies syndrome. *Am J Med Genet.* 1983;16:313–21. PubMed PMID: 6316787.
- Villavicencio EH, Walterhouse DO, Iannaccone PM. The sonic hedgehog-patched-gli pathway in human development and disease. *Am J Hum Genet.* 2000;67:1047–54. PubMed PMID: 11001584.
- Wild A, Kalff-Suske M, Vortkamp A, Bornholdt D, König R, Grzeschik KH. Point mutations in human GLI3 cause Greig syndrome. *Hum Mol Genet.* 1997;6:1979–84. PubMed PMID: 9302279.
- Williams PG, Hersh JH, Yen FF, Barch MJ, Kleinert HE, Kunz J, Kalff-Suske M. Greig cephalopolysyndactyly syndrome: altered phenotype of a microdeletion syndrome due to the presence of a cytogenetic abnormality. *Clin Genet.* 1997;52:436–41. PubMed PMID: 9520255.

## License

GeneReviews® chapters are owned by the University of Washington. Permission is hereby granted to reproduce, distribute, and translate copies of content materials for noncommercial research purposes only, provided that (i) credit for source (<http://www.genereviews.org/>) and copyright (© 1993-2024 University of Washington) are included with each copy; (ii) a link to the original material is provided whenever the material is published elsewhere on the Web; and (iii) reproducers, distributors, and/or translators comply with the [GeneReviews® Copyright Notice and Usage Disclaimer](#). No further modifications are allowed. For clarity, excerpts of GeneReviews chapters for use in lab reports and clinic notes are a permitted use.

For more information, see the [GeneReviews® Copyright Notice and Usage Disclaimer](#).

For questions regarding permissions or whether a specified use is allowed, contact: [admasst@uw.edu](mailto:admasst@uw.edu).