



Choroideremia

Ian M MacDonald, MD, CM,¹ Stacey Hume, PhD,² Yi Zhai, MD, PhD,³ and Manlong Xu, MD, PhD³

Created: February 21, 2003; Updated: March 4, 2021.

Summary

Clinical characteristics

Choroideremia (CHM) is characterized by progressive chorioretinal degeneration in affected males and milder signs in heterozygous (carrier) females. Typically, symptoms in affected males evolve from night blindness to peripheral visual field loss, with central vision preserved until late in life. Although carrier females are generally asymptomatic, signs of chorioretinal degeneration can be reliably observed with fundus autofluorescence imaging, and – after age 25 years – with careful fundus examination.

Diagnosis/testing

The diagnosis of choroideremia is established in a male proband with suggestive findings and a hemizygous pathogenic variant in *CHM* identified by molecular genetic testing.

Management

Treatment of manifestations: Surgical correction of retinal detachment and cataract as needed; UV-blocking sunglasses for outdoors; appropriate dietary intake of fresh fruit, leafy green vegetables; antioxidant vitamin supplement as needed; regular intake of dietary omega-3 very-long-chain fatty acids, including docosahexaenoic acid; low vision services as needed; counseling as needed to help cope with depression, loss of independence, fitness for driving, and anxiety over employment issues.

Surveillance: Periodic ophthalmologic examination, kinetic visual field examination, and spectral domain optical coherence tomography (SD-OCT), especially when central vision is affected and cystoid macular edema is suspected.

Agents/circumstances to avoid: UV exposure from sunlight reflected from water and snow; smoking (a major risk factor for macular degeneration).

Author Affiliations: 1 Professor, Department of Ophthalmology and Visual Sciences University of Alberta Edmonton, Alberta, Canada; Email: macdonal@ualberta.ca. 2 Joint Laboratory Head and Associate Professor, Molecular Diagnostics Laboratory Department of Medical Genetics University of Alberta Edmonton, Alberta, Canada; Email: shume@ualberta.ca. 3 Department of Ophthalmology and Visual Sciences University of Alberta Edmonton, Alberta, Canada; Email: yzhai4@ualberta.ca; Email: manlong@ualberta.ca.

Genetic counseling

CHM is inherited in an X-linked manner. Affected males transmit the pathogenic variant to all of their daughters and none of their sons. Heterozygous females have a 50% chance of transmitting the variant in each pregnancy: males who inherit the pathogenic variant will be affected; females who inherit the pathogenic variant will be carriers and will usually not be symptomatic. Once the *CHM* pathogenic variant has been identified in an affected family member, carrier testing for at-risk female relatives, prenatal testing for a pregnancy at increased risk, and preimplantation genetic testing for choroideremia are possible.

Diagnosis

Suggestive Findings

The diagnosis of choroideremia (CHM) should be suspected in males with the following clinical, electroretinogram (ERG), and visual field findings, and family history.

Clinical findings

- **Defective dark adaptation.** Poor vision in the dark is commonly the first symptom in affected males, usually as a preteen.
- **Characteristic fundus appearance.** Patchy areas of chorioretinal degeneration generally begin in the mid-periphery of the fundus. The areas of chorioretinal degeneration progress to marked loss of the retinal pigment epithelium and choriocapillaris (inner of the two vascular layers of the choroid that is composed largely of capillaries) with preservation of the deep choroidal vessels (Figures 1 and 2). Peripapillary atrophy of the RPE occurs early and is progressive [Khan et al 2016].
The function and anatomy of the central macula are preserved until late in the disease process and can be demonstrated with fundus autofluorescence imaging (Figure 3).

Electroretinogram (ERG) of affected males may at first show a pattern of rod-cone degeneration, which eventually becomes non-recordable.

Peripheral visual field loss manifests as a ring scotoma and generally follows changes in the fundus appearance. Areas of visual field loss closely match areas of chorioretinal degeneration.

Family history is consistent with X-linked inheritance (e.g., no male-to-male transmission). Absence of a known family history does not preclude the diagnosis.

Establishing the Diagnosis

The diagnosis of choroideremia **is established** in a male proband with suggestive findings and a hemizygous pathogenic variant in *CHM* identified by molecular genetic testing (see Table 1).

Note: Identification of a hemizygous *CHM* variant of uncertain significance does not establish or rule out a diagnosis of this disorder.

Molecular genetic testing approaches can include **gene-targeted testing** (single-gene testing and multigene panel) and **comprehensive genomic testing** (exome sequencing, genome sequencing) depending on the phenotype.

Gene-targeted testing requires that the clinician determine which gene(s) are likely involved, whereas genomic testing does not. Individuals with the distinctive findings described in Suggestive Findings are likely to be

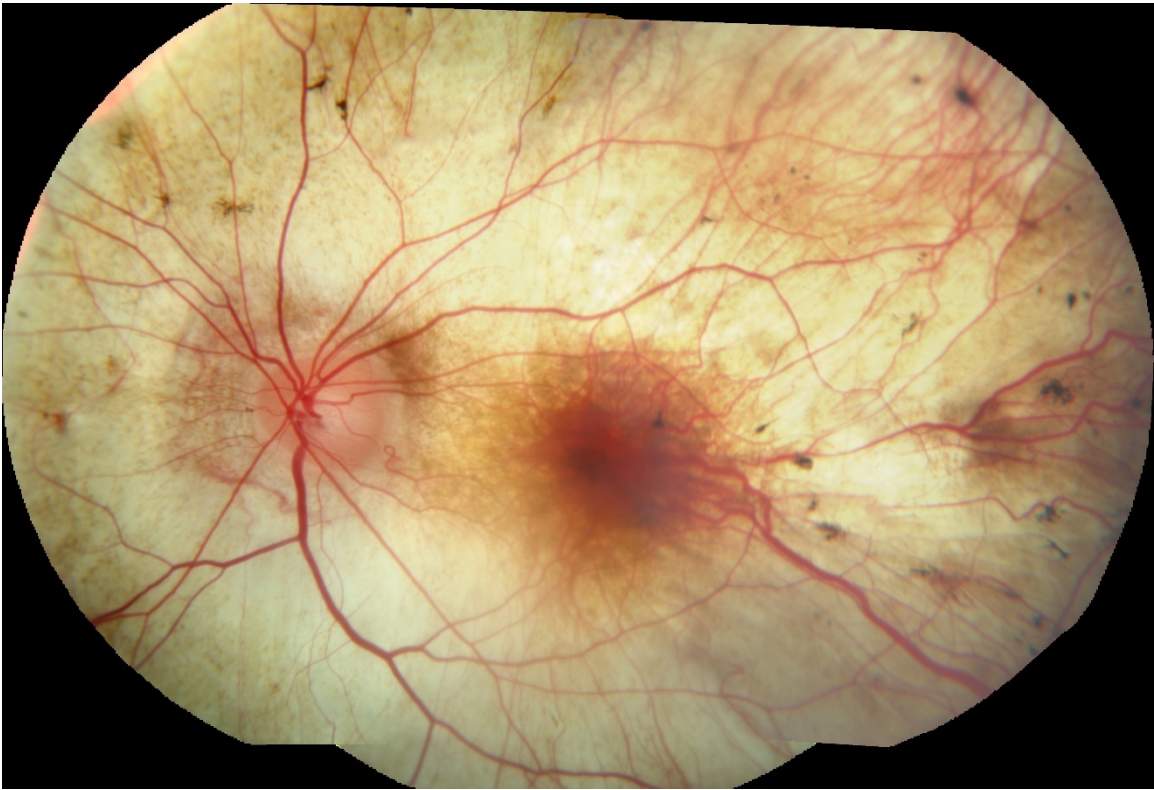


Figure 1. Fundus collage image from the left eye of an affected male with light pigmentation age 36 years

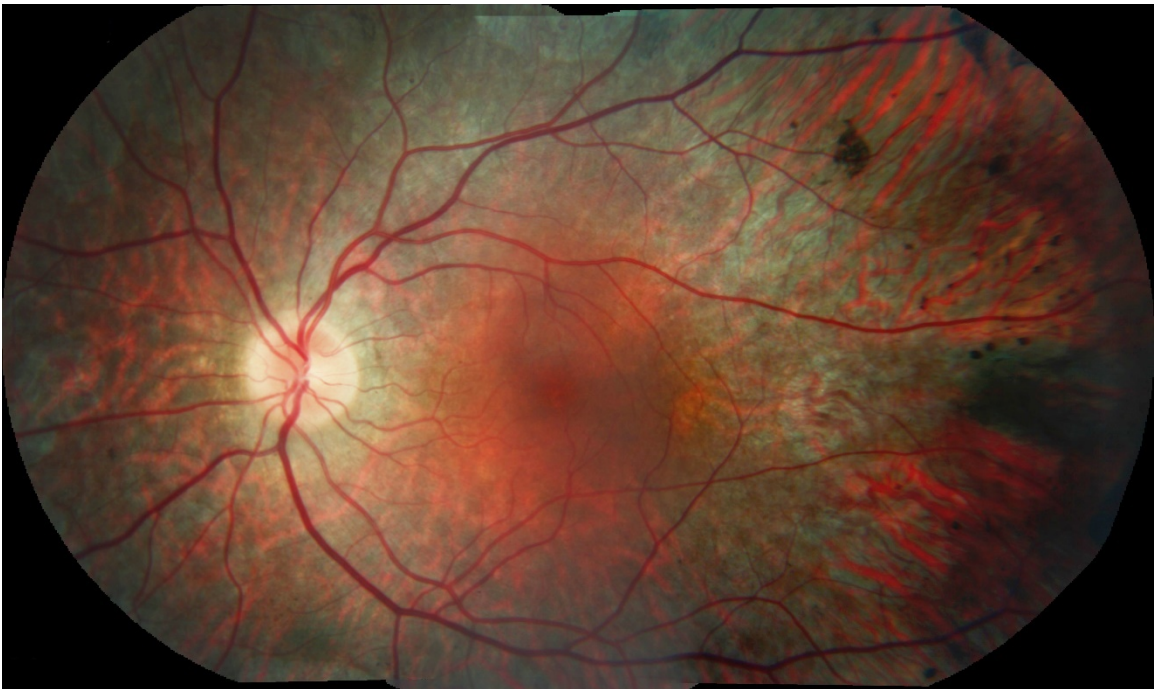

Figure 2. Fundus collage image from the left eye an affected male with dark pigmentation age 35 years

diagnosed using gene-targeted testing (see Option 1), whereas those in whom the diagnosis of choroideremia has not been considered are more likely to be diagnosed using genomic testing (see Option 2).

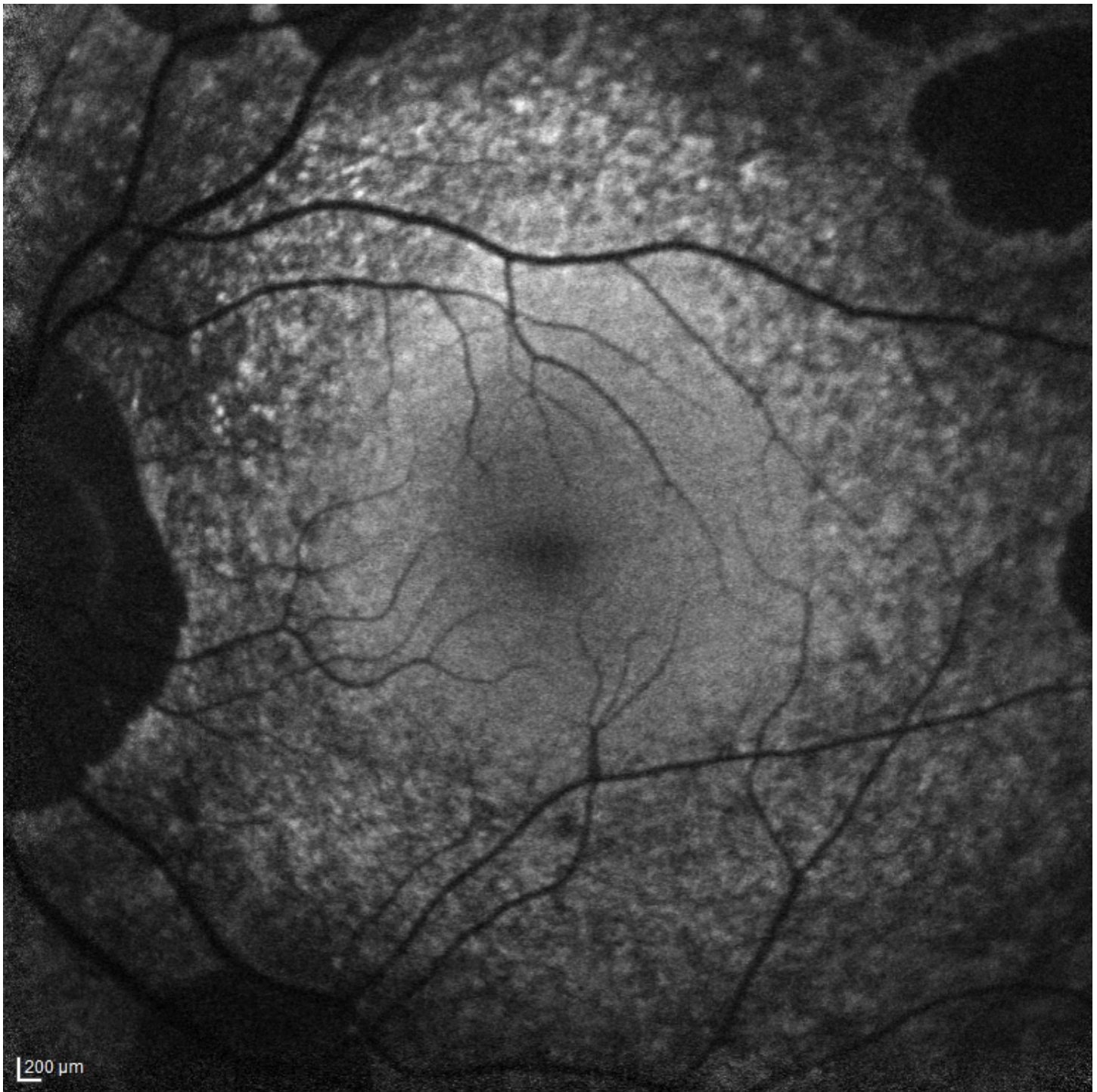


Figure 3. Fundus autofluorescence image from the left eye of an affected male age 35 years.

Option 1

Single-gene testing. Sequence analysis of *CHM* is performed first to detect small intragenic deletions/insertions and missense, nonsense, and splice site variants. Depending on the exon sequencing method used, single-exon, multiexon, or whole-gene duplications may not be detected. If no variant is detected by the sequencing method used, the next step is to perform gene-targeted deletion/duplication analysis to detect exon and whole-gene deletions or duplications.

An inherited retinal dystrophy multigene panel that includes *CHM* and other genes of interest (see Differential Diagnosis) is most likely to identify the genetic cause of the condition while limiting identification of variants of uncertain significance and pathogenic variants in genes that do not explain the underlying phenotype. Note: (1) The genes included in the panel and the diagnostic sensitivity of the testing used for each gene vary by laboratory and are likely to change over time. (2) Some multigene panels may include genes not associated with the condition discussed in this *GeneReview*. (3) In some laboratories, options may include a custom laboratory-designed panel and/or custom phenotype-focused genetic analysis that includes genes specified by the clinician. (4) Methods used in a panel may include sequence analysis, deletion/duplication analysis, and/or other non-sequencing-based tests.

For an introduction to multigene panels click [here](#). More detailed information for clinicians ordering genetic tests can be found [here](#).

Option 2

Comprehensive genomic testing does not require the clinician to determine which gene is likely involved. **Exome sequencing** is most commonly used; **genome sequencing** is also possible.

For an introduction to comprehensive genomic testing click [here](#). More detailed information for clinicians ordering genomic testing can be found [here](#).

Table 1. Molecular Genetic Testing Used in Choroideremia

Gene ¹	Method	Proportion of Probands with a Pathogenic Variant ^{2, 3} Detectable by Method
<i>CHM</i>	Sequence analysis ⁴	Up to 75% ⁵
	Deletion/duplication analysis ⁶	~25% ⁷

1. See Table A. Genes and Databases for chromosome locus and protein.

2. See Molecular Genetics for information on variants detected in this gene.

3. Additional individuals with contiguous gene deletions that include *CHM* (not included in these calculations) have been reported (see Genetically Related Disorders).

4. Sequence analysis detects variants that are benign, likely benign, of uncertain significance, likely pathogenic, or pathogenic. Variants may include small intragenic deletions/insertions and missense, nonsense, and splice site variants; typically, exon or whole-gene duplications are not detected. For issues to consider in interpretation of sequence analysis results, click [here](#).

5. McTaggart et al [2002], van den Hurk et al [2003]

6. Gene-targeted deletion/duplication analysis detects intragenic deletions or duplications. Methods used may include quantitative PCR, long-range PCR, multiplex ligation-dependent probe amplification (MLPA), and a gene-targeted microarray designed to detect single-exon deletions or duplications.

7. Copy number variants may represent up to 25% of instances in which Sanger sequencing did not identify a pathogenic variant and/or no *REP1* was found with western analysis. These observations are based predominantly on persons of northern European heritage and on separate Chinese cohorts [Chi et al 2013, Furgoch et al 2014, Zhou et al 2017].

Clinical Characteristics

Clinical Description

Affected males. Choroideremia (*CHM*) is characterized by progressive chorioretinal degeneration in affected males. Typically, symptoms evolve from night blindness to peripheral visual field loss, with central vision preserved until late in life. Males in their 40s have very good visual acuity but only a small visual field. In a large meta-analysis of more than 1,000 eyes, transition from a slow to more rapid decline in vision occurred at age 39 years [Shen et al 2021]. Later, around age 50-70 years, central vision becomes markedly impaired.

Posterior subcapsular cataracts are similar to those observed in retinitis pigmentosa.

Cystoid macular edema has been reported.

Heterozygous females are generally asymptomatic; however, signs of retinal pigment epithelial depigmentation or atrophy can be observed with careful fundus examination. These signs become more readily apparent after the second decade. Night blindness and visual field loss can also develop later in life due to expanding areas of retinal pigment epithelial atrophy.

Symptomatic but mildly affected females are likely underreported in the literature.

Note: The terms "silent carrier" and "manifesting heterozygote" are used in the literature to refer to asymptomatic heterozygous females and symptomatic heterozygous females, respectively. In this *GeneReview*, the term "heterozygous female" encompasses all females with a *CHM* pathogenic variant (i.e., silent carriers and manifesting heterozygotes) regardless of the presence or absence of CHM-related symptoms and/or findings.

Heterozygous females may or may not show changes with ERG testing, funduscopic examination, fundus autofluorescence (at a young age, <25 years), color vision testing, and visual field testing.

- The ERG may be normal or reduced. In seven heterozygous females, Renner et al [2006] reported normal ERGs in six and reduced amplitudes in one.
- Fundoscopy may reveal pigmentary stippling and distinct chorioretinal atrophy [Renner et al 2006].
- Color vision defects can be found using the desaturated panel D15 test [Renner et al 2006].
- Visual fields can range from normal in the majority of heterozygous females to distinct field defects that mimic those of affected males [Renner et al 2006].
- Fundus autofluorescence imaging will demonstrate patchy areas of lost fluorescence throughout the fundus [Edwards et al 2015, Jauregui et al 2019] (Figure 4).

Heterozygous females who demonstrate clinical findings mimicking those of affected males likely have skewed X-chromosome inactivation.

Genotype-Phenotype Correlations

Genotype-phenotype correlations have not been demonstrated for this disorder.

Prevalence

Prevalence is estimated at between 1:50,000 and 1:100,000 [Khan et al 2016].

Genetically Related (Allelic) Disorders

Choroideremia (CHM) is typically an isolated clinical finding; however, it may rarely be part of a contiguous gene deletion involving Xq21.

- Males with large interstitial deletions involving Xq21 and additional X chromosome material may have CHM, severe cognitive deficits, and birth defects such as cleft lip and palate and agenesis of the corpus callosum [Schwartz & Rosenberg 1996].
- Males who have a small deletion involving Xq21 may have CHM, mixed sensorineural and conductive hearing loss (caused by deletion of *POU3F4*), and varying degrees of cognitive deficits (caused by deletion of *RSK4*) [Yntema et al 1999].
- A contiguous gene deletion involving Xq21 in a female with premature ovarian failure and mixed conductive and sensorineural deafness resulted from a *de novo* X;4 chromosome translocation [Lorda-Sanchez et al 2000].

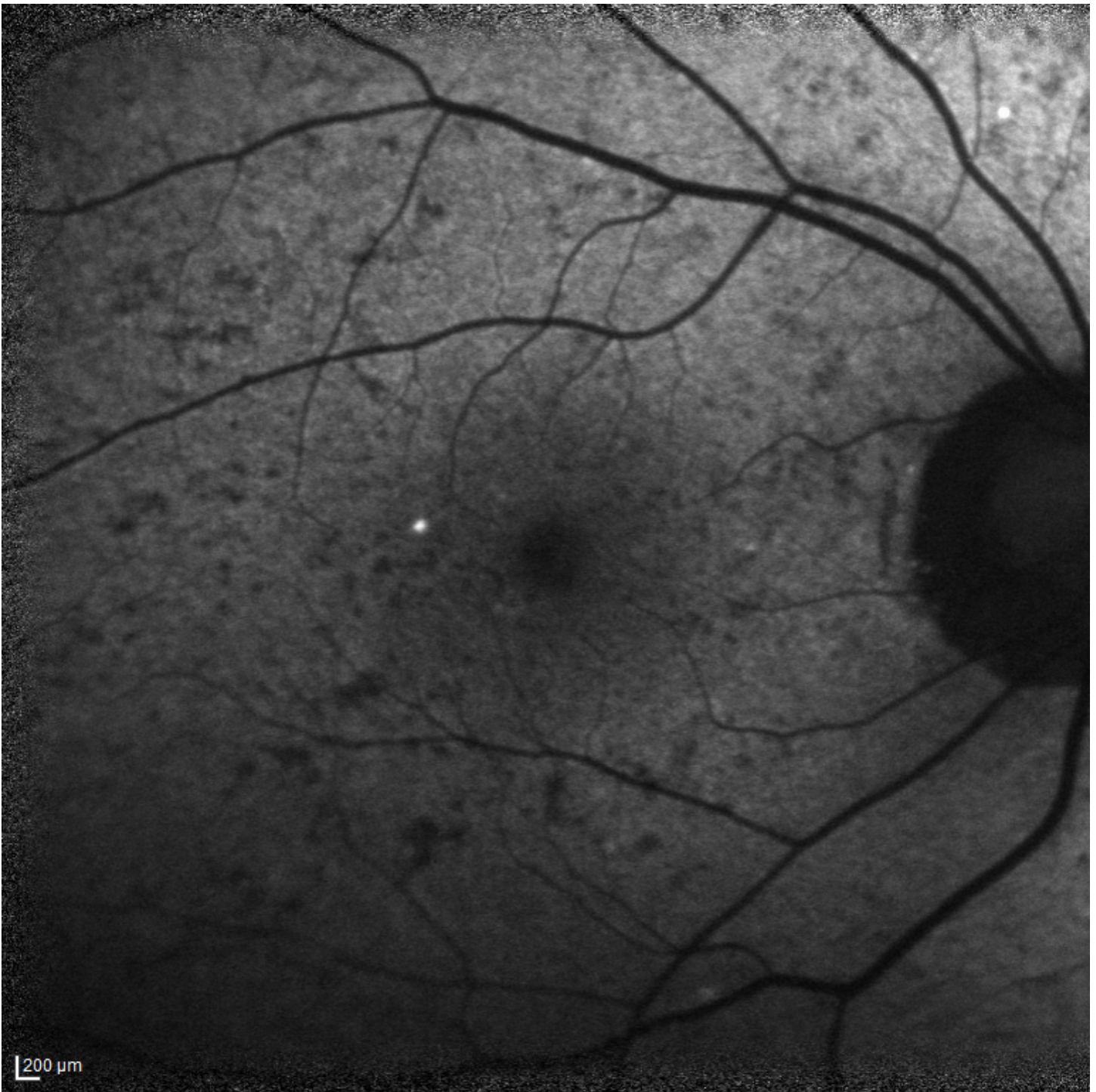

Figure 4. Fundus autofluorescence image from the right eye of a female carrier age 30 years

Differential Diagnosis

Choroideremia (CHM) needs to be distinguished from the inherited retinal dystrophies summarized in Table 2.

Table 2. Genes of Interest in the Differential Diagnosis of Choroideremia

Gene(s)	DiffDx Disorder	MOI	Clinical Characteristics of DiffDx Disorder	
			Overlapping Features	Distinguishing Features
~80 genes ¹	Nonsyndromic retinitis pigmentosa (RP)	AD AR XL ³	The symptoms of RP ("night blindness" & constriction of peripheral visual field) are similar to those of CHM. In later stages of CHM, when loss of choroid & retina are significant, fundus appearance may be confused w/end-stage RP.	The degree of pigment migration into the retina that typifies RP is not seen in persons w/CHM.
<i>CDH23</i> <i>CIB2</i> <i>MYO7A</i> <i>PCDH15</i> <i>USH1C</i> <i>USH1G</i>	Usher syndrome type 1 (USH1)	AR	RP develops in adolescence, → progressively constricted visual fields & impaired visual acuity.	The scalloped areas of significant chorioretinal degeneration w/ preservation of choroidal & retinal vessels typical of CHM are not seen in USH1. USH1 has features of congenital, bilateral, profound hearing loss & vestibular areflexia. Unless fitted w/ cochlear implant, persons do not typically develop speech.
<i>OAT</i>	Gyrate atrophy of choroid & retina (GACR) (OMIM 258870)	AR	The progressive nature of scalloped areas of chorioretinal atrophy in GACR may appear similar to findings in CHM.	Persons w/GACR have ↑ plasma concentration of ornithine (not seen in persons w/CHM).
<i>RPE65</i>	RP w/choroidal involvement (RP87) (OMIM 618697)	AD	Stellate, scalloped areas of chorioretinal atrophy, very similar to CHM	RP87 is only known to be assoc w/ Asp477Gly pathogenic variant. ⁴

AD = autosomal dominant; AR = autosomal recessive; CHM = choroideremia; DiffDx = differential diagnosis; MOI = mode of inheritance; XL = X-linked

1. See [Nonsyndromic Retinitis Pigmentosa Overview](#) and [OMIM Phenotypic Series: Retinitis pigmentosa](#).

2. In RP, abnormalities of the photoreceptors (rods & cones) or the retinal pigment epithelium lead to progressive visual loss.

3. Very rare digenic forms also occur.

4. Bowne et al [2011]

Management

No clinical practice guidelines for choroideremia have been published.

Evaluations Following Initial Diagnosis

To establish the extent of disease and needs in an individual diagnosed with choroideremia (CHM), the following evaluations (if not performed as part of the evaluation that led to the diagnosis) are recommended:

- Ophthalmologic examination including best corrected visual acuity (BCVA), funduscopy examination, and visual field testing for a baseline
- Spectral domain optical coherence tomography (SD-OCT) to evaluate and monitor the change of macular structure over time, especially ellipsoid zone (EZ), outer retinal tubulations, and chorioretinal atrophy. It is also helpful in identifying any comorbid maculopathy.
- Referral to a low vision specialist or vision rehabilitation clinic may be particularly helpful as central vision declines and/or visual field becomes limited.
- Consultation with a medical geneticist, certified genetic counselor, or certified advanced genetic nurse to inform affected individuals and their families about the nature, mode of inheritance, and implications of choroideremia in order to facilitate medical and personal decision making

Treatment of Manifestations

Retinal detachment, which may occur more commonly in individuals with high myopia (as seen in CHM), is treated by conventional surgical techniques by an ophthalmologist.

Cataract surgery may be required for individuals with a posterior subcapsular cataract.

Rare instances of choroidal neovascularization may be treated with intravitreal bevacizumab [Palejwala et al 2014].

UV-blocking sunglasses may have a protective role when an affected individual is outdoors.

Low vision services are designed to benefit those whose ability to function is compromised by vision impairment. Low vision specialists, often optometrists, help optimize the use of remaining vision. Services provided vary based on age and needs.

Counseling from organizations or professionals who work with the blind and visually impaired may help the affected individual cope with issues such as depression, loss of independence, fitness for driving, and anxiety over employment issues.

Nutrition and ocular health have become increasingly topical:

- For those individuals who do not have access to fresh fruit and leafy green vegetables, a supplement with antioxidant vitamins may be important.
- No information is available on the effectiveness of vitamin A supplementation in the treatment of CHM.
- A source of omega-3 very-long-chain fatty acids, including docosahexaenoic acid, may be beneficial, as clinical studies suggest that regular intake of fish is important.

Surveillance

Regular ophthalmologic examination to monitor progression of CHM is recommended, as affected individuals need advice regarding their levels of visual function.

Kinetic visual field examinations provide practical information for both the clinician and the affected individual.

SD-OCT imaging is a fundamental clinical tool to evaluate macular structure, especially when central vision is affected and cystoid macular edema is suspected.

Agents/Circumstances to Avoid

Avoid the following:

- UV exposure from sunlight reflected from water and snow
- Smoking, a major risk factor for macular degeneration

Evaluation of Relatives at Risk

See [Genetic Counseling](#) for issues related to testing of at-risk relatives for genetic counseling purposes.

Therapies Under Investigation

Gene replacement therapy using a subretinal delivery of AAV2-REP1 (Nightstar Therapeutics, UK) has been trialed in the UK, Canada, US, and Germany. Reports showed some gain in visual acuity in the treated eye compared to the untreated eye. However, some individuals experienced significant complications such as retinal overstretch and postoperative inflammation. This product is currently in a Phase III trial; results are expected in the coming years [Cehajic Kapetanovic et al 2019].

Another gene augmentation agent that is being trialed uses an intravitreal delivery of 4D-110 (4D Molecular Therapeutics, USA) in individuals with genetically confirmed choroideremia ([ClinicalTrials.gov](https://clinicaltrials.gov)). The trial is estimated to be completed in 2023.

Search [ClinicalTrials.gov](https://clinicaltrials.gov) in the US and [EU Clinical Trials Register](https://clinicaltrialsregister.eu) in Europe for access to information on clinical studies for a wide range of diseases and conditions.

Genetic Counseling

Genetic counseling is the process of providing individuals and families with information on the nature, mode(s) of inheritance, and implications of genetic disorders to help them make informed medical and personal decisions. The following section deals with genetic risk assessment and the use of family history and genetic testing to clarify genetic status for family members; it is not meant to address all personal, cultural, or ethical issues that may arise or to substitute for consultation with a genetics professional. —ED.

Mode of Inheritance

Choroideremia (CHM) is inherited in an X-linked manner.

Risk to Family Members

Parents of a male proband

- The father of an affected male will not have CHM nor will he be hemizygous for the *CHM* pathogenic variant; therefore, he does not require further evaluation/testing.
- In a family with more than one affected individual, the mother of an affected male is an obligate heterozygote. Note: If a woman has more than one affected child and no other affected relatives and if the *CHM* pathogenic variant identified in the proband cannot be detected in her leukocyte DNA, she most likely has germline mosaicism.
- If a male is the only affected family member (i.e., a simplex case), the mother may be a heterozygote, the affected male may have a *de novo* *CHM* pathogenic variant (in which case the mother is not a heterozygote), or the mother may have somatic/germline mosaicism [van den Hurk et al 2007].
- Evaluation of the mother is recommended to confirm her genetic status and to allow reliable recurrence risk assessment. Evaluations of the mother include:
 - Molecular genetic testing for the *CHM* pathogenic variant identified in the proband;
 - Examination of the retina through a dilated pupil to determine if she has signs of chorioretinal degeneration; however, a normal fundus examination at a young age (<25 years) may not be sufficient to exclude carrier status (see Clinical Description, **Heterozygous females**).

Sibs of a male proband. The risk to the sibs of a male proband depends on the genetic status of the mother:

- If the mother of the proband has a *CHM* pathogenic variant, the chance of transmitting it in each pregnancy is 50%.
 - Males who inherit the pathogenic variant will be affected; it is not possible to predict at what age an affected male will start to experience vision problems and how quickly the disease will progress.
 - Females who inherit the pathogenic variant will be heterozygotes and may or may not initially show changes with ERG testing, fundoscopic examination, color vision testing, and/or visual field testing; however, with time, areas of decreased fundus autofluorescence will be seen (see Clinical Description, **Heterozygous females**).

It is not possible to predict if a heterozygous female will manifest any vision loss. At one time, consensus held that heterozygous females experienced only mild vision disturbances later in life; however, heterozygous females may have vision loss similar to that of affected males because of skewed X-chromosome inactivation.

- If the proband represents a simplex case (i.e., a single occurrence in a family), if the mother has a normal fundus examination, and if the *CHM* pathogenic variant cannot be detected in the leukocyte DNA of the mother, the risk to sibs is presumed to be low but greater than that of the general population because of the possibility of maternal germline mosaicism [van den Hurk et al 2007].

Offspring of a male proband. Affected males transmit the pathogenic variant to all of their daughters and none of their sons.

Other family members. The maternal aunts and maternal cousins of an affected male may be at risk of having a *CHM* pathogenic variant.

Note: Molecular genetic testing may be able to identify the family member in whom a *de novo* pathogenic variant arose, information that could help determine genetic risk status of the extended family.

Heterozygote Detection

Molecular genetic testing. Identification of female heterozygotes requires either prior identification of the *CHM* pathogenic variant in the family or, if an affected male is not available for testing, molecular genetic testing first by sequence analysis, and if no pathogenic variant is identified, by gene-targeted deletion/duplication analysis.

Fundus examination. The retina is examined through a dilated pupil to determine if a female relative has signs of chorioretinal degeneration (see Clinical Description, **Heterozygous females**).

Note: Females who are heterozygous for this X-linked disorder may not have manifestations of CHM at a young age, but most definitely will have signs after age 25 years (see Clinical Description, **Heterozygous females**).

Related Genetic Counseling Issues

Family planning

- The optimal time for determination of genetic risk and discussion of the availability of prenatal/preimplantation genetic testing is before pregnancy.
- It is appropriate to offer genetic counseling (including discussion of potential risks to offspring and reproductive options) to young adults who are affected, are heterozygous, or are at risk of being heterozygous.

Prenatal Testing and Preimplantation Genetic Testing

Once the *CHM* pathogenic variant has been identified in an affected family member, prenatal testing for a pregnancy at increased risk and preimplantation genetic testing for choroideremia are possible.

Differences in perspective may exist among medical professionals and within families regarding the use of prenatal testing. While most centers would consider use of prenatal testing to be a personal decision, discussion of these issues may be helpful.

Resources

GeneReviews staff has selected the following disease-specific and/or umbrella support organizations and/or registries for the benefit of individuals with this disorder and their families. GeneReviews is not responsible for the information provided by other organizations. For information on selection criteria, click [here](#).

- **Choroideremia Research Foundation**

23 East Brundreth Street
Springfield MA 01109-2110

Phone: 800-210-0233

Email: info@curechm.org

curechm.org

- **Foundation Fighting Blindness**

7168 Columbia Gateway Drive
Suite 100

Columbia MD 21046

Phone: 800-683-5555 (toll-free); 800-683-5551 (Toll-free TDD); 410-423-0600; 410-363-7139 (local TDD)

Email: info@FightBlindness.org

[Choroideremia](#)

- **National Library of Medicine Genetics Home Reference**

[Choroideremia](#)

- **National Eye Institute**

Phone: 301-496-5248

Email: 2020@nei.nih.gov

[Low Vision](#)

- **eyeGENE – National Ophthalmic Disease Genotyping Network Registry**

Phone: 301-435-3032

Email: eyeGENEinfo@nei.nih.gov

<https://eyegene.nih.gov/>

Molecular Genetics

Information in the Molecular Genetics and OMIM tables may differ from that elsewhere in the GeneReview: tables may contain more recent information. —ED.

Table A. Choroideremia: Genes and Databases

Gene	Chromosome Locus	Protein	Locus-Specific Databases	HGMD	ClinVar

Table A. continued from previous page.

<i>CHM</i>	Xq21.2	Rab proteins geranylgeranyltransferase component A 1	Retinal and hearing impairment genetic mutation database	<i>CHM</i>	<i>CHM</i>
------------	--------	--	--	------------	------------

Data are compiled from the following standard references: gene from [HGNC](#); chromosome locus from [OMIM](#); protein from [UniProt](#). For a description of databases (Locus Specific, HGMD, ClinVar) to which links are provided, click [here](#).

Table B. OMIM Entries for Choroideremia (View All in OMIM)

300390	CHM RAB ESCORT PROTEIN; CHM
303100	CHOROIDEREMIA; CHM

Molecular Pathogenesis

REP-1, the protein encoded by *CHM*, is a cytosolic protein, present in all cells. REP-1 enables lipid modification by geranylgeranylation of small GTP-binding proteins (Rabs) that are involved in cellular mechanisms of endocytosis, exocytosis, and intracellular trafficking, the processes that primarily become disordered in key pathways within the retinal pigment epithelium, but also the photoreceptors.

Mechanism of disease causation. Loss of function. Nearly all known *CHM* pathogenic variants are nonsense variants, small deletions or insertions, or splice site alterations that predict or result in truncation of the protein product or its absence (REP-1).

An exception is the *CHM* pathogenic L1 retrotransposon insertion in exon 6 that results in the direct splicing of exon 5 to exon 7 with maintenance of the reading frame.

***CHM*-specific laboratory technical considerations.** When a clinical diagnosis of choroideremia is suspected, and no *CHM* pathogenic variant from gene-targeted testing can be identified, RNA and western blot analysis of *CHM* expression may be considered if available in a clinical laboratory. When a lack of *CHM* expression is identified, other variants (e.g., intronic, promoter, retrotransposon insertion, and large duplications) should be suspected. These variants may be incidentally detected by routine gene-targeted testing, for example, when the PCR product is larger than expected [Vaché et al 2019] or there is a drop in coverage of next-generation sequencing data within exon 2 of *CHM* [Jones et al 2020].

Table 3. Most Cited *CHM* Pathogenic Variants

Reference Sequences	DNA Nucleotide Change	Predicted Protein Change	Reference
NM_000390.4 NP_000381.1	c.877C>T	p.Arg293Ter	van Bokhoven et al [1994]
	c.1580_1583delTGTT	Frameshift	Li et al [2014]
	c.116+1G>T	--	van den Hurk et al [2003]
	c.1218 C>A	p.Cys406Ter	Nesslinger et al [1996]

Variants listed in the table have been provided by the authors. *GeneReviews* staff have not independently verified the classification of variants.

GeneReviews follows the standard naming conventions of the Human Genome Variation Society (varnomen.hgvs.org). See [Quick Reference](#) for an explanation of nomenclature.

Chapter Notes

Author Notes

Ian M MacDonald, MSc, MD, CM, is Professor Emeritus in the Department of Ophthalmology and Visual Sciences, University of Alberta, and past Chair of the department for 20 years. Prior to becoming Chair in Edmonton, he was a career scientist of the Ontario Ministry of Health at the University of Ottawa. From 2007 to 2008, he served as Branch Chief of Ophthalmic Genetics and Visual Function at the National Eye Institute of the National Institutes of Health. Dr MacDonald trained in genetics as an undergraduate and postgraduate student at McGill University, Montreal. His ophthalmology residency and clinical genetics fellowship training occurred at the University of Ottawa, Queen's University, Kingston, and the Hospital for Sick Children, Toronto.

Dr MacDonald's areas of interest are inherited ocular disorders, in particular maculopathies and choroideremia. In 2009, in recognition of his work in Canada to foster the development of academic ophthalmology, he was elected as a Fellow of the Canadian Academy of Health Sciences. The Canadian College of Medical Geneticists honored him with a Lifetime Achievement Award.

CHM Gene Therapy at University of Alberta website: chmgenetherapy.ca

Acknowledgments

Grant funding from Fighting Blindness Canada is gratefully acknowledged. Past grant funding: CIHR, Alberta Innovates, Choroideremia Research Foundation Inc. Dr Yi Zhai received a fellowship award from the Choroideremia Research Foundation. Dr Manlong Xu received fellowship support from a grateful patient, Pat Krawchuk.

Natural History of the Progression of Choroideremia (NIGHT NCT03359551) and SOLSTICE NCT03584165 was supported by Nightstar Therapeutics and Biogen Study Group.

The choroideremia natural history study (NCT02994368) was supported by funding from 4D Molecular Therapeutics, Inc (Emeryville, CA as sponsor) and Roche Pharma AG.

Author History

Stephanie Hoang, MSc, CGC, CCGC; University of Alberta Hospital (2015-2021)

Stacey Hume, PhD (2015-present)

Ian M MacDonald, MD, CM (2003-present)

Kerry McTaggart, MSc; University of Alberta (2003-2007)

Meira R Meltzer, MA, MS, CGC; National Eye Institute (2007-2010)

Miguel C Seabra, MD, PhD; Imperial College School of Medicine (2003-2021)

Christina Sereda, MSc; University of Alberta (2003-2007)

Nizar Smaoui, MD; GeneDx (2007-2015)

Manlong Xu, MD, PhD (2021-present)

Yi Zhai, MD, PhD (2021-present)

Revision History

- 4 March 2021 (bp) Comprehensive update posted live
- 26 February 2015 (me) Comprehensive update posted live
- 3 June 2010 (me) Comprehensive update posted live
- 28 May 2008 (cd) Revision: duplication/deletion analysis available clinically
- 3 May 2007 (me) Comprehensive update posted live

- 29 December 2004 (me) Comprehensive update posted live
- 2 January 2004 (im) Revision: testing
- 7 May 2003 (im) Revision: Molecular genetic testing; prenatal diagnosis
- 21 February 2003 (me) Review posted live
- 2 December 2002 (im) Original submission

References

Published Guidelines / Consensus Statements

American Academy of Ophthalmology Task Force on Genetic Testing. Recommendations for genetic testing of inherited eye diseases – 2014. Available [online](#). 2014. Accessed 11-9-21.

Literature Cited

- Bowne SJ, Humphries MM, Sullivan LS, Kenna PF, Tam LCS, Kiang AS, Campbell M, Weinstock GM, Koboldt S, Ding L, Fulton RS, Sodergren EJ, Allman D, Millington-Ward S, Palfi A, McKee A, Blanton SH, Slifer S, Konidari I, Farrar GJ, Daiger SP, Humphries P. A dominant mutation in RPE65 identified by whole-exome sequencing causes retinitis pigmentosa with choroidal involvement. *Eur J Hum Genet*. 2011;19:1074–81. PubMed PMID: 21654732.
- Cehajic Kapetanovic J, Barnard AR, MacLaren RE. Molecular therapies for choroideremia. *Genes (Basel)*. 2019;10:738. PubMed PMID: 31548516.
- Chi JY, MacDonald IM, Hume S. Copy number variant analysis in CHM to detect duplications underlying choroideremia. *Ophthalmic Genet*. 2013;34:229–33. PubMed PMID: 23273018.
- Edwards TL, Groppe M, Jolly JK, Downes SM, MacLaren RE. Correlation of retinal structure and function in choroideremia carriers. *Ophthalmology*. 2015;122:1274–76. PubMed PMID: 25682176.
- Furgoch MJ, Mewes-Arès J, Radziwon A, MacDonald IM. Molecular genetic diagnostic techniques in choroideremia. *Mol Vis*. 2014;20:535–44. PubMed PMID: 24791138.
- Jauregui R, Park KS, Tanaka AJ, Cho A, Paavo M, Zernant J, Francis JH, Allikmets R, Sparrow JR, Tsang SH. Spectrum of disease severity and phenotype in choroideremia carriers. *Am J Ophthalmol*. 2019;207:77–86. PubMed PMID: 31181178.
- Jones KD, Radziwon A, Birch DG, MacDonald IM. A novel SVA retrotransposon insertion in the CHM gene results in loss of REP-1 causing choroideremia. *Ophthalmic Genet*. 2020;41:341–4. PubMed PMID: 32441177.
- Khan KN, Islam F, Moore AT, Michaelides M. Clinical and genetic features of choroideremia in childhood. *Ophthalmology*. 2016;123:2158–65. PubMed PMID: 27506488.
- Li S, Guan L, Fang S, Jiang H, Xiao X, Yang J, Wang P, Yin Y, Guo X, Wang J, Zhang J, Zhang Q. Exome sequencing reveals CHM mutations in six families with atypical choroideremia initially diagnosed as retinitis pigmentosa. *Int J Mol Med*. 2014;34:573–7. PubMed PMID: 24913019.
- Lorda-Sanchez IJ, Ibanez AJ, Sanz RJ, Trujillo MJ, Anabitarte ME, Querejeta ME, Rodriguez de Alba M, Gimenez A, Infantes F, Ramos C, Garcia-Sandoval B, Ayuso C. Choroideremia, sensorineural deafness, and primary ovarian failure in a woman with a balanced X-4 translocation. *Ophthalmic Genet*. 2000;21:185–9. PubMed PMID: 11035551.
- McTaggart KE, Tran M, Mah DY, Lai SW, Nesslinger NJ, MacDonald IM. Mutational analysis of patients with the diagnosis of choroideremia. *Hum Mutat*. 2002;20:189–96. PubMed PMID: 12203991.
- Nesslinger N, Mitchell G, Strasberg P, MacDonald IM. Mutation analysis in Canadian families with choroideremia. *Ophthalmic Genet*. 1996;17:47–52. PubMed PMID: 8832720.

- Palejwala NV, Lauer AK, Weleber RG. Choroideremia associated with choroidal neovascularization treated with intravitreal bevacizumab. *Clin Ophthalmol*. 2014;8:1675–9. PubMed PMID: 25214760.
- Renner AB, Kellner U, Cropp E, Preising MN, MacDonald IM, van den Hurk JA, Cremers FP, Foerster MH (2006) Choroideremia: variability of clinical and electrophysiological characteristics and first report of a negative electroretinogram. *Ophthalmology*. 113:2066-73.e1-10.
- Schwartz M, Rosenberg T. Prenatal diagnosis of choroideremia. *Acta Ophthalmol Scand Suppl*. 1996;219:33–6. PubMed PMID: 8741114.
- Shen LL, Ahluwalia A, Sun M, Young BK, Nardini HKG, Del Priore LV. Long-term natural history of visual acuity in eyes with choroideremia: a systematic review and meta-analysis of data from 1004 individual eyes. *Br J Ophthalmol*. 2021;105:271–8. PubMed PMID: 32471821.
- Vaché C, Torriano S, Faugère V, Erkilic N, Baux D, Garcia-Garcia G, Hamel CP, Meunier I, Zanlonghi X, Koenig M, Kalatzis V, Roux AF. Pathogenicity of novel atypical variants leading to choroideremia as determined by functional analyses. *Hum Mutat*. 2019;40:31–5. PubMed PMID: 30341801.
- van Bokhoven H, van den Hurk JA, Bogerd L, Philippe C, Gilgenkrantz S, de Jong P, Ropers HH, Cremers FP. Cloning and characterization of the human choroideremia gene. *Hum Mol Genet*. 1994;3:1041–6. PubMed PMID: 7981670.
- van den Hurk JA, Meij IC, Seleme MC, Kano H, Nikopoulos K, Hoefsloot LH, Sistermans EA, de Wijs IJ, Mukhopadhyay A, Plomp AS, de Jong PT, Kazazian HH, Cremers FP. L1 retrotransposition can occur early in human embryonic development. *Hum Mol Genet*. 2007;16:1587–92. PubMed PMID: 17483097.
- van den Hurk JA, van de Pol DJ, Wissinger B, van Driel MA, Hoefsloot LH, de Wijs IJ, van den Born LI, Heckenlively JR, Brunner HG, Zrenner E, Ropers HH, Cremers FP. Novel types of mutation in the choroideremia (CHM) gene: a full-length L1 insertion and an intronic mutation activating a cryptic exon. *Hum Genet*. 2003;113:268–75. PubMed PMID: 12827496.
- Yntema HG, van den Helm B, Kissing J, van Duijnhoven G, Poppelaars F, Chelly J, Moraine C, Fryns JP, Hamel BC, Heilbronner H, Pander HJ, Brunner HG, Ropers HH, Cremers FP, van Bokhoven H. A novel ribosomal S6-kinase (RSK4; RPS6KA6) is commonly deleted in patients with complex X-linked mental retardation. *Genomics*. 1999;62:332–43. PubMed PMID: 10644430.
- Zhou Q, Yao F, Han X, Li H, Yang L, Sui R. Rep1 copy number variation is an important genetic cause of choroideremia in Chinese patients. *Exp Eye Res*. 2017;164:64–73. PubMed PMID: 28774736.

License

GeneReviews® chapters are owned by the University of Washington. Permission is hereby granted to reproduce, distribute, and translate copies of content materials for noncommercial research purposes only, provided that (i) credit for source (<http://www.genereviews.org/>) and copyright (© 1993-2024 University of Washington) are included with each copy; (ii) a link to the original material is provided whenever the material is published elsewhere on the Web; and (iii) reproducers, distributors, and/or translators comply with the [GeneReviews® Copyright Notice and Usage Disclaimer](#). No further modifications are allowed. For clarity, excerpts of GeneReviews chapters for use in lab reports and clinic notes are a permitted use.

For more information, see the [GeneReviews® Copyright Notice and Usage Disclaimer](#).

For questions regarding permissions or whether a specified use is allowed, contact: admasst@uw.edu.