



Polymicrogyria Overview

Chloe A Stutterd, MBBS, FRACP,¹ William B Dobyns, MD,² Anna Jansen, MD, PhD,³ Ghayda Mirzaa, MD,⁴ and Richard J Leventer, MBBS, BMedSci, PhD, FRACP⁵

Created: April 18, 2005; Updated: August 16, 2018.

Summary

The following are the goals of this overview.

Goal 1

Describe the neuroimaging characteristics of polymicrogyria (PMG).

Goal 2

Review the genetic causes of PMG.

Goal 3

Provide an evaluation strategy to identify the genetic cause of PMG in a proband (when possible).

Goal 4

Inform genetic counseling of family members of a proband with PMG.

1. Definition and Clinical Characteristics of Polymicrogyria

Polymicrogyria (PMG) is a malformation of the developing brain characterized by abnormal cortical lamination and an unusual folding pattern of the cerebral cortex such that all or part of the brain surface is taken up by an excessive number of small gyri (folds). PMG, one of the most common brain malformations, accounts for approximately 20% of all malformations of cortical development [Leventer et al 1999].

Author Affiliations: 1 Murdoch Children's Research Institute, Department of Paediatrics, University of Melbourne, Royal Children's Hospital, Melbourne, Australia; Email: chloe.stutterd@mcri.edu.au. 2 Departments of Pediatrics and Neurology, University of Washington, Center for Integrative Brain Research, Seattle Children's Research Institute, Seattle, Washington; Email: wbd@uw.edu. 3 Pediatric Neurology Unit, UZ Brussel, Neurogenetics Research Group, Vrije Universiteit Brussel, Brussels, Belgium; Email: anna.jansen@uzbrussel.be. 4 Center for Integrative Brain Research, Seattle Children's Research Institute, Seattle, Washington; Email: gmirzaa@uw.edu. 5 Department of Neurology, Royal Children's Hospital, Murdoch Children's Research Institute, Department of Paediatrics, University of Melbourne, Melbourne, Australia; Email: richard.leventer@rch.org.au.

MRI. The diagnosis of PMG is typically made by MRI since computed tomography (CT) and other imaging methods do not have high enough resolution or adequate contrast to identify the small folds that define PMG. It is important that optimal imaging techniques (including thin sections) and age-specific protocols be used to provide the best contrast between gray and white matter with good spatial resolution and adequate signal-to-noise ratio [Barkovich 2010].

With high-quality MRI, microgyri and microsulci may be appreciated and stippling of the gray-white junction (a specific feature of PMG not seen in other malformations of cortical development) may be observed [Leventer et al 2010] (see Table 1). Of note, the Sylvian fissures (best seen on sagittal imaging) should be scrutinized in particular, as PMG often affects these areas preferentially.

While PMG is usually an isolated finding (i.e., occurring in the absence of other brain malformations), it can be seen in association with other brain malformations including gray matter heterotopia and ventriculomegaly, as well as abnormalities of the white matter, corpus callosum, brain stem, and cerebellum.

MRI – when interpreted by an expert – can reliably differentiate PMG from other malformations of cortical development (see Differential Diagnosis).

Prenatal ultrasound examination. In 5% of cases, PMG is detected on prenatal ultrasound examination by the presence of abnormalities – usually microcephaly and/or associated brain malformations. Note: PMG is difficult to detect by ultrasound examination until late in gestation [Leventer et al 2010].

Table 1. Patterns of PMG: MRI and Clinical Findings

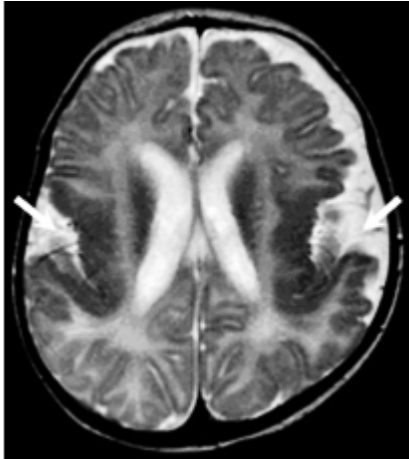
PMG Pattern	Affected Regions	MRI Findings
Bilateral perisylvian PMG (BPP)		Bilateral PMG maximal in perisylvian regions (arrows), which may be symmetric or asymmetric & may extend beyond perisylvian regions; sylvian fissures often extended posteriorly & superiorly

Table 1. continued from previous page.

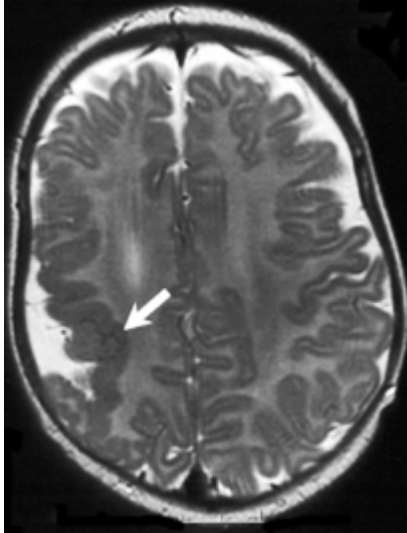
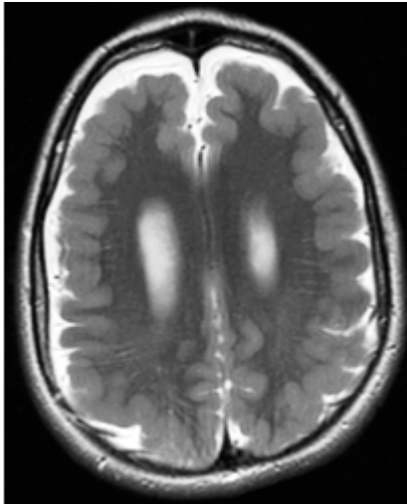
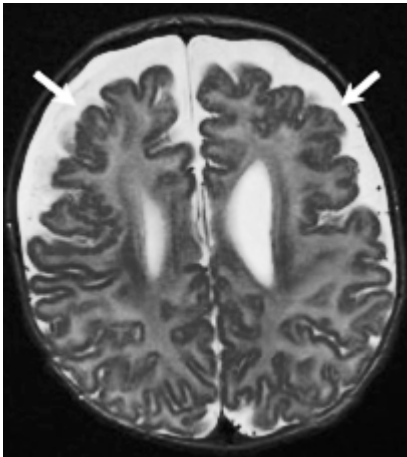

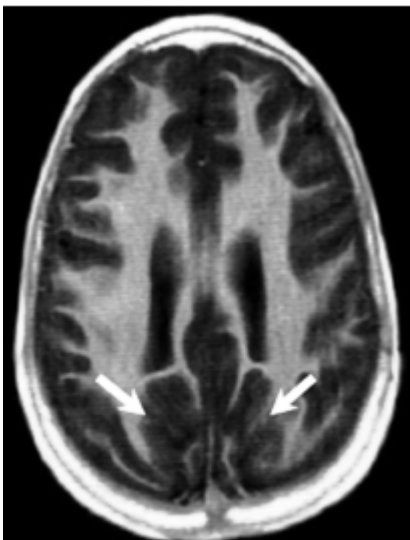
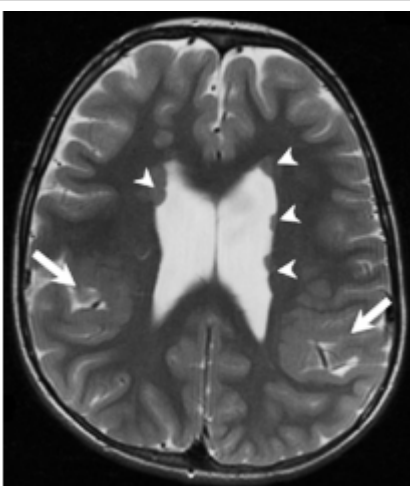
PMG Pattern	Affected Regions	MRI Findings
Unilateral perisylvian PMG (UPP)		Unilateral PMG maximal in perisylvian cortex (arrow), but may extend beyond perisylvian region; sylvian fissure often extended posteriorly & superiorly
Bilateral generalized PMG (BGP)		Symmetric generalized PMG w/no obvious gradient or region of maximal severity; may have abnormal high signal in white matter
Bilateral frontal PMG (BFP)		Symmetric PMG w/anterior > posterior gradient extending from frontal poles (arrows) posteriorly to precentral gyrus & inferiorly to frontal operculum

Table 1. continued from previous page.

PMG Pattern	Affected Regions	MRI Findings
Bilateral frontoparietal PMG (BFPP)		Symmetric generalized PMG with decreasing anterior-posterior gradient, most prominent in frontoparietal cortex (arrows)
Bilateral parasagittal parieto-occipital PMG (BPPP)		Bilateral PMG in parasagittal & mesial aspects of parieto-occipital cortex (arrows)
PMG associated w/periventricular nodular heterotopia (PNH-PMG)		PMG of variable patterns (mainly perisylvian or parieto-occipital) (large arrows) associated w/nodules of periventricular gray matter heterotopia (arrowheads)

All MRI images are T₂-weighted axial.

Bilateral perisylvian PMG (BPP), the most common pattern of PMG, is associated with oromotor dysfunction and a seizure disorder. Other findings typically include difficulties with tongue movement, expressive speech,

and sucking and swallowing, as well as excessive drooling and facial diplegia as seen in the Worster-Drought syndrome. Mild-moderate intellectual disability is seen in up to 75%. Motor dysfunction may include limb spasticity, which – if present – is rarely severe [Kuzniecky et al 1993].

For information on neuropathology of PMG click [here](#) (pdf).

Differential Diagnosis

Other malformations of cortical development that need to be distinguished from PMG:

- Pachygyria/lissencephaly, a distinct brain malformation in which reduced or absent cortical folding is combined with a thick cortex. Pachygyria and PMG may look similar on low-resolution neuroimaging (e.g., CT) because in both conditions the cortical thickness can appear to be increased and the gyri can appear to be broad and smooth. The cortex in PMG is overfolded but not thickened. The microgyri and microsulci of PMG and stippling of the gray-white junction that can be appreciated with high-quality MRI can distinguish PMG from pachygyria [Leventer et al 2010].
- Cobblestone lissencephaly, a brain surface that has a bumpy contour resulting from migration of neurons and glial cells through the basement membrane into the leptomeninges. Sometimes regions populated by these misplaced cells are incorrectly initially diagnosed as PMG based on the MRI appearance and are only distinguished from PMG by the presence of other brain abnormalities (e.g., white matter and cerebellar abnormalities) in combination with ocular anomalies and congenital muscular dystrophy. The cobblestone lissencephalies comprise brain malformations associated with congenital muscular dystrophy, including Walker-Warburg syndrome, muscle-eye-brain disease, and [Fukuyama congenital muscular dystrophy](#).
- Schizencephaly, a specific pattern of PMG that describes a full-thickness cleft in the brain lined by PMG. While either CT or MRI is usually sufficient to diagnose schizencephaly, MRI is preferred when determining if the schizencephaly is open- or closed-lipped.

2. Genetic Causes of Polymicrogyria

Genetic causes of polymicrogyria (PMG) include both contiguous-gene and single-gene disorders.

Contiguous-Gene Disorders

PMG has been implicated in a number of chromosome copy number variants (CNVs) (summarized in Robin et al [2006], Dobyns et al [2008]).

The most common copy number variants associated with PMG:

- [22q11.2 deletion](#), characterized by cardiac defects, parathyroid hypoplasia, facial dysmorphism, and thymus hypoplasia, ± microcephaly and bilateral perisylvian PMG
- [1p36 deletion \(OMIM 607872\)](#), characterized by developmental delay / intellectual disability and dysmorphic facial features, ± microcephaly and bilateral perisylvian PMG

Other copy number variants with which PMG may be associated are deletion of 4q21, 6q26, 13q3, 18p11, and 21q2 and duplication of 2p13 [Guerrini & Dobyns 2014].

Single-Gene Disorders

To date more than 40 genes have been associated with PMG. This *GeneReview* covers the following pathways and groups of related disorders implicated in PMG:

- The mTORopathies (the PI3K-AKT-MTOR pathway)

- The tubulinopathies
- Cobblestone dysplasia – alpha dystroglycanopathies
- Cobblestone dysplasia – other (including laminopathies and congenital disorders of glycosylation)
- Other pathways/pathologies

Table 2 presents the genes associated with the above categories (in alphabetic order within each category). Several conditions with PMG are described in more detail following Table 2.

Additional disorders not included in Table 2 are [Aicardi syndrome](#) (in which PMG is almost uniformly seen) [Hetts et al 2006], and the monogenic syndromes [Mowat-Wilson syndrome](#), Yunis Varon syndrome [Baulac et al 2014], Adams-Oliver syndrome [Amor et al 2000], and Sturge-Weber syndrome (in all of which PMG is seen at low frequency).

Table 2. PMG-Associated Genes Grouped by Pathway/Pathology

Pathway/ Pathology	Gene ¹	Head Size ²			Brain Findings	Disorder Name	MOI	Reference ³
		MAC	MIC	N/ MS				
mTORopathies	<i>AKT3</i>	x			Bilateral perisylvian PMG	MPPH syndrome	AD	MPPH Syndrome
	<i>CCND2</i>	x				Smith-Kingsmore syndrome	AD	OMIM 616638
	<i>MTOR</i>	x						
	<i>PI4KA</i>			x	Perisylvian PMG		AR	PI4KA-Related Disorder
	<i>PIK3CA</i>	x			Bilateral perisylvian PMG	MCAP syndrome	See footnote 5.	PIK3CA-Related Segmental Overgrowth
	<i>PIK3R2</i>	x				MPPH syndrome	AD	MPPH Syndrome
	<i>PTEN</i>	x			Diffuse, focal, or multifocal PMG		AD	Elia et al [2012], Saletti et al [2017]
Tubulinopathies	<i>DYNC1H1</i>		x	x	Frontal or diffuse PMG		AD	OMIM 600112
	<i>KIF5C</i>			x	Perisylvian PMG		AD	OMIM 615282
	<i>TUBA1A</i>		x	x	Diffuse, focal, or multifocal PMG; bilateral, asymmetric, perisylvian PMG	Lissencephaly 3	AD	Tubulinopathies Overview
	<i>TUBB</i>		x		PMG		AD	
	<i>TUBB2A</i>		x		Bilateral, asymmetric, anterior predominant PMG		AD	
	<i>TUBB2B</i>		x	x				
	<i>TUBB3</i>		x	x	Frontoparietal PMG		AD	

Table 2. continued from previous page.

Pathway/ Pathology	Gene ¹	Head Size ²			Brain Findings	Disorder Name	MOI	Reference ³
		MAC	MIC	N/ MS				
Cobblestone dysplasia – alpha dystroglycanopathies	<i>FKTN</i>			x	Diffuse (cerebral & cerebellar) PMG		AR	Fukuyama Congenital Muscular Dystrophy
	<i>POMGNT1</i>			x	PMG		AR	OMIM 606822
	<i>POMT2</i>			x	PMG		AR	OMIM 607439
Cobblestone dysplasia – other (incl laminopathies & congenital disorders of glycosylation)	<i>ADGRG1 (GPR56)</i>			x	Bilateral frontoparietal PMG		AR	OMIM 604110
	<i>COL3A1</i>	x		x	Diffuse cobblestone cortex; PMG A > P		AR	Horn et al [2017]
	<i>ATP6V0A2</i>		x	x	Frontoparietal PMG	Autosomal recessive cutis laxa type 2A	AR	ATP6V0A2-Related Cutis Laxa
	<i>LAMA2</i>			x	Occipital PMG; white-matter signal abnormalities	Muscular dystrophy, congenital merosin-deficient, 1A	AR	OMIM 607855
	<i>LAMB1</i>	x		x	Porencephaly; cobblestone lissencephaly P > A	Lissencephaly 5	AR	OMIM 615191
	<i>LAMC3</i>			x	Occipital PMG		AR	OMIM 614115
	<i>SNAP29</i>		x		Perisylvian or diffuse PMG		AR	OMIM 609528
	<i>SRD5A3</i>			x	Frontal PMG	SRD5A3-CDG (<i>CDG-Iq</i>)	AR	Congenital Disorders of N-Linked Glycosylation and Multiple Pathway Overview
Other	<i>BICD2</i>			x	Perisylvian PMG		AD	Ravenscroft et al [2016]
	<i>COL18A1</i>			x	Frontal PMG	Knobloch syndrome 1	AR	Keren et al [2007]
	<i>DDX3X</i>		x	x	Frontoparietal or diffuse PMG	<i>DDX3X</i> -related neurodevelopmental disorder	XL	DDX3X-Related Neurodevelopmental Disorder
	<i>EML1</i>	x			Ribbon-like heterotopia w/ overlying PMG; ACC		AR	OMIM 600348
	<i>EOMES (TBR2)</i>		x		Bilateral perisylvian or diffuse PMG		AR	OMIM 604615

Table 2. continued from previous page.

Pathway/ Pathology	Gene ¹	Head Size ²			Brain Findings	Disorder Name	MOI	Reference ³
		MAC	MIC	N/ MS				
	<i>EZH2</i>	x			Bilateral perisylvian PMG	Weaver syndrome	AD	EZH2-Related Overgrowth
	<i>FIG4</i>		x	x	Bilateral or temporo-occipital PMG		AR	OMIM 612691
	<i>GPSM2</i>	x			Parasagittal PMG; ACC	Chudley-McCollough syndrome	AR	OMIM 604213
	<i>GRIN1</i>		x		Extensive bilateral PMG		AD	GRIN1-Related Neurodevelopmental Disorder
	<i>GRIN2B</i>		x	x	Diffuse PMG		AD	GRIN2B-Related Neurodevelopmental Disorder
	<i>KIFBP</i> (<i>KIAA1279</i>)		x		Diffuse PMG	Goldberg-Shprintzen syndrome	AR	OMIM 609460
	<i>MAP1B</i>				Perisylvian PMG; PNH		AD	Heinzen et al [2018]
	<i>NDE1</i>		x		Diffuse PMG		AR	OMIM 609449
	<i>NEDD4L</i>			x	Bilateral perisylvian PMG; PNH		AD	Kato et al [2017]
	<i>OCLN</i>		x		Band-like calcifications w/ diffuse PMG	Pseudo-TORCH syndrome 1	AR	OMIM 251290
	<i>OFD1</i>	x			Frontal and parietal PMG	Joubert syndrome (XLR); orofaciodigital syndrome 1 (XLD)	XL	Joubert Syndrome
	<i>PAX6</i>		x		Variable temporal PMG		AR	OMIM 607108
	<i>RAB18</i>		x	x	Diffuse or frontal PMG	RAB18 deficiency ⁴	AR	RAB18 Deficiency
	<i>RAB3GAP1</i>		x	x				
	<i>RAB3GAP2</i>		x	x				
	<i>RTTN</i>		x		Variable diffuse, asymmetric PMG		AR	OMIM 614833
	<i>TBC1D20</i>			x	Diffuse or bilateral frontal PMG	RAB18 deficiency ⁴	AR	RAB18 Deficiency
	<i>TCTN1</i>			x	Frontal PMG	Joubert syndrome	AR	Joubert Syndrome
	<i>TMEM216</i>			x	Variable PMG	Meckel-Gruber syndrome, Joubert syndrome	AR	

Table 2. continued from previous page.

Pathway/ Pathology	Gene ¹	Head Size ²			Brain Findings	Disorder Name	MOI	Reference ³
		MAC	MIC	N/ MS				
	<i>WDR62</i>		x		± diffuse or asymmetric PMG	AR	WDR62 Primary Microcephaly	

Note: The table does not list genes that can be associated with PMG and metabolic disorders (Table 3), disorders of peroxisomal biogenesis (see [Zellweger Spectrum Disorder](#)), or mitochondrial disorders (see [Mitochondrial Disorders Overview](#)).

A = anterior; ACC = absence of the corpus callosum; AD = autosomal dominant; AR = autosomal recessive; CDG = congenital disorder of glycosylation; MCAP = megalencephaly-capillary malformation-PMG; MOI = mode of inheritance; MPPH = megalencephaly-polymicrogyria-polydactyly-hydrocephalus; P = posterior; PNH = periventricular nodular heterotopia; XL = X-linked; XLD = X-linked dominant; XLR = X-linked recessive

1. Genes are in alphabetic order.

2. Head size:

N/MS = normal / mildly small (i.e., head circumference >3 SD and <97%)

MIC = severe microcephaly (i.e., birth head circumference <3 SD or earliest HC <4 SD)

MAC = macrocephaly (i.e., head circumference >97%)

3. *GeneReview*, citation, or OMIM entry

4. RAB18 deficiency is a spectrum that includes Warburg micro syndrome (at the severe end) and Martsolf syndrome (at the mild end). Additional findings are eye involvement (bilateral congenital cataracts, microphthalmia, and microcornea); severe-to-profound intellectual disability; and hypogonadism.

5. Most affected individuals with MCAP reported to date (21/24) had somatic mosaicism for pathogenic variants in *PIK3CA*, suggesting that mutation occurred post fertilization in one cell of the multicellular embryo. Two of 24 affected individuals had a *de novo* germline pathogenic variant in *PIK3CA*.

Tubulinopathies (see [Tubulinopathies Overview](#)) are caused by a heterozygous pathogenic variant in *TUBA1A* (see Note), *TUBB*, *TUBB2A*, *TUBB2B*, or *TUBB3* – genes encoding different isoforms of α -tubulin. Brain malformations include asymmetric perisylvian PMG with callosal defects, cerebellar vermis dysplasia, pontine hypoplasia, and dysmorphic basal ganglia. Because dysmorphic basal ganglia [Amrom et al 2014] and atypical microgyration (which may not be as evident as in typical PMG) are common in tubulin-associated PMG, it has been proposed that these complex cortical malformations be called "tubulin-associated dysgyria."

Note: While heterozygous pathogenic variants in *TUBA1A* can be associated with PMG, they are more frequently associated with pachygyria [Jansen et al 2011].

ADGRG1 (formerly *GPR56*). The spectrum of brain malformations includes the relatively rare phenotype of bilateral frontoparietal-predominant PMG [Piao et al 2005], a cobblestone-like lissencephaly (with no eye or muscle involvement), cerebellar dysplasia, and diffuse myelination abnormalities [Dobyns et al 1996, Bahi-Buisson et al 2010]. Although biallelic *ADGRG1* pathogenic variants were initially reported as a cause of bilateral frontoparietal PMG (BFPP), subsequent reports and further delineation of the phenotype showed that the cortical malformation was most often cobblestone in nature or complex cortical dysgyria resembling PMG, rather than typical PMG [Bahi-Buisson et al 2010].

Metabolic disorders most commonly reported with PMG are summarized in Table 3.

Table 3. Selected Metabolic Disorders Commonly Associated with PMG

Disorder	Reference (<i>GeneReview</i> or OMIM)
Classic nonketotic hyperglycinemia	Classic Nonketotic Hyperglycinemia
Fumaric aciduria ¹	OMIM 136850
Glutaric acidemia type II	Multiple Acyl-CoA Dehydrogenase Deficiency
Histidinemia	OMIM 235800

Table 3. continued from previous page.

Disorder	Reference (<i>GeneReview</i> or OMIM)
Maple syrup urine disease	Maple Syrup Urine Disease
Mitochondrial disorders	Mitochondrial Disorders Overview
Pyruvate dehydrogenase deficiency	OMIM PS312170
Zellweger spectrum disorder ¹	Zellweger Spectrum Disorder

1. Zellweger syndrome and fumaric aciduria are the most common metabolic causes of PMG of those addressed in Table 3. Zellweger syndrome and fumaric aciduria are typically identified by additional clinical features.

3. Evaluation Strategy to Identify the Genetic Cause of PMG in a Proband

The approach outlined in this section can be used to determine if a specific genetic cause or mode of inheritance can be identified to aid in discussions of prognosis and genetic counseling.

Confirming the Clinical Diagnosis

Confirming PMG as the underlying cortical malformation and ruling out other brain malformations that may be confused with PMG (e.g., pachgyria and other forms of cortical dysplasia) requires consultation with an expert in interpretation of the MRI findings of PMG. Note that while the gold standard for the diagnosis of PMG is postmortem histopathologic examination, the clinical diagnosis relies on neuroimaging.

History

Pregnancy. A detailed pregnancy history with attention to infections, trauma, multiple gestations, and other documented problems that could provide insight into possible acquired causes of PMG. PMG is commonly associated with congenital cytomegalovirus [Kwak et al 2018].

Family. Parental consanguinity may suggest an autosomal recessive disorder (Table 2).

If no genetic cause has been identified and if familial PMG is suspected, it may be reasonable to perform a brain MRI (if not previously performed) on close relatives (i.e., parents or sibs) with the following:

- Neurologic problems including seizures, cognitive delay, motor impairment, pseudobulbar signs, and/or focal weakness
- What appear to be minor findings, such as a lisp or an isolated learning disability

Medical. Other specific tests targeting individual neurometabolic disorders can be obtained if clinically suggested (see Table 3).

Physical Examination

Head size is a useful first step in clinical assessment to aid in focusing genetic testing.

Macrocephaly is the group in which a genetic cause of PMG is most likely to be identified. The most common disorders with macrocephaly are the PI3K-AKT-MTOR-related disorders. Diagnostic possibilities:

- In the absence of systemic findings: [MPPH syndrome](#)

Note that a subset of individuals have hydrocephalus (requiring shunting) and/or polydactyly of fingers/toes.

- In the presence of other systemic features such as somatic overgrowth or pigmentary skin changes:
 - [MCAP](#) (vascular-lymphatic abnormalities)
 - [MTOR-related disorders](#) (linear pigmentary skin changes)
 - [PTEN-related disorders](#) (features of [PTEN-hamartoma tumor syndrome](#))

Microcephaly, a highly genetically heterogeneous group that includes numerous multisystem disorders, requires thorough physical assessment and detailed review of the brain MRI findings. Diagnostic possibilities in the presence of:

- Fetal brain disruption pattern on imaging:
 - [NDE1-related lissencephaly](#)
 - [WDR62-related microcephaly](#)
- Complex additional brain malformations:
 - Pseudo-TORCH syndrome
 - [RAB18 deficiency](#)
 - Tubulinopathies (typically patchy and asymmetric cortical dysplasia with callosal, cerebellar, and brain stem anomalies) (See [Tubulinopathies Overview](#).)

Normocephaly (or borderline microcephaly). The most commonly identified genetic factors are copy number variants resulting in disorders such as [22q11.2 deletion](#) and [1p36 deletion](#) (OMIM [607872](#)), which involve multiple systems and have numerous additional features including (but not limited to) intellectual disability, dysmorphic facial features, and congenital heart defects.

A general physical examination should look for any associated craniofacial, musculoskeletal, and/or visceral findings that could indicate the mostly commonly considered syndromes (Table 2).

Molecular Genetic Testing

Testing approaches can include a combination of gene-targeted testing (single-gene testing or a multigene panel) and comprehensive genomic testing (exome sequencing, exome array, or chromosomal microarray analysis [CMA]). Gene-targeted testing requires the clinician to hypothesize which gene(s) are likely involved, whereas genomic testing does not. Options include the following:

- **Serial single-gene testing** can be considered if clinical findings and/or family history indicate that pathogenic variants in a particular gene are most likely (see Table 2). Sequence analysis of the most likely gene is performed first, followed by gene-targeted deletion/duplication analysis as indicated.
- **A PMG multigene panel** that includes some or all of the genes listed in Table 2 is most likely to identify the genetic cause of PMG while limiting identification of variants of uncertain significance and pathogenic variants in genes that do not explain the underlying phenotype. Note: (1) The genes included in the panel and the diagnostic sensitivity of the testing used for each gene vary by laboratory and are likely to change over time. (2) Some multigene panels may include genes not associated with the condition discussed in this *GeneReview*. Of note, given the rarity of some of the genes associated with PMG, some panels may not include all of the genes listed in Table 2. (3) In some laboratories, panel options may include a custom laboratory-designed panel and/or custom phenotype-focused exome analysis that includes genes specified by the clinician. (4) Methods used in a panel may include sequence analysis, deletion/duplication analysis, and/or other non-sequencing-based tests. For this disorder a multigene panel that also includes deletion/duplication analysis is recommended.

For an introduction to multigene panels click [here](#). More detailed information for clinicians ordering genetic tests can be found [here](#).

- **Chromosomal microarray analysis (CMA)** using oligonucleotide or SNP arrays to detect genome-wide large deletions/duplications that cannot be detected by sequence analysis may be considered in individuals with distinguishing phenotypic features suggestive of a contiguous gene deletion (see Genetic Causes of Polymicrogyria, Contiguous-Gene Disorders).
- **Comprehensive genomic testing** (which does not require the clinician to determine which gene[s] are likely involved) may be considered. **Exome sequencing** is most commonly used; **genome sequencing** is also possible. **Exome array** (when clinically available) may be considered if exome sequencing is not diagnostic.

For an introduction to comprehensive genomic testing click [here](#). More detailed information for clinicians ordering genomic testing can be found [here](#).

4. Genetic Counseling of Family Members of an Individual with PMG

Genetic counseling is the process of providing individuals and families with information on the nature, mode(s) of inheritance, and implications of genetic disorders to help them make informed medical and personal decisions. The following section deals with genetic risk assessment and the use of family history and genetic testing to clarify genetic status for family members; it is not meant to address all personal, cultural, or ethical issues that may arise or to substitute for consultation with a genetics professional. —ED.

Mode of Inheritance

Hereditary polymicrogyria (PMG) may be inherited in an autosomal dominant, autosomal recessive, or X-linked manner. Genetic counseling and risk assessment depend on determination of the specific genetic cause of PMG in an individual.

Autosomal Dominant Inheritance – Risk to Family Members

Parents of a proband

- Some individuals diagnosed with PMG have an affected parent.
- Many individuals diagnosed with PMG have the disorder as the result of a *de novo* pathogenic variant.
- Recommendations for the evaluation of parents of a proband with an apparent *de novo* pathogenic variant (i.e., the proband appears to be the only affected family member) include molecular genetic testing.
- The family history may appear to be negative because of failure to recognize the disorder in a family member or reduced penetrance in a heterozygous parent. Therefore, an apparently negative family history cannot be confirmed unless appropriate molecular genetic testing and/or clinical evaluation has been performed.
- Note: Due to reduced penetrance, there may be asymptomatic family members or several generations of individuals with the pathogenic variant who remain symptom-free.

Sibs of a proband. The risk to sibs depends on the genetic status of the proband's parents: if one of the proband's parents has a PMG-related pathogenic variant, the risk to the sibs of inheriting the pathogenic variant is 50%. Note that phenotypic variability can be observed within families.

Offspring of a proband. Each child of an individual with autosomal dominant PMG has a 50% chance of inheriting the pathogenic variant.

Other family members. The risk to other family members depends on the status of the proband's parents: if a parent has the PMG-related pathogenic variant, the parent's family members may be at risk.

Autosomal Recessive Inheritance – Risk to Family Members

Parents of a proband

- The parents of an affected individual are obligate heterozygotes (i.e., carriers of one PMG-related pathogenic variant).
- Heterozygotes are asymptomatic.

Sibs of a proband. At conception, each sib of a proband has a 25% chance of being affected, a 50% chance of being an asymptomatic carrier (heterozygote), and a 25% chance of being unaffected and not a carrier.

Offspring of a proband. All offspring are obligate heterozygotes (carriers) for a pathogenic variant in a PMG-related gene.

Other family members. Each sib of the proband's parents is at a 50% risk of being a carrier of a PMG-related pathogenic variant.

Carrier detection. Carrier testing for at-risk relatives requires prior identification of the PMG-related pathogenic variants in the family.

X-Linked Inheritance – Risk to Family Members

Parents of a male proband

- The father of an affected male will not have the disorder nor will he be hemizygous for the PMG-related pathogenic variant; therefore, he does not require further evaluation/testing.
- In a family with more than one affected individual, the mother of an affected male is an obligate heterozygote (carrier). Note: If a woman has more than one affected child and no other affected relatives and if the PMG-related pathogenic variant cannot be detected in her leukocyte DNA, she most likely has germline mosaicism.
- If a male is the only affected family member (i.e., a simplex case), the mother may be a heterozygote (carrier) or the affected male may have a *de novo* pathogenic variant, in which case the mother is not a carrier.

Parents of a female proband. See [Oral-Facial-Digital Syndrome Type I](#).

Sibs of a male proband. The risk to sibs depends on the genetic status of the proband's mother:

- If the mother of the proband has the PMG-related pathogenic variant, the chance of transmitting it in each pregnancy is 50%. Males who inherit the variant will be affected; females who inherit the variant will be heterozygotes (carriers) and will not typically be affected.
- If the proband represents a simplex case (i.e., a single occurrence in a family) and if the PMG-related pathogenic variant cannot be detected in the leukocyte DNA of the mother, the risk to sibs is slightly greater than that of the general population (though still <1%) because of the possibility of maternal germline mosaicism.

Sibs of a female proband. See [Oral-Facial-Digital Syndrome Type I](#).

Offspring of a proband. Affected males will transmit the pathogenic variant to all of their daughters and none of their sons.

Other family members. The proband's maternal aunts may be at risk of being heterozygotes (carriers) for the pathogenic variant, and the aunts' offspring, depending on their sex, may be at risk of being heterozygotes (carriers) for the pathogenic variant or of being affected.

Heterozygote detection. Molecular genetic testing of at-risk female relatives to determine their genetic status is most informative if the PMG-related pathogenic variant has been identified in the proband.

Prenatal Testing and Preimplantation Genetic Testing

Once the PMG-related pathogenic variant(s) have been identified in an affected family member, prenatal and preimplantation genetic testing are possible.

Differences in perspective may exist among medical professionals and within families regarding the use of prenatal testing. While most centers would consider use of prenatal testing to be a personal decision, discussion of these issues may be helpful.

Resources

GeneReviews staff has selected the following disease-specific and/or umbrella support organizations and/or registries for the benefit of individuals with this disorder and their families. GeneReviews is not responsible for the information provided by other organizations. For information on selection criteria, click [here](#).

- **PMG Awareness Organization, Inc.**
Phone: 949-329-5975
Email: information@pmgawareness.org
www.pmgawareness.org
- **MedlinePlus**
[Polymicrogyria](#)

Chapter Notes

Author Notes

Dr Ghayda Mirzaa is a geneticist and researcher at Seattle Children's Hospital. The goal of her research is to study the underlying causes, natural history, and medical management of developmental brain disorders including brain malformations, autism, and epilepsy.

Acknowledgments

We acknowledge the assistance of Ms Stefanie Brock in the preparation of Table 2.

Author History

Kira Apse, ScM; Harvard Medical School (2004-2018)

Adria Bodell, MS, CGC; Harvard Medical School (2004-2018)

Bernard Chang, MD; Harvard Medical School (2004-2018)

William Dobyns, MD (2018-present)

Anna Jansen, MD, PhD (2018-present)

Richard J Leventer, MBBS, BMedSci, PhD, FRACP (2018-present)

Ghayda Mirzaa, MD (2018-present)

Chloe Stutterd, MBBS, FRACP (2018-present)

Christopher A Walsh, MD, PhD; Harvard Medical School (2004-2018)

Revision History

- 16 August 2018 (bp) Comprehensive update posted live
- 6 August 2007 (me) Comprehensive update posted live
- 18 April 2005 (me) Overview posted live
- 24 August 2004 (bc) Original submission

References

Literature Cited

- Amor DJ, Leventer RJ, Hayllar S, Bankier A. Polymicrogyria associated with scalp and limb defects: variant of Adams-Oliver syndrome. *Am J Med Genet.* 2000;93:328-34. PubMed PMID: 10946361.
- Amrom D, Tanyalçın I, Verhelst H, Deconinck N, Brouhard GJ, Décarie JC, Vanderhasselt T, Das S, Hamdan FF, Lissens W, Michaud JL, Jansen AC. Polymicrogyria with dysmorphic basal ganglia? Think tubulin! *Clin Genet.* 2014;85:178-83. PubMed PMID: 23495813.
- Bahi-Buisson N, Poirier K, Boddaert N, Fallet-Bianco C, Specchio N, Bertini E, Caglayan O, Lascelles K, Elie C, Rambaud J, Baulac M, An I, Dias P, des Portes V, Moutard ML, Soufflet C, El Maleh M, Beldjord C, Villard L, Chelly J. GPR56-related bilateral frontoparietal polymicrogyria: further evidence for an overlap with the cobblestone complex. *Brain.* 2010;133:3194-209. PubMed PMID: 20929962.
- Barkovich AJ. MRI analysis of sulcation morphology in polymicrogyria. *Epilepsia.* 2010;51 Suppl 1 :17-22. PubMed PMID: 20331706.
- Baulac S, Lenk GM, Dufresnois B, Ouled Amar Bencheikh B, Couarch P, Renard J, Larson PA, Ferguson CJ, Noé E, Poirier K, Hubans C, Ferreira S, Guerrini R, Ouazzani R, El Hachimi KH, Meisler MH, Leguern E. Role of the phosphoinositide phosphatase FIG4 gene in familial epilepsy with polymicrogyria. *Neurology.* 2014;82:1068-75 PubMed PMID: 24598713.
- Dobyns WB, Mirzaa G, Christian SL, Petras K, Roseberry J, Clark GD, Curry CJ, McDonald-McGinn D, Medne L, Zackai E, Parsons J, Zand DJ, Hisama FM, Walsh CA, Leventer RJ, Martin CL, Gajecka M, Shaffer LG. Consistent chromosome abnormalities identify novel polymicrogyria loci in 1p36.3, 2p16.1-p23.1, 4q21.21-q22.1, 6q26-q27, and 21q2. *Am J Med Genet A.* 2008;146A:1637-54. PubMed PMID: 18536050.
- Dobyns WB, Patton MA, Stratton RF, Mastrobattista JM, Blanton SH, Northrup H. Cobblestone lissencephaly with normal eyes and muscle. *Neuropediatrics.* 1996;27:70-5. PubMed PMID: 8737821.
- Elia M, Amato C, Bottitta M, Grillo L, Calabrese G, Esposito M, Carotenuto M. An atypical patient with Cowden syndrome and PTEN gene mutation presenting with cortical malformation and focal epilepsy. *Brain Dev.* 2012;34:873-6. PubMed PMID: 22469695.
- Guerrini R, Dobyns WB. Malformations of cortical development: clinical features and genetic causes. *Lancet Neurol.* 2014;13:710-26. PubMed PMID: 24932993.
- Heinzen EL, O'Neill AC, Zhu X, Allen AS, Bahlo M, Chelly J, Chen MH, Dobyns WB, Freytag S, Guerrini R, Leventer RJ, Poduri A, Robertson SP, Walsh CA, Zhang M, et al. De novo and inherited private variants in MAP1B in periventricular nodular heterotopia. *PLoS Genet.* 2018;14:e1007281. PubMed PMID: 29738522.
- Hetts SW, Sherr EH, Chao S, Gobuty S, Barkovich AJ. Anomalies of the corpus callosum: an MR analysis of the phenotypic spectrum of associated malformations. *AJR Am J Roentgenol.* 2006;187:1343-8. PubMed PMID: 17056927.

- Horn D, Siebert E, Seidel U, Rost I, Mayer K, Abou Jamra R, Mitter D, Kornak U. Biallelic COL3A1 mutations result in a clinical spectrum of specific structural brain anomalies and connective tissue abnormalities. *Am J Med Genet A*. 2017;173:2534-8. PubMed PMID: 28742248.
- Jansen AC, Oostra A, Desprechins B, De Vlaeminck Y, Verhelst H, Régál L, Verloo P, Bockaert N, Keymolen K, Seneca S, De Meirleir L, Lissens W. TUBA1A mutations: from isolated lissencephaly to familial polymicrogyria. *Neurology*. 2011;76:988-92. PubMed PMID: 21403111.
- Kato K, Miya F, Hori I, Ieda D, Ohashi K, Negishi Y, Hattori A, Okamoto N, Kato M, Tsunoda T, Yamasaki M, Kanemura Y, Kosaki K, Saitoh S. A novel missense mutation in the HECT domain of NEDD4L identified in a girl with periventricular nodular heterotopia, polymicrogyria and cleft palate. *J Hum Genet*. 2017;62:861-3. PubMed PMID: 28515470.
- Keren B, Suzuki OT, Gérard-Blanluet M, Brémond-Gignac D, Elmaleh M, Titomanlio L, Delezoide AL, Passos-Bueno MR, Verloes A. CNS malformations in Knobloch syndrome with splice mutation in COL18A1 gene. *Am J Med Genet A*. 2007;143A:1514-8. PubMed PMID: 17546652.
- Kuzniecky R, Andermann F, Guerrini R. Congenital bilateral perisylvian syndrome: study of 31 patients. The CBPS Multicenter Collaborative Study. *Lancet*. 1993;341:608-12. PubMed PMID: 8094839.
- Kwak M, Yum MS, Yeh HR, Kim HJ, Ko TS. Brain magnetic resonance imaging findings of congenital cytomegalovirus infection as a prognostic factor for neurological outcome. *Pediatr Neurol*. 2018;83:14-18. PubMed PMID: 29681488.
- Leventer RJ, Jansen A, Pilz DT, Stoodley N, Marini C, Dubeau F, Malone J, Mitchell LA, Mandelstam S, Scheffer IE, Berkovic SF, Andermann F, Andermann E, Guerrini R, Dobyns WB. Clinical and imaging heterogeneity of polymicrogyria: a study of 328 patients. *Brain*. 2010;133:1415-27. PubMed PMID: 20403963.
- Leventer RJ, Phelan EM, Coleman LT, Kean MJ, Jackson GD, Harvey AS. Clinical and imaging features of cortical malformations in childhood. *Neurology*. 1999;53:715-22. PubMed PMID: 10489031.
- Piao X, Chang BS, Bodell A, Woods K, Benzeev B, Topcu M, Guerrini R, Goldberg-Stern H, Sztriha L, Dobyns WB, Barkovich AJ, Walsh CA. Genotype-phenotype analysis of human frontoparietal polymicrogyria syndromes. *Ann Neurol*. 2005;58:680-7. PubMed PMID: 16240336.
- Ravenscroft G, Di Donato N, Hahn G, Davis MR, Craven PD, Poke G, Neas KR, Neuhann TM, Dobyns WB, Laing NG. Recurrent de novo BICD2 mutation associated with arthrogryposis multiplex congenita and bilateral perisylvian polymicrogyria. *Neuromuscul Disord*. 2016;26:744-8. PubMed PMID: 27751653.
- Robin NH, Taylor CJ, McDonald-McGinn DM, Zackai EH, Bingham P, Collins KJ, Earl D, Gill D, Granata T, Guerrini R, Katz N, Kimonis V, Lin JP, Lynch DR, Mohammed SN, Massey RF, McDonald M, Rogers RC, Splitt M, Stevens CA, Tischkowitz MD, Stoodley N, Leventer RJ, Pilz DT, Dobyns WB. Polymicrogyria and deletion 22q11.2 syndrome: window to the etiology of a common cortical malformation. *Am J Med Genet A*. 2006;140:2416-25. PubMed PMID: 17036343.
- Saletti V, Esposito S, Maccaro A, Giglio S, Valentini LG, Chiapparini L. Chiari I malformation in a child with PTEN hamartoma tumor syndrome: association or coincidence? *Eur J Med Genet*. 2017;60:261-4. PubMed PMID: 28286253.

License

GeneReviews® chapters are owned by the University of Washington. Permission is hereby granted to reproduce, distribute, and translate copies of content materials for noncommercial research purposes only, provided that (i) credit for source (<http://www.genereviews.org/>) and copyright (© 1993-2024 University of Washington) are included with each copy; (ii) a link to the original material is provided whenever the material is published elsewhere on the Web; and (iii) reproducers, distributors, and/or translators comply with the [GeneReviews® Copyright Notice and Usage Disclaimer](#). No further modifications are allowed. For clarity, excerpts of GeneReviews chapters for use in lab reports and clinic notes are a permitted use.

For more information, see the [GeneReviews® Copyright Notice and Usage Disclaimer](#).

For questions regarding permissions or whether a specified use is allowed, contact: admasst@uw.edu.