



X-Linked Congenital Retinoschisis

Synonym: X-Linked Retinoschisis

Paul A Sieving, MD, PhD,¹ Ian M MacDonald, MD, CM,² and Stephanie Hoang, MSc³

Created: October 24, 2003; Updated: November 5, 2020.

Summary

Clinical characteristics

X-linked congenital retinoschisis (XLRS) is characterized by symmetric bilateral macular involvement with onset in the first decade of life, in some cases as early as age three months. Fundus examination shows areas of schisis (splitting of the nerve fiber layer of the retina) in the macula, sometimes giving the impression of a spoke wheel pattern. Schisis of the peripheral retina, predominantly inferotemporally, occurs in approximately 50% of individuals. Affected males typically have 20/60 to 20/120 vision. Visual acuity often deteriorates during the first and second decades of life but then remains relatively stable until the fifth or sixth decade.

Diagnosis/testing

The diagnosis of XLRS is established in a male proband with suggestive ophthalmologic findings and a hemizygous pathogenic variant in *RS1* identified by molecular genetic testing.

Management

Treatment of manifestations: Management of refractive errors and amblyopia is per standard care. Amblyopia prevention therapy is indicated following surgical intervention for vitreous hemorrhage or retinal detachment or in instances of severe retinoschisis or hypermetropia.

Low-vision aids such as large-print textbooks; preferential seating in the front of the classroom; and use of handouts with high contrast. Surgery may be required to address the infrequent complications of vitreous hemorrhage and full-thickness retinal detachment.

Author Affiliations: 1 Professor of Ophthalmology, Director of the Center for Ocular Regenerative Therapy (CORT), University of California, Davis, Sacramento, California; Email: pasieving@ucdavis.edu. 2 Professor, Department of Ophthalmology and Visual Sciences, University of Alberta, Royal Alexandra Hospital, Edmonton, Alberta, Canada; Email: macdonal@ualberta.ca. 3 Genetic Counselor, Department of Medical Genetics, University of Alberta Hospital, Edmonton, Alberta, Canada; Email: stephanie.hoang@albertahealthservices.ca.

Surveillance: Annual evaluation of children younger than age ten years by a pediatric ophthalmologist or retina specialist; patient education and close follow up may allow for early identification of refractive errors and treatment of vision-threatening complications (retinal detachment).

Agents/circumstances to avoid: Head trauma and high-contact sports to reduce risk of retinal detachment and vitreous hemorrhage.

Genetic counseling

XLRS is inherited in an X-linked manner. Heterozygous females have a 50% chance of transmitting the pathogenic variant in each pregnancy: males who inherit the pathogenic variant will be affected; females who inherit the pathogenic variant will be carriers and will nearly always have normal visual function. Affected males transmit the pathogenic variant to all of their daughters and none of their sons. Once the *RS1* pathogenic variant in the family is known, carrier testing for at-risk female relatives, prenatal testing for pregnancies at increased risk, and preimplantation genetic testing are possible.

Diagnosis

Suggestive Findings

X-linked congenital retinoschisis (XLRS) **should be suspected** in males with following ophthalmologic findings and family history.

Ophthalmologic findings

- Bilaterally reduced visual acuity, typically between 20/60 and 20/120
- No presenting complaint of “night blindness” (i.e., vision difficulty in dim lighting)
- Fundus examination revealing:
 - Areas of schisis (cavities and splitting through the deeper retinal layers) in the macula, frequently giving the impression of a spoke wheel pattern (Figure 1).
 - Schisis of the peripheral retina, predominantly inferotemporally, in approximately 50% of individuals [Eksandh et al 2000]. The associated elevation of the surface layer of the retina into the vitreous has been described as “vitreous veils” (Figure 2).
 - On occasion:
 - More severe involvement of the macula (Figure 3)
 - Presence of the Mizuo phenomenon, a color change in the retina after dark adaptation with the onset of light
 - Pigmentary retinal scarring in the periphery from resolution of previous tears of the inner retina layers
- Spectral domain optical coherence tomography (SD-OCT), currently the major diagnostic technique for XLRS, reveals characteristic intraretinal foveal schisis in younger men, while cystic spaces become less evident by middle age as the flattening of cysts (with the appearance of partial macular atrophy) occurs with age [Molday et al 2012].
- Electroretinogram (ERG) in more than half of affected males shows characteristic changes of greatly diminished dark-adapted b-wave amplitude despite relative preservation of the a-wave amplitude, termed an “electronegative ERG” [Nakamura et al 2001]. However, as some boys have a technically normal ERG b-wave [Sieving et al 1999, Eksandh et al 2005, Renner et al 2008], the ERG may give false negative results when relatively normal. Note: Progressive reduction of ERG b-wave amplitudes can occur in older men with severe pathogenic variants (e.g., null variants, splice variants, cysteine conformational disruptions) [Bowles et al 2011].
- Increased fundus autofluorescence in the fovea [Renner et al 2008, Molday et al 2012]

- Intravenous fluorescein angiogram appears normal in younger boys, with no apparent leakage, whereas older individuals may have atrophic changes and involvement of the retinal pigment epithelium.

Family history consistent with X-linked inheritance (e.g., no male-to-male transmission). Absence of a known family history does not preclude the diagnosis.

Establishing the Diagnosis

The diagnosis of XLRS is **established** in a male proband with suggestive ophthalmologic findings and a hemizygous pathogenic (or likely pathogenic) variant in *RS1* identified by molecular genetic testing (see Table 1).

Note: (1) Per ACMG/AMP variant interpretation guidelines, the terms "pathogenic variant" and "likely pathogenic variant" are synonymous in a clinical setting, meaning that both are considered diagnostic and can be used for clinical decision making [Richards et al 2015]. Reference to "pathogenic variants" in this *GeneReview* is understood to include likely pathogenic variants. (2) Identification of a hemizygous *RS1* variant of uncertain significance does not establish or rule out the diagnosis.

Molecular genetic testing approaches can include a combination of **gene-targeted testing** (single-gene testing, multigene panel) and **comprehensive genomic testing** (exome sequencing, genome sequencing) depending on the phenotype.

Gene-targeted testing requires that the clinician determine which gene(s) are likely involved, whereas genomic testing does not. Individuals with the distinctive findings described in Suggestive Findings are likely to be diagnosed using gene-targeted testing (see Option 1), whereas those in whom the diagnosis of XLRS has not been considered are more likely to be diagnosed using genomic testing (see Option 2).

Option 1

Single-gene testing. Sequence analysis of *RS1* is performed first to detect missense, nonsense, and splice site variants and small intragenic deletions/insertions. Note: Depending on the sequencing method used, single-exon, multiexon, or whole-gene deletions/duplications may not be detected. If no variant is detected by the sequencing method used, the next step is to perform gene-targeted deletion/duplication analysis to detect exon and whole-gene deletions or duplications.

Note: Targeted analysis can be performed first for the following pathogenic variants in individuals of Finnish ancestry [Huopaniemi et al 1999]:

- c.214G>A (p.Glu72Lys)
- c.221G>T (p.Gly74Val)
- c.325G>C (p.Gly109Arg)

An inherited retinal dystrophy multigene panel that includes *RS1* and other genes of interest (see Differential Diagnosis) is most likely to identify the genetic cause of the condition while limiting identification of variants of uncertain significance and pathogenic variants in genes that do not explain the underlying phenotype. Note: (1) The genes included in the panel and the diagnostic sensitivity of the testing used for each gene vary by laboratory and are likely to change over time. (2) Some multigene panels may include genes not associated with the condition discussed in this *GeneReview*. (3) In some laboratories, panel options may include a custom laboratory-designed panel and/or custom phenotype-focused exome analysis that includes genes specified by the clinician. (4) Methods used in a panel may include sequence analysis, deletion/duplication analysis, and/or other non-sequencing-based tests. For this disorder a multigene panel that also includes deletion/duplication analysis is recommended (see Table 1).

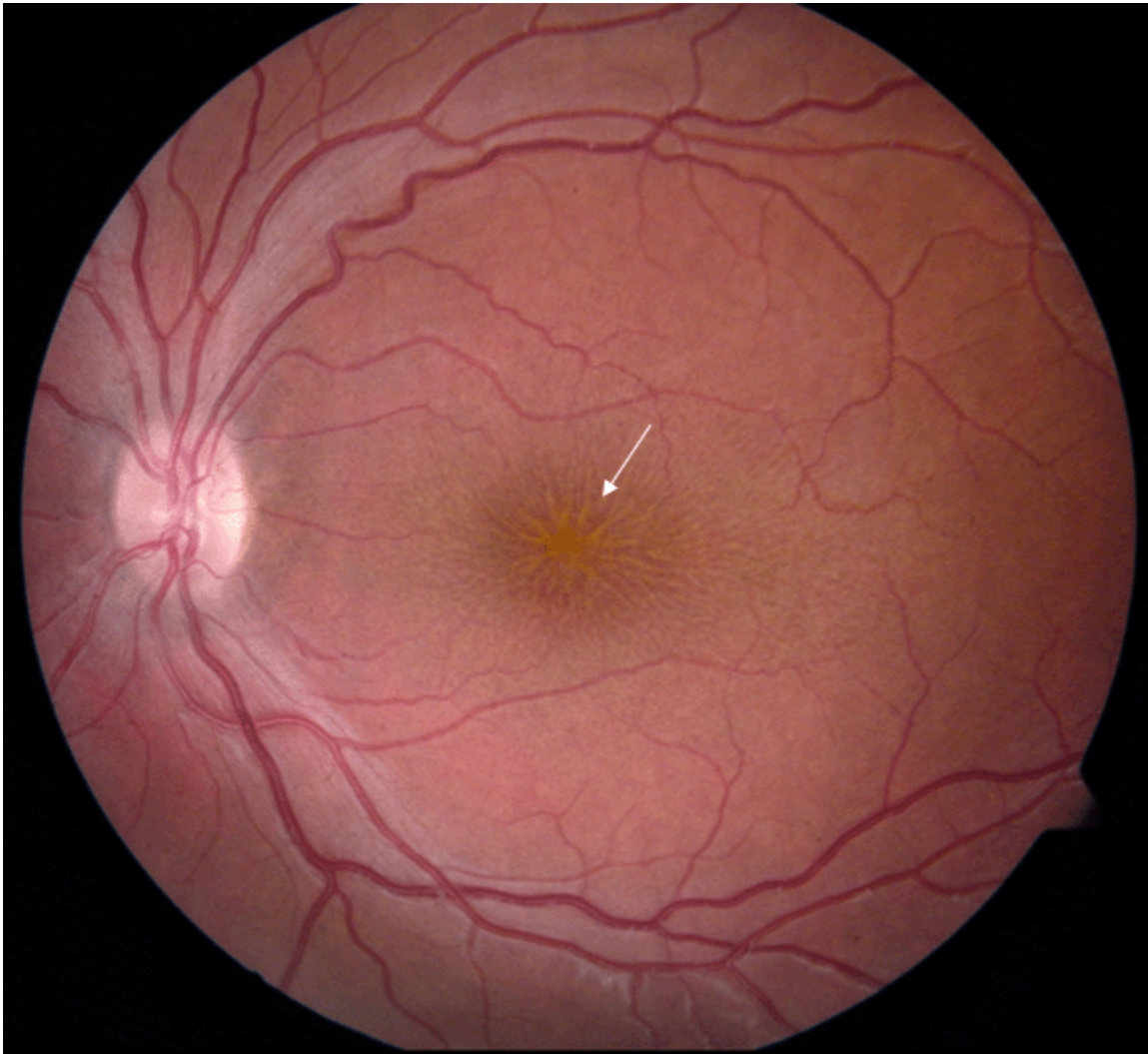


Figure 1. Fundus photo of a male with congenital retinoschisis. Arrow points to typical spoke-wheel pattern of foveal cysts.

For an introduction to multigene panels click [here](#). More detailed information for clinicians ordering genetic tests can be found [here](#).

Option 2

Comprehensive genomic testing does not require the clinician to determine which gene is likely involved. **Exome sequencing** is most commonly used; **genome sequencing** is also possible.

For an introduction to comprehensive genomic testing click [here](#). More detailed information for clinicians ordering genomic testing can be found [here](#).

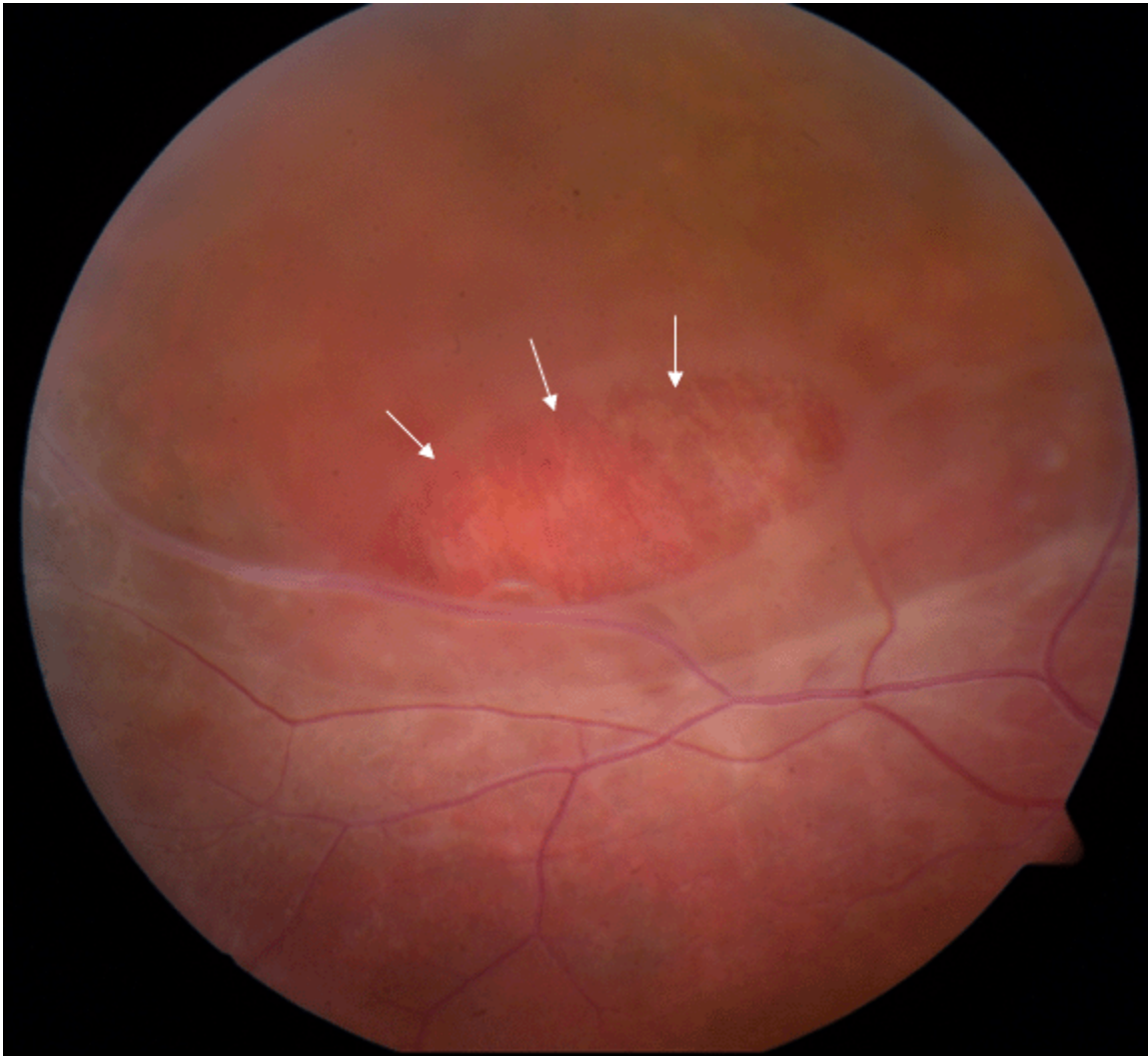


Figure 2. Fundus photo of the peripheral retina of a male with congenital retinoschisis. Area marked with arrows shows a partial-thickness retinal hole.

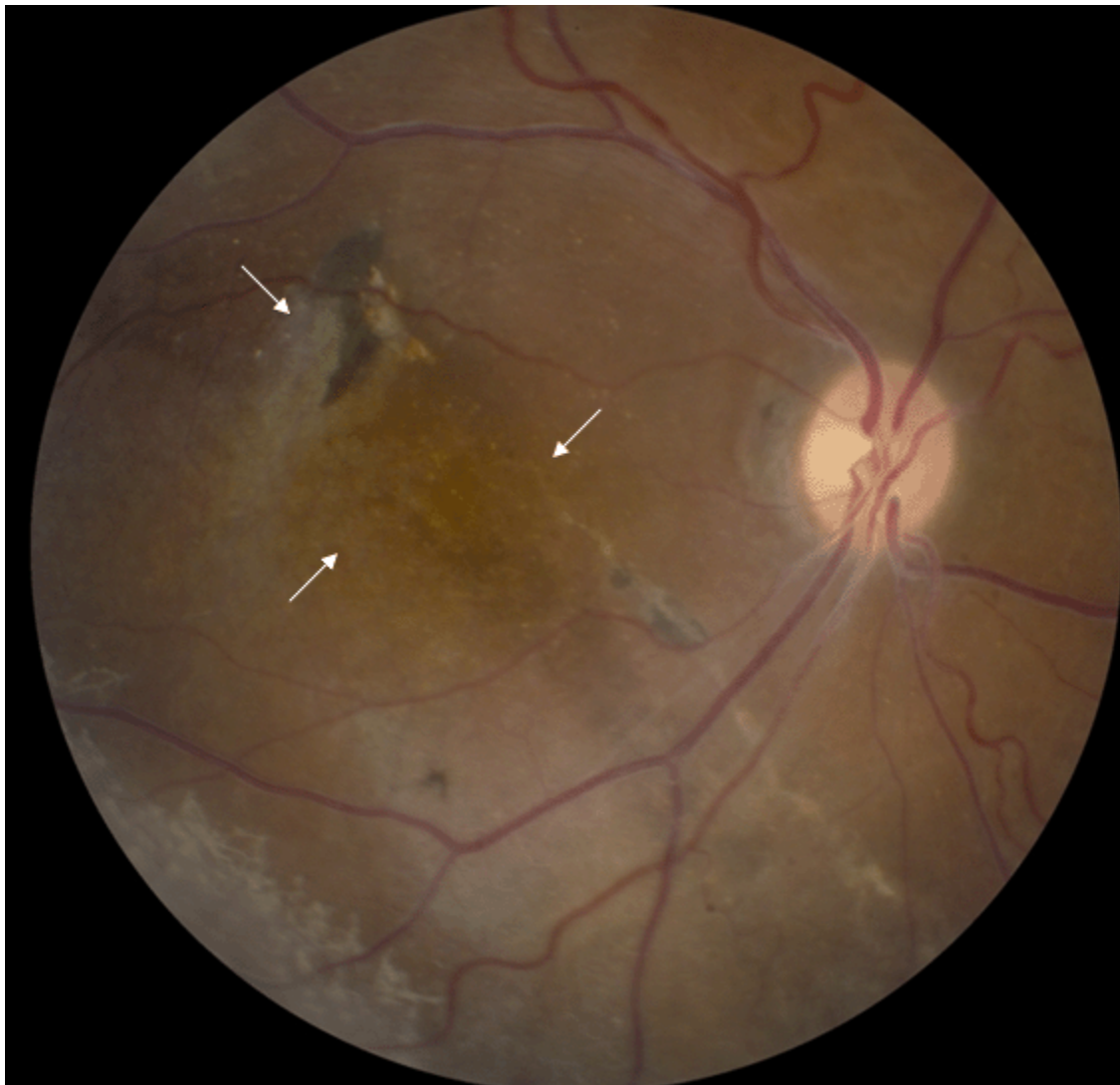

Figure 3. Fundus photo of a male with congenital retinoschisis showing atypical, more severe findings with arrows pointing to atrophic macular changes

Table 1. Molecular Genetic Testing Used in X-Linked Congenital Retinoschisis

Gene ¹	Method	Proportion of Pathogenic Variants ² Identified by Method
<i>RS1</i>	Sequence analysis ³	90%-95% ⁴
	Gene-targeted deletion/duplication analysis ⁵	5%-10% ⁴

1. See Table A. Genes and Databases for chromosome locus and protein.

2. See Molecular Genetics for information on variants detected in this gene.

3. Sequence analysis detects variants that are benign, likely benign, of uncertain significance, likely pathogenic, or pathogenic. Variants may include missense, nonsense, and splice site variants and small intragenic deletions/insertions; typically, exon or whole-gene deletions/duplications are not detected. For issues to consider in interpretation of sequence analysis results, click [here](#).

4. Retinoschisis Consortium [1998], Orès et al [2018], Kondo et al [2019]

5. Gene-targeted deletion/duplication analysis detects intragenic deletions or duplications. Methods used may include a range of techniques such as quantitative PCR, long-range PCR, multiplex ligation-dependent probe amplification (MLPA), and a gene-targeted microarray designed to detect single-exon deletions or duplications.

Clinical Characteristics

Clinical Description

X-linked congenital retinoschisis (XLRS) is a symmetric bilateral macular disorder with onset in the first decade of life in males, and, in some instances, as early as age three months. Affected males generally present with reduction in vision by early elementary school. Affected males typically have vision of 20/60 to 20/120 on first presentation.

Visual acuity may deteriorate slightly during the first and second decades of life but then remains relatively stable until the fifth or sixth decade, when slowly progressive macular atrophy can occur [Eksandh et al 2000, Apushkin et al 2005]. Visual loss may later progress to legal blindness (acuity <20/200). Some men show macular pigmentary changes after age 50 years; some degree of atrophy of the retinal pigment epithelium is common.

Variations in disease severity and progression are observed even among members of the same family.

Appearance of foveal lesions varies from largely radial striations (3%), microcystic lesions (34%), honeycomb-like cysts (8%), or their combinations (31%) to non-cystic-appearing foveal changes including pigment mottling (8%), loss of the foveal reflex (8%), or an atrophic-appearing lesion (8%) [Apushkin et al 2005].

XLRS progresses to retinal detachment in an estimated 5% to 22% of affected individuals. Retinal detachment can occur in infants with severe retinoschisis. About 4% to 40% of individuals with XLRS develop vitreous hemorrhage.

Heterozygous (carrier) females. In most instances, heterozygous females cannot be identified by clinical examination as they nearly always have a normal fundus appearance and visual function. Very rarely, examination of the peripheral retina may show white flecks or areas of schisis.

Genotype-Phenotype Correlations

The phenotype comprises a spectrum ranging from a few schisis cavities at the mild end to major retinoschisis detachment (not surgically repairable) at the severe end. The following general genotype-phenotype correlations have been reported:

- Pathogenic variants that are predicted to result in loss of protein function are typically associated with greater clinical severity [Sergeev et al 2010, Bowles et al 2011].
- Missense pathogenic variants are more commonly associated in milder clinical features, possibly due to residual protein function [Kim & Mukai 2013, Sergeev et al 2013].

Molecular modeling indicates that predicted change and/or damage to retinoschisin determines progression rate and clinical severity as evaluated by ERG. Importantly, molecular alterations that result in nonsense, splice site, and cysteine disulfide bond variants appear to be associated with the most severe functional deterioration [Sergeev et al 2010, Bowles et al 2011, Sergeev et al 2013].

Nomenclature

Other terms correctly used in the past to refer to X-linked congenital retinoschisis:

- X-linked juvenile retinoschisis
- Juvenile macular degeneration/dystrophy
- Degenerative retinoschisis
- Vitreous veils of the retina

Other terms incorrectly used in the past to refer to X-linked congenital retinoschisis:

- Cone dystrophy
- Macular hole

Prevalence

According to the Retinoschisis Consortium [1998] (which comprises the largest collection of known cases of XLRS) the estimated prevalence ranges from 1:5,000 to 1:25,000.

Genetically Related (Allelic) Disorders

No phenotypes other than those discussed in this *GeneReview* are known to be associated with germline pathogenic variants in *RS1*.

Differential Diagnosis

While the presence of retinoschisis in an individual with a positive family history of X-linked congenital retinoschisis (XLRS) establishes the diagnosis in that person, making the diagnosis in a male with no known family history may be more difficult.

Hereditary Disorders

Table 2. Genes of Interest in the Differential Diagnosis of X-Linked Congenital Retinoschisis

Gene	Disorder	MOI	Clinical Features of Differential Diagnosis Disorder	Distinguishing Features
<i>CACNA1F</i> <i>NYX</i>	X-linked congenital stationary night blindness	XL	Electronegative ERG may mimic XLRS.	XLRS rarely presents w/ complaint of "night blindness."
<i>NR2E3</i>	Goldmann-Favre vitreoretinal degeneration & enhanced S-cone syndrome (OMIM 268100)	AR	May mimic XLRS. Onset in infancy. Severely impaired vision incl marked visual field loss & severe night blindness. Coarse intraretinal cysts may be seen w/peripheral retinoschisis; no vitreous veils are observed.	ERG shows markedly ↓ a-waves & b-waves w/ altered timing (vs simply the ↓ in the b-wave amplitude seen in XLRS).
<i>OFD1</i> <i>RP2</i> <i>RPGR</i> (>80 genes) ¹	Nonsyndromic retinitis pigmentosa	XL ¹ (AD, AR, digenic)	RP: a group of inherited disorders involving congenital or progressive death of retinal photoreceptors (rods & cones) → visual loss. ² Referring diagnosis in many persons w/XLRS (XLRP may cause confusion w/XLRS.)	Unlike XLRS, RP may be assoc w/intraretinal pigment dispersion or clumping, narrowing of retinal vessels, & optic nerve gliotic pallor. ERG in RP (esp XLRP) has markedly ↓ a-wave & b-wave (vs selective b-wave amplitude ↓ in XLRS)

Table 2. continued from previous page.

Gene	Disorder	MOI	Clinical Features of Differential Diagnosis Disorder	Distinguishing Features
VCAN	VCAN vitreoretinopathy (Wagner syndrome & erosive vitreoretinopathy) (OMIM 143200)	AD	"Optically empty vitreous" on slit-lamp exam & avascular vitreous strands & veils, mild or occasionally moderate-to-severe myopia, presenile cataract, night blindness of variable degree assoc w/ progressive chorioretinal atrophy, retinal traction & retinal detachment at advanced stages of disease, & ↓ visual acuity. 1st signs usually appear in early adolescence.	

AD = autosomal dominant; AR = autosomal recessive; ERG = electroretinogram; MOI = mode of inheritance; XL = X-linked; XLRP = X-linked retinitis pigmentosa; XLRS = X-linked congenital retinoschisis

1. More than 80 genes are known to be associated with RP (see [Nonsyndromic Retinitis Pigmentosa Overview](#)). *OFD1*, *RP2*, and *RPGR* are associated with X-linked RP; 5% to 15% of all RP probands have X-linked RP.

2. Noble et al [1978] reported a family with rod-cone dystrophy and associated foveal schisis. For this reason, foveal retinoschisis alone does not make the diagnosis of XLRS.

Acquired Disorders and Hereditary Disorders of Unknown Genetic Cause

Cystoid macular edema may mimic foveal retinoschisis. Macular edema may be caused by diabetes mellitus, inflammatory conditions of the eye (uveitis), or intraocular surgery.

Bilateral amblyopia can be a referring diagnosis when foveal schisis changes are subtle and difficult to observe. Suspicion of XLRS is raised if family history indicates other affected males in an X-linked inheritance pattern.

Degenerative retinoschisis is an idiopathic, degenerative disease of the peripheral retina. No evidence suggests genetic etiology [Lewis 2003]. Degenerative peripheral retinoschisis is primarily age related, with splitting in the outer retina through the outer nuclear layer and plexiform layer; in XLRS splitting may also involve the proximal retinal layers [Sieving 1998].

Retinal detachment, in which the full-thickness retina elevates and lifts off from the underlying ocular support, differs from retinoschisis, in which the retina splits through the nerve fiber layer. Retinal detachment in an otherwise normal eye can be surgically repaired, whereas retinal detachment associated with retinoschisis usually cannot.

Management

Evaluations Following Initial Diagnosis

To establish the extent of disease and needs in an individual diagnosed with X-linked congenital retinoschisis (XLRS), the following evaluations (if not performed as part of the evaluation that led to the diagnosis) are recommended:

- Complete ophthalmologic examination including:
 - Best corrected visual acuity
 - Refractive error
 - Possible amblyopia
- Visual fields, by Goldmann or other perimetry

- Fundoscopic examination
- Optical coherence tomography
- Electroretinogram; confirmatory for half or more of cases by an electronegative configuration or b-wave amplitude reduction disproportionate to a-wave loss
- Consultation with a medical geneticist, certified genetic counselor, or certified advanced genetic nurse for the purpose of informing affected individuals and their families about the nature, mode of inheritance, and implications of XLRS in order to facilitate medical and personal decision making

Note: Turriff et al [2020] interviewed and surveyed parents of sons following a confirmed diagnosis of XLRS and describe ways in which medical professionals can optimally support affected individuals and their families.

Treatment of Manifestations

Refractive errors and amblyopia. Management is per standard care.

Note that amblyopia prevention therapy is indicated following surgical intervention to treat vitreous hemorrhage or retinal detachment, or in cases of severe retinoschisis or hypermetropia [Kyung & Lee 2012].

Surgical intervention. Because retinoschisis affects primarily the inner retinal layers, retinoschisis alone (without retinal detachment) is at best difficult to treat surgically.

Care of a retinal surgeon may be required to address the infrequent complications of vitreous hemorrhage and full-thickness retinal detachment. Because the clinical presentation of a large area of peripheral retinoschisis may mask a true retinal detachment, consultation with an ophthalmologist or retinal surgeon is recommended when in doubt.

Low-vision services are designed to benefit those whose ability to function is compromised by vision impairment. Low-vision specialists, often optometrists, help optimize the use of remaining vision. Services provided vary based on age and needs.

Public school systems are mandated by federal law to provide appropriate education for children who have vision impairment.

- Individualized education plan (IEP) services:
 - An IEP provides specially designed instruction and related services to children who qualify.
 - IEP services will be reviewed annually to determine whether any changes are needed.
 - Special education law requires that children participating in an IEP be in the least restrictive environment feasible at school and included in general education as much as possible, when and where appropriate.
 - Vision consultants should be a part of the child's IEP team to support access to academic material.
- A 504 plan (Section 504: a US federal statute that prohibits discrimination based on disability) can be considered for those who require accommodations or modifications such as front-of-class seating, assistive technology devices, classroom scribes, extra time between classes, modified assignments, and enlarged text.

Other. Many individuals with XLRS are able to obtain a restricted driver's license. Some individuals have found specially designed telescopic lenses useful when driving; legal use of telescopic lenses may vary by locale.

Surveillance

Annual evaluation of children younger than age ten years by a pediatric ophthalmologist to diagnose refractive errors or by a retina specialist to examine the peripheral retina for schisis or detachment is recommended.

Older children and adults need less frequent monitoring as they would be more apt to report changes in vision.

Patient education and close follow up are the only clinical options that may allow for early identification and treatment of vision-threatening complications such as retinal detachment ([Orphanet](#), accessed 11-2-20).

Agents/Circumstances to Avoid

Although retinal detachment and vitreous hemorrhage occur in a minority of affected individuals (5%-22% and 4%-40%, respectively), generally avoiding head trauma and high-contact sports is recommended.

Evaluation of Relatives at Risk

It is appropriate to clarify the genetic status of apparently asymptomatic older and younger at-risk male relatives of an affected individual in order to identify as early as possible those who would benefit from institution of treatment for retinal detachment and preventive measures (see Agents/Circumstances to Avoid).

- If the *RS1* pathogenic variant in the family is known, molecular genetic testing can be used to clarify the genetic status of at-risk male relatives.
- If the pathogenic variant in the family is not known, examination by an ophthalmologist can clarify the affected status of at-risk relatives.

See Genetic Counseling for issues related to testing of at-risk male relatives for genetic counseling purposes.

Therapies Under Investigation

Successful ocular gene therapy has been demonstrated in mouse XLR5 models [Zeng et al 2004, Min et al 2005].

Two human XLR5 gene therapy trials were initiated in 2015 (National Eye Institute: [ClinicalTrials.gov NCT02317887](#); AGTC, Inc: [ClinicalTrials.gov NCT02416622](#)):

- The NEI trial found closure of schisis cavities in one individual at higher dosing, which also caused ocular inflammation [Cukras et al 2018]. As of September 2020, this trial is ongoing and open for recruitment.
- The AGTC trial was halted by inflammation and lack of positive clinical treatment signs.

Search [ClinicalTrials.gov](#) in the US and [EU Clinical Trials Register](#) in Europe for access to information on clinical studies for a wide range of diseases and conditions.

Note: See Turriff et al [2019] for discussion of how medical professionals can support informed decision making in individuals considering participation in a gene therapy trial.

Genetic Counseling

Genetic counseling is the process of providing individuals and families with information on the nature, mode(s) of inheritance, and implications of genetic disorders to help them make informed medical and personal decisions. The following section deals with genetic risk assessment and the use of family history and genetic testing to clarify genetic status for family members; it is not meant to address all personal, cultural, or ethical issues that may arise or to substitute for consultation with a genetics professional. —ED.

Mode of Inheritance

X-linked congenital retinoschisis (XLR5) is inherited in an X-linked manner.

Risk to Family Members

Parents of a male proband

- The father of an affected male will not have the disorder nor will he be hemizygous for the *RS1* pathogenic variant; therefore, he does not require further evaluation/testing.
- In a family with more than one affected individual, the mother of an affected male is an obligate heterozygote (carrier). Note: If a woman has more than one affected son and no other affected relatives, and if the *RS1* pathogenic variant cannot be detected in her leukocyte DNA, she most likely has germline mosaicism.

Heterozygous females do not exhibit any signs in the macula, and only rarely are peripheral retinal changes associated with the carrier state.

- If a male is the only affected family member (i.e., a simplex case), the mother may be a carrier or the affected male may have a *de novo* *RS1* pathogenic variant, in which case the mother is not a carrier. *De novo* pathogenic variants have been reported but are rare [Gehrig et al 1999, Kim et al 2009].

Sibs of a male proband. The risk to sibs depends on the genetic status of the mother:

- If the mother of the proband has an *RS1* pathogenic variant, the chance of transmitting it in each pregnancy is 50%:
 - Males who inherit the pathogenic variant will be affected. Intrafamilial variability in disease severity and progression is observed in XLR5 [Vijayasathya et al 2009, Stephenson et al 2018, Christodoulou et al 2019].
 - Females who inherit the pathogenic variant will be carriers. Carriers nearly always have normal ocular examination, visual function, and electrophysiology (i.e., ERG).
- If the proband represents a simplex case (i.e., a single occurrence in a family) and if the *RS1* pathogenic variant cannot be detected in the leukocyte DNA of the mother, the risk to sibs of inheriting an *RS1* pathogenic variant is greater than that of the general population because of the possibility of maternal germline mosaicism; the risk of maternal germline mosaicism in XLR5 is not known.

Offspring of a male proband. Affected males transmit the *RS1* pathogenic variant to:

- All of their daughters will be (heterozygous) carriers and nearly always have normal visual function and normal electrophysiology (i.e., ERG); and
- None of their sons.

Other family members. A male proband's maternal aunts are at risk of being carriers for the *RS1* pathogenic variant and the aunts' offspring, depending on their sex, are at risk of being carriers for the pathogenic variant or of being affected.

Note: Molecular genetic testing may be able to identify the family member in whom a *de novo* pathogenic variant arose, thus providing information that could help determine genetic risk status of the extended family.

Carrier Detection

Molecular genetic testing of at-risk female relatives to determine their genetic status is most informative if the *RS1* pathogenic variant has been identified in the proband.

Note: (1) Females who are carriers for this X-linked disorder nearly always have normal visual function and normal electrophysiology (i.e., ERG). (2) Identification of female heterozygotes requires either (a) prior identification of the *RS1* pathogenic variant in the family or, (b) if an affected male is not available for testing, molecular genetic testing first by sequence analysis, and if no pathogenic variant is identified, by gene-targeted deletion/duplication analysis.

Related Genetic Counseling Issues

See Evaluation of Relatives at Risk for information on evaluating at-risk relatives for the purpose of early diagnosis and treatment.

Family planning

- The optimal time for determination of genetic risk, clarification of carrier status, and discussion of the availability of prenatal/preimplantation genetic testing is before pregnancy.
- It is appropriate to offer genetic counseling (including discussion of potential risks to offspring and reproductive options) to young adults who are affected, are carriers, or are at risk of being carriers.

Prenatal Testing and Preimplantation Genetic Testing

Once the *RS1* pathogenic variant has been identified in an affected family member, prenatal and preimplantation genetic testing are possible.

Differences in perspective may exist among medical professionals and within families regarding the use of prenatal testing. While most centers would consider use of prenatal testing to be a personal decision, discussion of these issues may be helpful.

Resources

GeneReviews staff has selected the following disease-specific and/or umbrella support organizations and/or registries for the benefit of individuals with this disorder and their families. GeneReviews is not responsible for the information provided by other organizations. For information on selection criteria, click [here](#).

- **National Library of Medicine Genetics Home Reference**
[X-linked juvenile retinoschisis](#)
- **Foundation Fighting Blindness**
7168 Columbia Gateway Drive
Suite 100
Columbia MD 21046
Phone: 800-683-5555 (toll-free); 800-683-5551 (toll-free TDD); 410-423-0600
Email: info@fightblindness.org
www.fightingblindness.org
- **Retina International**
Ireland
Phone: 353 1 961 9259
Email: info@retina-International.org
www.retina-international.org
- **eyeGENE – National Ophthalmic Disease Genotyping Network Registry**
Phone: 301-435-3032
Email: eyeGENEinfo@nei.nih.gov

<https://eyegene.nih.gov/>

Molecular Genetics

Information in the Molecular Genetics and OMIM tables may differ from that elsewhere in the GeneReview: tables may contain more recent information. —ED.

Table A. X-Linked Congenital Retinoschisis: Genes and Databases

Gene	Chromosome Locus	Protein	Locus-Specific Databases	HGMD	ClinVar
<i>RS1</i>	Xp22.13	Retinoschisin	Leiden Open Variation Database (RS1)	RS1	RS1

Data are compiled from the following standard references: gene from [HGNC](#); chromosome locus from [OMIM](#); protein from [UniProt](#). For a description of databases (Locus Specific, HGMD, ClinVar) to which links are provided, click [here](#).

Table B. OMIM Entries for X-Linked Congenital Retinoschisis ([View All in OMIM](#))

300839	RETINOSCHISIN; RS1
312700	RETINOSCHISIS 1, X-LINKED, JUVENILE; RS1

Molecular Pathogenesis

RS1 encodes retinoschisin, a protein highly expressed within the inner segments of the photoreceptors that has a complex interaction within cells of the retina [Molday et al 2001]. Retinoschisin is a scaffold protein necessary for retinal architecture and organization, as well as maintenance of the photoreceptor-bipolar synapse. Further refinement in the understanding of protein function and interaction continues to be elucidated [Bush et al 2015, Strupaitė et al 2018, Plössl et al 2019, Ziccardi et al 2019].

Mechanism of disease causation. Loss of function

Table 3. Notable *RS1* Pathogenic Variants

Reference Sequences	DNA Nucleotide Change	Predicted Protein Change	Comment [Reference]
NM_000330.3 NP_000321.1	c.214G>A	p.Glu72Lys	Founder variants in the Finnish population [Huopaniemi et al 1999]
	c.221G>T	p.Gly74Val	
	c.325G>C	p.Gly109Arg	

Variants listed in the table have been provided by the authors. *GeneReviews* staff have not independently verified the classification of variants.

GeneReviews follows the standard naming conventions of the Human Genome Variation Society (varnomen.hgvs.org). See [Quick Reference](#) for an explanation of nomenclature.

Chapter Notes

Author History

Stephanie Hoang, MSc (2014-present)

Ian M MacDonald, MD, CM (2003-present)

Paul A Sieving, MD, PhD (2003-present)

Meira Rina Meltzer, MA, MS; National Institutes of Health (2003-2014)

Nizar Smaoui, MD, FACMG; GeneDx (2003-2014)

Revision History

- 5 November 2020 (bp) Comprehensive update posted live
- 28 August 2014 (me) Comprehensive update posted live
- 12 May 2009 (me) Comprehensive update posted live
- 18 January 2006 (me) Comprehensive update posted live
- 24 October 2003 (me) Review posted live
- 1 July 2003 (ps) Original submission

References

Published Guidelines / Consensus Statements

AAO Task Force on Genetic Testing. American Academy of Ophthalmology Recommendations for Genetic Testing of Inherited Eye Diseases - 2014. Available [online](#). 2014. Accessed 1-25-22.

Literature Cited

- Apushkin MA, Fishman GA, Rajagopalan AS (2005) Fundus findings and longitudinal study of visual acuity loss in patients with X-linked retinoschisis. *Retina* 25:612-8 PubMed PMID: 16077359.
- Bowles K, Cukras C, Turriff A, Sergeev Y, Vitale S, Bush RA, Sieving PA. X-linked retinoschisis: RS1 mutation severity and age affect the ERG phenotype in a cohort of 68 affected male subjects. *Invest Ophthalmol Vis Sci.* 2011;52:9250-6. PubMed PMID: 22039241.
- Bush RA, Wei LL, Sieving PA. Convergence of human genetics and animal studies: gene therapy for X-linked retinoschisis. *Cold Spring Harb Perspect Med.* 2015;5:a017368. PubMed PMID: 26101206.
- Christodoulou P, Tanteles G, Nikolaou N, Katsimbris I, Stefaniotou M. Intrafamilial phenotype variability in two male siblings, with X-linked juvenile retinoschisis and dorzolamide treatment effect in the natural history of the disease. *Med Hypothesis Discov Innov Ophthalmol.* 2019;8:11-5. PubMed PMID: 30923717.
- Cukras CA, Wiley HE, Jeffrey BG, Sen HN, Turriff A, Zeng Y, Vijayasarathy C, Marangoni D, Ziccardi L, Kjellstrom S, Park TK, Hiriyantha S, Wright JF, Colosi P, Wu X, Bush RA, Wei LL, Sieving PA. Retinal AAV8-RS1 gene therapy for X-linked retinoschisis: initial findings from a Phase I/IIa trial by intravitreal delivery. *Mol Ther.* 2018;26:2282-94 PubMed PMID: 30196853.
- Eksandh L, Andréasson S, Abrahamson M. Juvenile X-linked retinoschisis with normal scotopic b-wave in the electroretinogram at an early stage of the disease. *Ophthalmic Genet.* 2005;26:111-7. PubMed PMID: 16272055.
- Eksandh LC, Ponjavic V, Ayyagari R, Bingham EL, Hiriyantha KT, Andreasson S, Ehinger B, Sieving PA (2000) Phenotypic expression of juvenile X-linked retinoschisis in Swedish families with different mutations in the XLR1 gene. *Arch Ophthalmol* 118:1098-104 PubMed PMID: 10922205.
- Gehrig A, Weber BH, Lorenz B, Andrassi M (1999) First molecular evidence for a de novo mutation in RS1 (XLR1) associated with X linked juvenile retinoschisis. *J Med Genet* 36:932-4 PubMed PMID: 10636740.
- Huopaniemi L, Rantala A, Forsius H, Somer M, de la Chapelle A, Alitalo T (1999) Three widespread founder mutations contribute to high incidence of X-linked juvenile retinoschisis in Finland. *Eur J Hum Genet* 7:368-76 PubMed PMID: 10234514.
- Kim DY, Mukai S. X-linked juvenile retinoschisis (XLR1): a review of genotype-phenotype relationships. *Semin Ophthalmol.* 2013;28:392-6. PubMed PMID: 24138048.

- Kim SY, Ko HS, Yu YS, Hwang JM, Lee JJ, Kim SY, Kim JY, Seong MW, Park KH, Park SS. Molecular genetic characteristics of X-linked retinoschisis in Koreans. *Mol Vis*. 2009;15:833-43 PubMed PMID: 19390641.
- Kondo H, Oku K, Katagiri S, Hayashi T, Nakano T, Iwata A, Kuniyoshi K, Kusaka S, Hiyoshi A, Uchio E, Kondo M, Oishi N, Kameya S, Mizota A, Naoi N, Ueno S, Terasaki H, Morimoto T, Iwaki M, Yoshitake K, Iejima D, Fujinami K, Tsunoda K, Shinoda K, Iwata T. Novel mutations in the RS1 gene in Japanese patients with X-linked congenital retinoschisis. *Hum Genome Var*. 2019;6:3. PubMed PMID: 30652005.
- Kyung SE, Lee M. Foveal retinoschisis misdiagnosed as bilateral amblyopia. *Int Ophthalmol*. 2012;32:595-8. PubMed PMID: 22752678.
- Lewis H. Peripheral retinal degenerations and the risk of retinal detachment. *Am J Ophthalmol*. 2003;136:155-60. PubMed PMID: 12834683.
- Min SH, Molday LL, Seeliger MW, Dinculescu A, Timmers AM, Janssen A, Tonagel F, Tanimoto N, Weber BH, Molday RS, Hauswirth WW (2005) Prolonged recovery of retinal structure/function after gene therapy in an Rs1h-deficient mouse model of x-linked juvenile retinoschisis. *Mol Ther* 12:644-51 PubMed PMID: 16027044.
- Molday LL, Hicks D, Sauer CG, Weber BH, Molday RS (2001) Expression of X-linked retinoschisis protein RS1 in photoreceptor and bipolar cells. *Invest Ophthalmol Vis Sci* 42:816-25 PubMed PMID: 11222545.
- Molday RS, Kellner U, Weber BH. X-linked juvenile retinoschisis: clinical diagnosis, genetic analysis, and molecular mechanisms. *Prog Retin Eye Res*. 2012;31:195-212. PubMed PMID: 22245536.
- Nakamura M, Ito S, Terasaki H, Miyake Y (2001) Japanese X-linked juvenile retinoschisis: conflict of phenotype and genotype with novel mutations in the XLRs1 gene. *Arch Ophthalmol* 119:1553-4 PubMed PMID: 11594966.
- Noble KG, Carr RE, Siegel IM (1978) Familial foveal retinoschisis associated with a rod-cone dystrophy. *Am J Ophthalmol* 85:551-7 PubMed PMID: 306756.
- Orès R, Mohand-Said S, Dhaenens CM, Antonio A, Zeitz C, Augstburger E, Andrieu C, Sahel JA, Audo I. Phenotypic characteristics of a French cohort of patients with X-linked retinoschisis. *Ophthalmology*. 2018;125:1587-96. PubMed PMID: 29739629.
- Plössl K, Straub K, Schmid V, Strunz F, Wild J, Merkl R, Weber BHF, Friedrich U. Identification of the retinoschisin-binding site on the retinal Na/K-ATPase. *PLoS One*. 2019 May 2;14(5):e0216320. PubMed PMID: 31048931.
- Renner AB, Kellner U, Fiebig B, Cropp E, Foerster MH, Weber BH. ERG variability in X-linked congenital retinoschisis patients with mutations in the RS1 gene and the diagnostic importance of fundus autofluorescence and OCT. *Doc Ophthalmol*. 2008;116:97-109. PubMed PMID: 17987333.
- Retinoschisis Consortium. Functional implications of the spectrum of mutations found in 234 cases with X-linked juvenile retinoschisis. *Hum Mol Genet* 1998;7:1185-92 PubMed PMID: 9618178.
- Richards S, Aziz N, Bale S, Bick D, Das S, Gastier-Foster J, Grody WW, Hegde M, Lyon E, Spector E, Voelkerding K, Rehm HL; ACMG Laboratory Quality Assurance Committee. Standards and guidelines for the interpretation of sequence variants: a joint consensus recommendation of the American College of Medical Genetics and Genomics and the Association for Molecular Pathology. *Genet Med*. 2015;17:405-24. PubMed PMID: 25741868.
- Sergeev YV, Caruso RC, Meltzer MR, Smaoui N, MacDonald IM, Sieving PA. Molecular modeling of retinoschisin with functional analysis of pathogenic mutations from human X-linked retinoschisis. *Hum Mol Genet*. 2010;19:1302-13. PubMed PMID: 20061330.
- Sergeev YV, Vitale S, Sieving PA, Vincent A, Robson AG, Moore AT, Webster AR, Holder GE. Molecular modeling indicates distinct classes of missense variants with mild and severe XLRs phenotypes. *Human Molecular Genetics* 2013;22:4756-67. PubMed PMID: 23847049.

- Sieving PA, Bingham EL, Kemp J, Richards J, Hiriyanna K (1999) Juvenile X-linked retinoschisis from XLRs1 Arg213Trp mutation with preservation of the electroretinogram scotopic b-wave. *Am J Ophthalmol* 128:179-84 PubMed PMID: 10458173.
- Sieving PA. Juvenile retinoschisis. In: Traboulsi EI, ed. *Genetic Diseases of the Eye*. New York, NY: Oxford University Press; 1998:347-55.
- Stephenson K, Dockery A, Wynne N, Carrigan M, Kenna P, Jane Farrar G, Keegan D. Multimodal imaging in a pedigree of X-linked Retinoschisis with a novel RS1 variant. *BMC Med Genet*. 2018;19:195. PubMed PMID: 30419843.
- Strupaitė R, Ambrozaitytė L, Cimbalistienė L, Ašoklis R, Utkus A. X-linked juvenile retinoschisis: phenotypic and genetic characterization. *Int J Ophthalmol*. 2018;11:1875-8. PubMed PMID: 30450322.
- Turriff A, Blain D, Similuk M, Biesecker B, Wiley H, Cukras C, Sieving PA. Motivations and decision making processes of men with X-linked retinoschisis considering participation in an ocular gene therapy trial. *Am J Ophthalmol*. 2019;204:90-6. PubMed PMID: 30885710.
- Turriff A, Nolen R, D'Amanda C, Biesecker B, Cukras C, Sieving PA. "There are hills and valleys": experiences of parenting a son with X-linked retinoschisis. *Am J Ophthalmol*. 2020 Apr;212:98-104. PubMed PMID: 31765628.
- Vijayasarathy C, Ziccardi L, Zeng Y, Smaoui N, Caruso RC, Sieving PA. Null retinoschisin-protein expression from an RS1 c354del1-ins18 mutation causes progressive and severe XLRs in a cross-sectional family study. *Invest Ophthalmol Vis Sci*. 2009;50:5375-83. PubMed PMID: 19474399.
- Zeng Y, Takada Y, Kjellstrom S, Hiriyanna K, Tanikawa A, Wawrousek E, Smaoui N, Caruso R, Bush RA, Sieving PA (2004) RS-1 gene delivery to an adult Rs1h knockout mouse model restores ERG b-wave with reversal of the electronegative waveform of X-linked retinoschisis. *Invest Ophthalmol Vis Sci* 45:3279-85 PubMed PMID: 15326152.
- Ziccardi L, Cordeddu V, Gaddini L, Matteucci A, Parravano M, Malchiodi-Albedi F, Varano M. Gene therapy in retinal dystrophies. *Int J Mol Sci*. 2019;20:5722. PubMed PMID: 31739639.

License

GeneReviews® chapters are owned by the University of Washington. Permission is hereby granted to reproduce, distribute, and translate copies of content materials for noncommercial research purposes only, provided that (i) credit for source (<http://www.genereviews.org/>) and copyright (© 1993-2024 University of Washington) are included with each copy; (ii) a link to the original material is provided whenever the material is published elsewhere on the Web; and (iii) reproducers, distributors, and/or translators comply with the [GeneReviews® Copyright Notice and Usage Disclaimer](#). No further modifications are allowed. For clarity, excerpts of GeneReviews chapters for use in lab reports and clinic notes are a permitted use.

For more information, see the [GeneReviews® Copyright Notice and Usage Disclaimer](#).

For questions regarding permissions or whether a specified use is allowed, contact: admasst@uw.edu.